

VIDEO SESSION

## Implantable Loop Recorder and Syncope-Rhythm Correlation

Christos Maniotis, MD, Athanasios G. Manolis, MD,  
Panagiotis Dimitriou, MD, Kostas Kouvelas, MD, Zenon S. Kyriakides, MD

---

ABSTRACT

---

A case of syncope-rhythm correlation is presented in a patient with a history of unexplained loss of consciousness and an implantable loop recorder. A permanent pacemaker was implanted due to the bradycardia event revealed by the recorder device and the patient remained asymptomatic in the follow up period.

2<sup>nd</sup> Cardiology Department, Hellenic  
Red Cross Hospital of Athens, Athens,  
Greece

**KEY WORDS:** *syncope; implantable  
loop recorder; pacemaker*

**ABBREVIATIONS**

ECG = electrocardiogram

ESC = European Society of Cardiology

ILR = implantable loop recorder

*Corresponding author:*

Christos Maniotis, MD, 2<sup>nd</sup> Cardiology  
Department, Hellenic Red Cross  
Hospital of Athens, Athens, Greece;  
E-mail: chrnm21@gmail.com

---

INTRODUCTION

---

Syncope is defined as a transient loss of consciousness characterized by rapid onset, short duration and spontaneous complete recovery.<sup>1</sup> The etiology of recurrent syncope is often difficult to determine if the diagnosis is not evident from the initial clinical and laboratory investigations. The major obstacles concerning the diagnosis of the etiology of syncope are the periodic and unpredictable frequency of events. An evidence based approach in this patient's population is the prolonged rhythm monitoring with a subcutaneously implanted loop recorder (ILR). A patient with recurrent and unexplained syncope in whom the arrhythmic cause was documented using an ILR is herein presented.

---

CASE REPORT

---

A 59-year-old man was referred to our hospital for an episode of loss of consciousness. His past medical history was significant for three similar episodes that he had experienced in the upright position over the preceding one year. No family history of sudden death was reported. The clinical examination was negative. Sinus rhythm with a narrow QRS complex was recorded in the surface electrocardiogram. Echocardiogram was normal and therefore apparent structural heart disease could not be documented. The 24-hour external ambulatory recording (Holter ECG) revealed no arrhythmias and conduction disturbances. The head-up tilt testing (passive and under isoproterenol administration) was negative. An electrophysiology study was performed during which no conduction abnormality could be detected and no ventricular tachyarrhythmias could be induced by programmed electrical stimulation. Subsequently, an implantable loop recorder (ILR) device (St Jude Medical) was employed in order to further elucidate

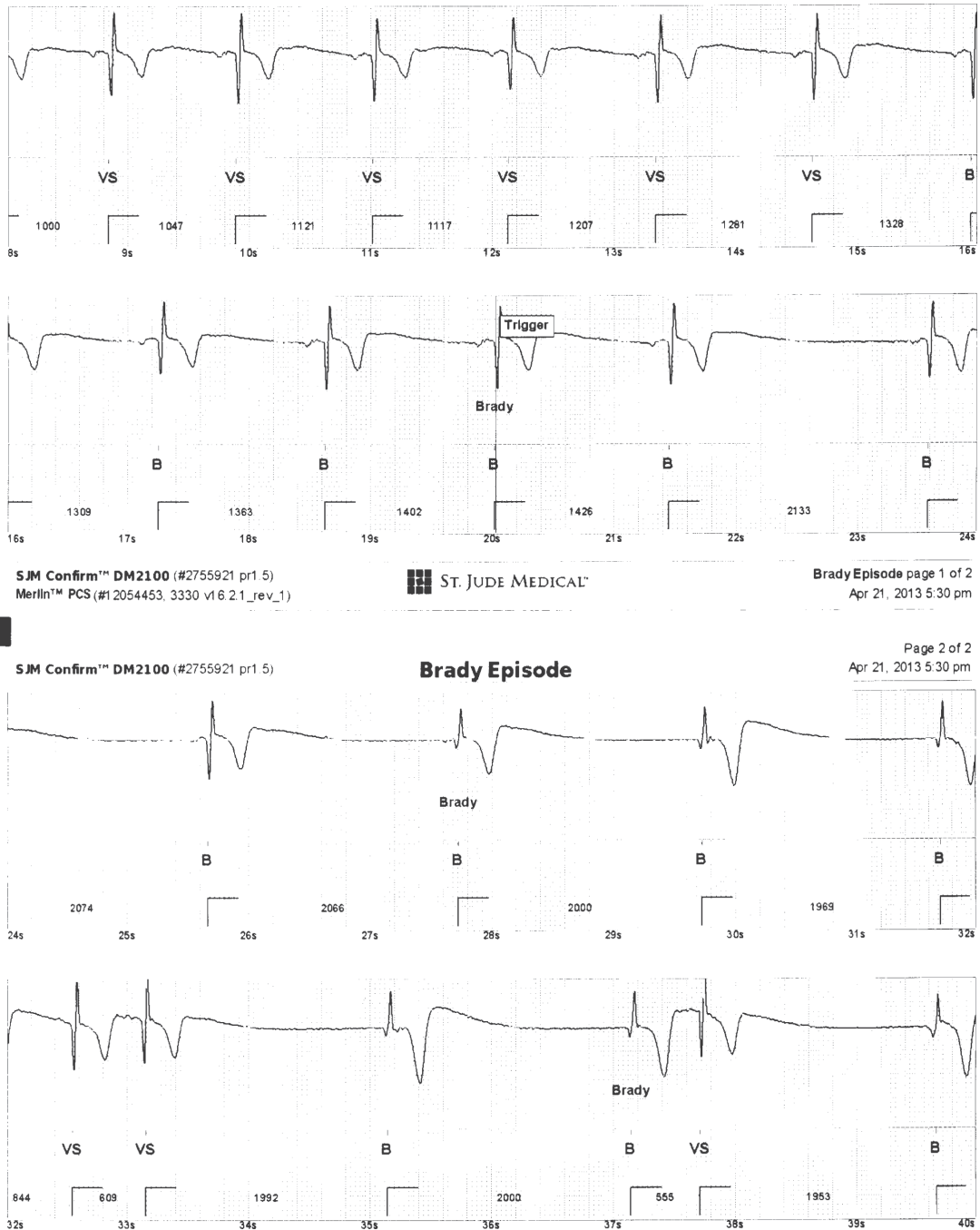---

**Conflict of Interest:** none declared

the cause of the syncopal episodes.

Six months later, the patient was referred to our emergency clinic because of syncope followed by head trauma. The interrogation of the ILR revealed an episode of low escape junctional rhythm (narrow QRS complex) at a rate of 29 bpm.

Careful tracing analysis demonstrated a gradual decrease of the heart rate with sinus pause followed by a slow junctional rhythm (Figure 1). This rhythm pattern was probably related to a neutrally-mediated reflex mechanism as the possible cause of syncope.



**FIGURE 1.** ILR tracing during syncope demonstrated a gradually decrease of the heart rate with sinus pause followed by a slow junctional rhythm (29 bpm).

## IMPLANTABLE LOOP RECORDER

Based on this symptom- rhythm abnormality correlation, a dual chamber pacemaker was implanted. The ILR was not extracted at this time because the device had enough battery energy for future recording other arrhythmia abnormalities (Figure 2). During a 10-month follow-up period no symptoms were reported by the patient.

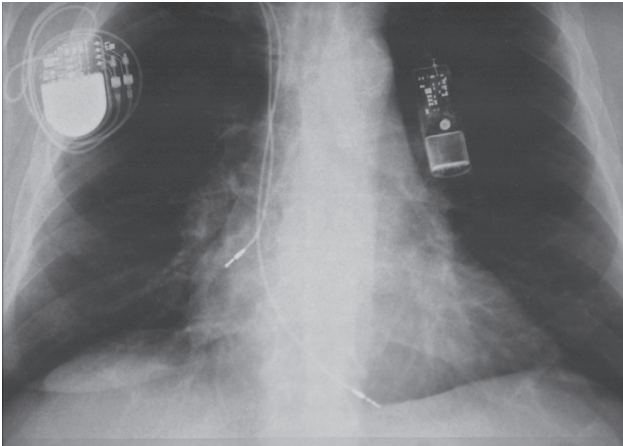


FIGURE 2. Chest X-ray with the implanted devices (dual chamber pacemaker and ILR).

---

### DISCUSSION

---

The cause of syncope of unknown origin can be elusive, even after rigorous noninvasive and invasive testing. It is not the symptomatology but the etiology of syncope that is related to its prognosis.<sup>2</sup> Establishing a symptom-rhythm correlation in patients with unexplained syncope is complicated because of its sporadic, infrequent and unpredictable nature. Conventional ambulatory monitoring is frequently undertaken in patients with syncope, but symptom correlation with relevant rhythm disorders occurs in less than 5%.<sup>3</sup>

We herein presented a case of a 59- year-old man with an ILR who was referred to our hospital for loss of conscious-

ness. The interrogation of the device revealed the cause of syncope. Based on the ILR findings, a permanent pacemaker implantation was performed.<sup>4</sup>

Over the recent years, ILR has been reported to be a useful tool for the evaluation of syncopal episodes, with a very satisfactory diagnostic rate compared to other conventional tests. The ILR has a diagnostic yield of approximately 60%, with considerable variation among studies.<sup>5</sup> It has been proven to be more cost effective and effectual than conventional diagnostic studies like external loop recorders, tilt-table test, and electrophysiology studies.<sup>6</sup> The usefulness of the ILR in this setting was reconfirmed by two large multicenter studies.<sup>4,7</sup> Finally and according to the current guidelines of the European Society of Cardiology (ESC),<sup>1</sup> a pacemaker implantation is recommended in the neurally mediated syncope population if cardiac bradycardia is documented by ILR monitoring.

### REFERENCES

1. Moya A, Sutton R, Ammirati F, et al. Guidelines for the diagnosis and management of syncope (version 2009). *Eur Heart J* 2009;30:2631-2671.
2. Soteriades ES, Evans JC, Larson MG, et al. Incidence and prognosis of syncope. *N Engl J Med* 2002;347:878-885.
3. Bass EB, Curtiss EI, Arena VC, et al. The duration of Holter monitoring in patients with syncope. Is 24 hours enough? *Arch Intern Med* 1990;150:1073-1078.
4. Brignole M, Sutton R, Menozzi C, et al. Early application of an implantable loop recorder allows effective specific therapy in patients with recurrent suspected neurally mediated syncope. *Eur Heart J* 2006;27:1085-1092.
5. Farwell DJ, Freemantle N, Sulke AN. Use of implantable loop recorders in the diagnosis and management of syncope. *Eur Heart J* 2004;25:1257-1263.
6. Krahn AD, Klein GJ, Yee R, Hoch JS, Skanes AC. Cost implications of testing strategy in patients with syncope: randomized assessment of syncope trial. *J Am Coll Cardiol* 2003;42:495-501.
7. Edvardsson N, Frykman V, van Mechelen R, et al. Use of an implantable loop recorder to increase the diagnostic yield in unexplained syncope: results from the PICTURE registry. *Europace* 2011;13:262-269.