

VIDEO SESSION

## Thrombosis of Left Coronary Artery During Primary Percutaneous Coronary Intervention

Panagiotis Margos, MD, Maria Vroulidaki, MD, Athanasios Kranidis, MD

### ABSTRACT

We present a case of a 51-year-old male with acute anterior myocardial infarction, who was transferred to our hospital under mechanical ventilation, after resuscitation due to cardiopulmonary arrest. The patient underwent urgent coronary angiography, which showed total thrombotic occlusion of the proximal segment of the left anterior descending (LAD) coronary artery disease. During primary percutaneous coronary intervention (PPCI), thrombosis extended into the left main coronary artery (LMCA), the LAD and the left circumflex artery (LCx) coronary arteries, causing severe hemodynamic compromise. This devastating complication was successfully managed with intracoronary administration of antithrombotic and antiplatelet drugs, as well as thrombus aspiration. We herein discuss the possible mechanisms of this complication and highlight its prevention and treatment.

*First Department of Cardiology,  
General Hospital of Nikea, Piraeus,  
Greece*

**KEY WORDS:** *myocardial infarction;  
resuscitation; coronary artery  
thrombosis; thrombus aspiration*

### INTRODUCTION

Primary percutaneous coronary intervention (PPCI) improves outcomes in patients with acute ST elevation myocardial infarction (STEMI) in comparison to thrombolysis.<sup>1</sup> PPCI can be easily performed in intubated patients with hemodynamic stability and should be preferred over thrombolysis, especially when cardiopulmonary resuscitation has been performed.<sup>2</sup> In this situation, thrombolysis may cause severe hemorrhage due to rib fracture or other injury caused by cardiac arrest and subsequent resuscitation. We describe a case of a middle-aged male with aborted sudden cardiac death due to acute anterior myocardial infarction, who manifested a secondary potentially lethal complication during PPCI.

### CASE PRESENTATION

A 51-year-old male, smoker, without medical history of cardiovascular disease, complained of progressive chest discomfort and dizziness. In a short period of time, cardiopulmonary arrest occurred. The patient underwent intubation, chest compressions and repetitive defibrillation therapies for ventricular fibrillation by paramedical personnel during his transfer to our hospital. In the emergency department, the electrocardiogram revealed acute anterior myocardial infarction. Blood pressure was 110/70

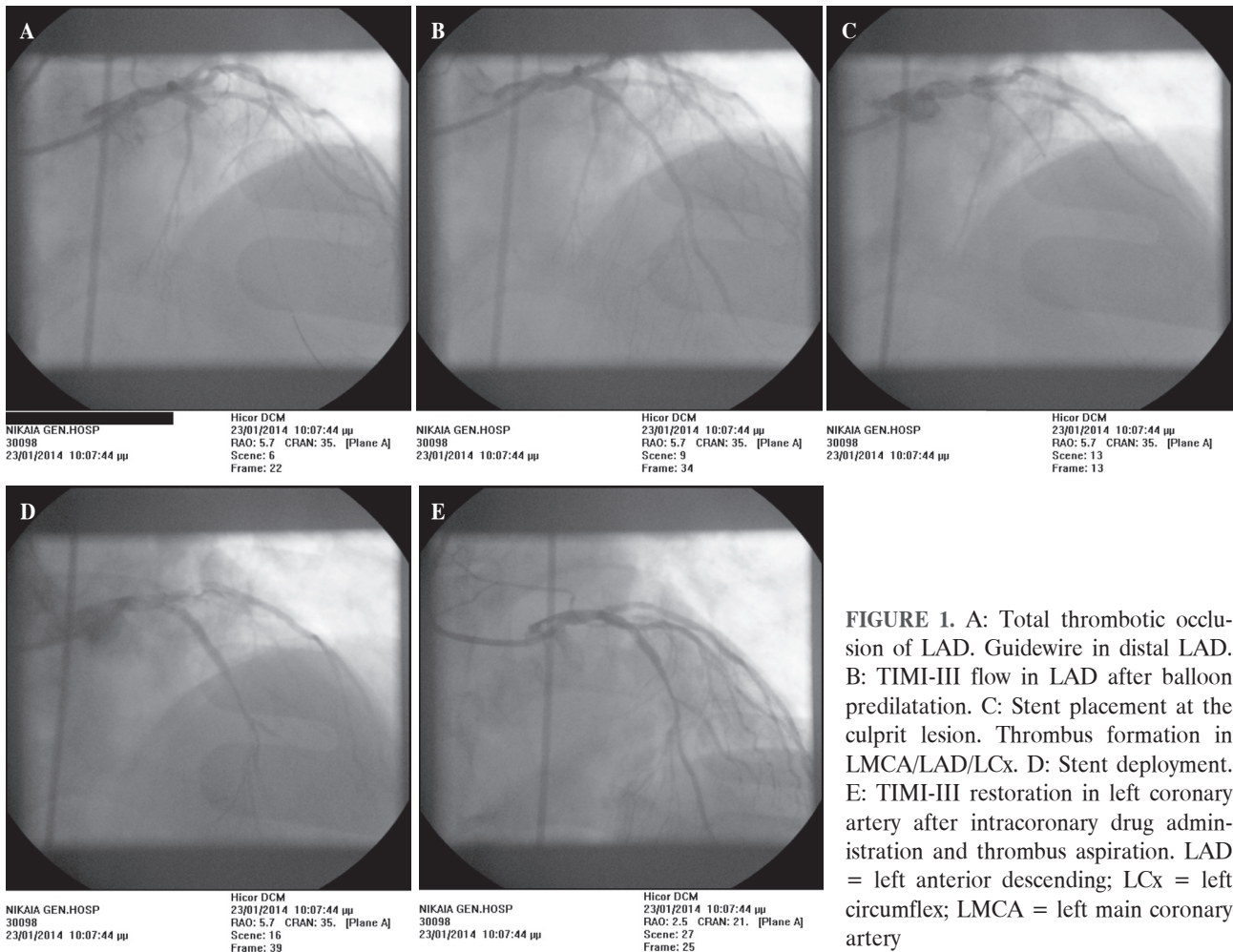
*Corresponding author:*  
Athanasios Kranidis, MD  
E-mail: athanasioskranidis@gmail.com

mmHg. Pupillary light reflex was normal. No signs of rib fracture or major trauma were present on physical examination.

The patient was directly transferred to the catheterization laboratory, after intravenous administration of heparin (5000 IU). Coronary angiography demonstrated a total thrombotic occlusion of the proximal segment of the left anterior descending (LAD) coronary artery and PPCI was performed. After predilatation of the total occlusion with a balloon (*Sprinter 2.5x15 mm, inflation at 12 Atm*), TIMI-III flow was restored within the LAD artery. A bare metal stent (BMS Integrity, 3.0 x 22 mm) was placed in the culprit lesion. Before stent deployment, thrombus formation was noted in the left main coronary artery (LMCA), proximal LAD and proximal left circumflex (LCx) coronary artery segments. Despite stent deployment (at 16 Atm), thrombus formation progressed with subsequent flow regression (TIMI-I) in the left coronary arteries and cardiogenic shock occurred (bradycardia, severe

hypotension). Intracoronary extra loading dose of 5000 IU of heparin as well as intracoronary loading dose of abciximab were administered directly, followed by thrombus aspiration from the LMCA and proximal LAD (*E-max catheter*). As a consequence, hemodynamic stability was restored and repeat angiography revealed restoration of TIMI-III flow. Residual thrombus in the proximal LAD segment was detected and was treated with balloon angioplasty (*balloon Sprinter 3.0x15 mm, inflation at 12 Atm*).

The final angiographic result was optimal (Figure 1, A-E). The patient remained hemodynamically stable and was extubated 5 days later, with no neurologic defects. Echocardiogram revealed depressed left ventricular systolic function (ejection fraction=35-40%) due to hypokinetic anteroseptal and akinetic apical wall. The patient was discharged home a few days later, with no arrhythmic events and no symptoms or signs of heart failure.



**FIGURE 1.** A: Total thrombotic occlusion of LAD. Guidewire in distal LAD. B: TIMI-III flow in LAD after balloon predilatation. C: Stent placement at the culprit lesion. Thrombus formation in LMCA/LAD/LCx. D: Stent deployment. E: TIMI-III restoration in left coronary artery after intracoronary drug administration and thrombus aspiration. LAD = left anterior descending; LCx = left circumflex; LMCA = left main coronary artery

---

**DISCUSSION**


---

Acute thrombosis is a rare but well-described complication of primary percutaneous coronary intervention (PPCI), especially in the form of acute stent thrombosis.<sup>3</sup> This complication is more often in patients with STEMI who undergo PPCI. During or right after PPCI, the activated endogenous thrombotic mechanism may predominate over antithrombotic power of antiplatelet and heparin loading doses. It is well known that 600 mg loading dose of clopidogrel achieves its full platelet-inhibitory effect within 2 hours.<sup>4</sup> Ticagrelor and prasugrel may shorten this latent period. Factors like vomiting or opioid administration may be responsible for reduced or delayed drug absorption after p.o. taking.<sup>5,6</sup> Thrombus embolization is another mechanism of occlusion of distal parts or branches of the recanalized artery. New thrombus formation proximal to the culprit lesion is quite rare and potentially lethal complication during PCI.<sup>7</sup>

In our patient, the extensive thrombus formation that transiently occluded the left coronary arteries can be partially explained by the absence of antiplatelet loading dose (intubated patient). Intravenous glycoprotein IIb-IIIa inhibitor was not administered before the occurrence of thrombus formation, due to the risk of traumatic bleeding (resuscitated patient). Nevertheless, the subsequent 72-hour administration of glycoprotein IIb-IIIa inhibitor, in combination with low-molecular weight heparin, did not cause any hemorrhagic complication.

In general, thrombolytic therapy could be preferred over extra loading dose of heparin and/or loading dose of abciximab in cases of acute intracoronary thrombosis, depending on the extent of thrombus formation and its hemodynamic consequences.<sup>8,9</sup> Balloon angioplasty in the thrombotic segment of the coronary artery may also be preferred over thrombus aspiration, in order to restore TIMI-III flow. The first-line drug or mechanical therapy depends mainly on the location and extent of thrombus formation.

In conclusion, in cases of increased risk of acute coronary thrombosis during PCI, intravenous administration of glycoprotein IIb-IIIa inhibitors should be considered. Whenever acute thrombosis occurs, aggressive drug therapy with intrave-

nous antithrombotic, antiplatelet or even thrombolytic agents and mechanical therapy (balloon angioplasty and/or thrombus aspiration) should be performed.

**REFERENCES**

1. Silber S. Evidence-based management of ST-segment elevation myocardial infarction (STEMI). Latest guidelines of the European Society of Cardiology (ESC) 2010. *Herz* 2010;35:558-564.
2. Siudak Z, Birkemeyer R, Dziewierz A, et al. Out-of-hospital cardiac arrest in patients treated with primary PCI for STEMI. Long-term follow up data from EUROTRANSFER registry. *Resuscitation* 2012;83:303-306.
3. Hong YJ, Jeong MH, Choi YH, et al. Clinical, angiographic, and intravascular ultrasound predictors of early stent thrombosis in patients with acute myocardial infarction. *Int J Cardiol* 2013;168:1674-1675.
4. Hochholzer W, Trenk D, Frundi D, et al. Time dependence of platelet inhibition after a 600-mg loading dose of clopidogrel in a large, unselected cohort of candidates for percutaneous coronary intervention. *Circulation* 2005;111:2560-2564.
5. Montalescot G, Wiviott SD, Braunwald E, et al; TRITON-TIMI 38 investigators. Prasugrel compared with clopidogrel in patients undergoing percutaneous coronary intervention for ST-elevation myocardial infarction (TRITON-TIMI 38): double-blind, randomised controlled trial *Lancet* 2009;373:723-731.
6. Steg PG, Harrington RA, Emanuelsson H, et al; PLATO Study Group. Stent thrombosis with ticagrelor versus clopidogrel in patients with acute coronary syndromes: an analysis from the prospective, randomized PLATO trial. *Circulation* 2013; 128:1055-1065.
7. Stone GW Advances in interventional cardiology. Angioplasty strategies in ST-segment-elevation myocardial infarction Part I: primary percutaneous coronary intervention. *Circulation* 2008;118:538-551.
8. Higashi H, Inaba S, Nishimura K, et al. Usefulness of adjunctive pulse infusion thrombolysis after failed aspiration for massive intracoronary thrombus. *Can J Cardiol* 2011;27:869.e1-2.
9. Balghith M, Al-Ghamdi A, Zain el H, et al. Intracoronary reopro during percutaneous coronary intervention in acute and stable patient can influence stent thrombosis formation (IR-PASST) study. *Heart Views* 2013;14:62-67.