

VIDEO SESSION

## Recurring Strokes Due to an Arterio-Venous Fistula in the Pulmonary Circulation

Anastasios Papadopoulos, MD, Ilias K. Karabinos, MD

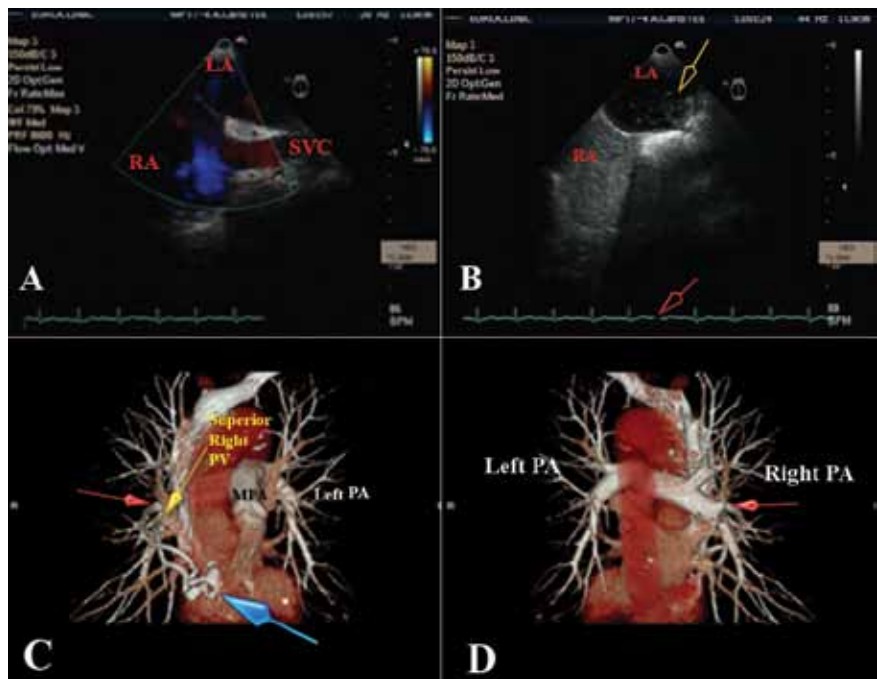
Department of Cardiology,  
Euroclinic Hospital, Athens, Greece

A 67-year-old female patient, with history of smoking and hypertension under treatment with aspirin 100 mg qd and nebivolol 5 mg qd, presented with deteriorating

KEY WORDS:

ABBREVIATIONS

CT = computed tomography  
MRI = magnetic resonance imaging  
TPA = tissue-plasminogen activator



**FIGURE 1.** **A.** Transesophageal echocardiography, bicaval view, colored Doppler: intact atrial septum, interatrial communication. **B.** Transesophageal echocardiography, bicaval view; infusion of 10 ml of agitated normal saline (bubble contrast study) revealed an early, after 5 cardiac cycles (red arrow), massive inflow of microbubbles (yellow arrow) to the left atrium. **C.** CT-angiography of pulmonary circulation, anterior view; a U shaped communication (blue arrow) between a branch of right superior pulmonary vein (yellow arrow) and a vessel originating from right pulmonary artery (red arrow) is depicted. **D.** CT-angiography of pulmonary circulation, posterior view; the origin of the vessel from the right pulmonary artery (red arrow) which is implicated in the communication with a branch of pulmonary vein is depicted. CT = computed tomography; LA = left atrium; MPA = main pulmonary artery; PA = pulmonary artery; PV = pulmonary vein; RA = right atrium; SVC = superior vena cava.

Corresponding author:

Dr. Ilias Karabinos, Athens  
Euroclinic, 9 Athanassiadou Street,  
11521 Athens, Greece;  
Tel: +30 2106416660, +30 6977614311;  
Fax: +30-210-6416661;  
Email: ilias.karabinos@lycos.com

**Conflict of Interest:** none declared

symptoms of diplopia, dysarthria and right facial weakness over the preceding 3 hours, suggestive of a stroke. She also had history of two strokes in the past at the age of 29 and 45 years old, but work up had been inconclusive for any definite cause of those pathologies.

Upon admission, the patient was submitted to an emergency brain computed tomography (CT) scan, which excluded intracranial hemorrhage. Immediately afterwards, thrombolytic treatment was administered with use of recombinant tissue plasminogen activator (r-TPA 1 mg/kg) with successful outcome. Brain magnetic resonance imaging (MRI) confirmed an acute ischemic stroke in the region of the left thalamus. Carotid ultrasound, digital subtraction angiography of cerebral arteries, and transthoracic echocardiography did not reveal any causal pathology. The patient also underwent transesophageal

echocardiography in order to search for any source of cardiac emboli. Although no pathology involving the atrial septum was detected both at rest and after Valsalva maneuver (Video 1, Figure 1, panel A), we proceeded with infusion of 10 ml of agitated normal saline (bubble contrast) that revealed an early- after five cardiac cycles- (Video 2, panel B red arrow) massive inflow of microbubbles to the left atrium (Video 2, panel B yellow arrow). Since the exact point of this interatrial communication had not been identified, we performed CT-angiography of the pulmonary circulation which revealed an arterio-venous fistula between the right pulmonary artery and the right superior pulmonary vein (panels C, D). The patient was proposed to have this arterio-venous fistula occluded percutaneously.