

VIDEO SESSION - CASE REPORT

Angiosarcoma of the Heart: from Primary Location to Rapid Extension

Christos Tountas, MD, Anastasios Theodosis-Georgilas, MD,
Dimitrios Beldekos, MD

CASE REPORT

*Echocardiography Laboratory,
Cardiology Department, Tzaneio
Hospital, Piraeus, Greece*

KEY WORDS: *cardiac angiosarcoma;
cardiac tumor; pericardial effusion;
cardiac tamponade; metastases*

A 68-year-old man was admitted to our department with severe dyspnea and hemodynamic instability. The initial echocardiogram revealed a massive pericardial effusion with signs of tamponade. Urgent pericardiocentesis was performed. The cytological examination of the pericardial fluid was negative for malignant cells but the pre-discharge transthoracic echocardiogram depicted a heterogeneous tissue (mass) in the right atrium (Fig. 1, arrow). The subsequent transesophageal echocardiogram revealed a large sessile heterogeneous mass adherent to the right atrial free wall, extending into the inferior vena cava (Fig. 2, arrow).

In order to further characterize the tissue, computed tomography (CT) with contrast enhancement and magnetic resonance imaging (MRI) were performed (Fig. 3 & 4). The previous findings were confirmed. The large mass (60x45x45 mm) had an irregular outline, occupied the inflow area of the right atrium and infiltrated the free wall and the pericardium. Contrast enhancement was heterogeneous and the signals on T1- and T2- weighted MRI images were intermediate and intermediate high respectively. With these findings the diagnosis of a malignant neoplasm was made. The work-up did not show any other primary or metastatic locations and a further cardiothoracic consultation was suggested but the patient refused and thus he was discharged.

Three months later the patient returned with dyspnea on exertion and fatigue. Transthoracic echocardiography showed a medium pericardial effusion and the same characteristic tumor but further tests showed metastases to liver, spleen and both adrenals. Fine needle biopsy of metastatic liver tissue revealed angiosarcoma. Un-

ABBREVIATIONS

CT = computed tomography

MRI = magnetic resonance imaging

Correspondence to:

Dimitrios Beldekos, MD

E-mail: beldekos_d@yahoo.gr

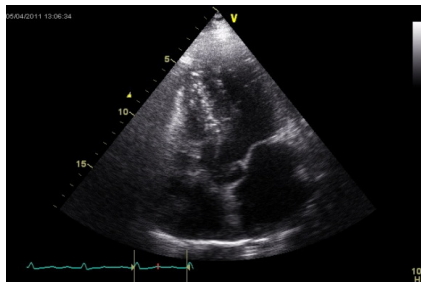


FIGURE 1. Transthoracic echocardiogram.

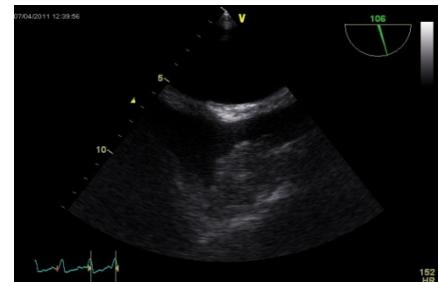


FIGURE 2. Transesophageal echocardiogram.

Conflict of Interest: none declared

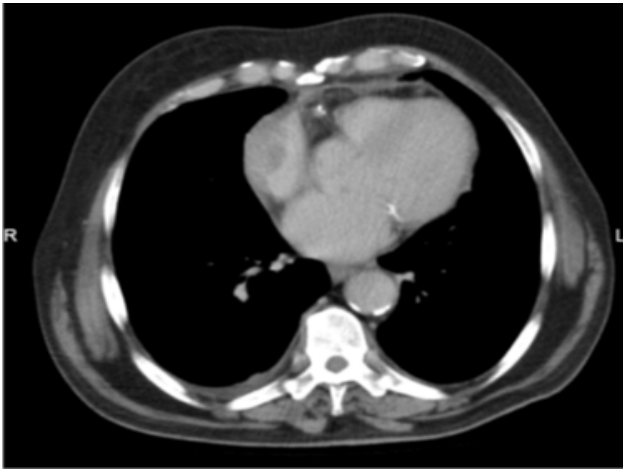


FIGURE 3. Computed tomography (CT) of the heart.

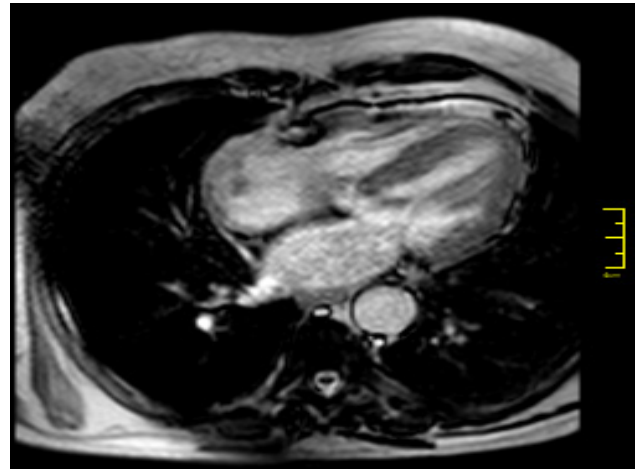


FIGURE 4. Magnetic resonance imaging (MRI) of the heart.

fortunately hematological abnormalities did not permit any chemotherapy and the patient died soon after.

The absence of any other primary or metastatic lesions on the initial work-up suggests that the tumor was a primary cardiac angiosarcoma of the right atrium with a rapid metastatic progression.

REFERENCES

1. Thiene G, Valente M, Lombardi M, Basso C. Tumours of the

heart. In: Camm AJ, Lüscher TF, Serruys PW (eds). *The ESC Textbook of Cardiovascular Medicine*, 2nd ed. Oxford: Oxford University Press, 2009, pp.735–61.

2. Burke A, Jevdy J, Virmani R. Cardiac tumours: an update. *Heart* 2008; 94:117–123.

3. Yuan S-M, Shinfeld A, Lavee J, Kuperstein R, Haizler R, Raanani E. Imaging morphology of cardiac tumours. *Cardiol J* 2009; 16:26–35.