

CASE REPORT

Ectopic Mediastinal Thyroid Tissue - A Case Report and Review of the Literature

Nikolaos Barbetakis, MD, Asterios Chnaris, MD, Pavlos Papoulidis, MD,
Paschalis Siobolas, MD, Georgios Kostopoulos, MD

*Cardiothoracic Surgery Department,
“G. Papanikolaou” General Hospital,
Thessaloniki, Greece*

ABSTRACT

BACKGROUND: Ectopic intrathoracic thyroid is a very rare presentation of a mediastinal mass, comprising 1-3% of retrosternal goiters and about 1% of mediastinal tumors.

CASE PRESENTATION: A case of a 59-year-old man with a mediastinal mass that proved to be ectopic intrathoracic thyroid tissue is presented. The mass was completely excised through a right posterolateral thoracotomy and pathologic examination confirmed multinodular goiter. Relevant literature is briefly reviewed.

CONCLUSION: Surgical removal relieved symptoms, excluded malignancy and provided a definite diagnosis of a mediastinal mass.

KEY WORDS: *ectopic thyroid, middle mediastinum, thoracotomy*

Ectopic intrathoracic thyroid is a very rare presentation of a mediastinal mass, comprising 1-3% of retrosternal goiters and about 1% of mediastinal tumors.¹ Ectopic thyroid tissue may be found between the foramen ceacum and the normal position of thyroid gland. The most frequent locations are along the midline from the base of the tongue to the mediastinum.² Ectopic thyroid tissue has been described in the submandibular region, trachea, heart, lung duodenum, adrenal gland and parotid salivary gland.³

A case of a 59-year-old man with a middle mediastinal mass that proved to be ectopic intrathoracic thyroid tissue is presented. The mass was completely excised through a right posterolateral thoracotomy and pathologic examination confirmed multinodular goiter.

CASE PRESENTATION

A 59-year-old man presented to our department for management of a mediastinal mass. He had a history of cough and dyspnea over the last year. Physical examination was normal. He had undergone total thyroidectomy 8 years earlier, and had been placed on thyroid supplement ever since. Thyroid function tests done a week prior to admission were normal. Chest radiography revealed a mass in the superior mediastinum with tracheal deviation (Figure 1). Computed tomographic scan of the chest showed a

Correspondence to:
Nikolaos Barbetakis,
Himarras 25, Pilea, Thessaloniki
55535, Greece.
Tel: 697 2039345,
e-mail: nibarbet@yahoo.gr

*Manuscript received May 3, 2009;
Accepted after revisions February 19, 2010*

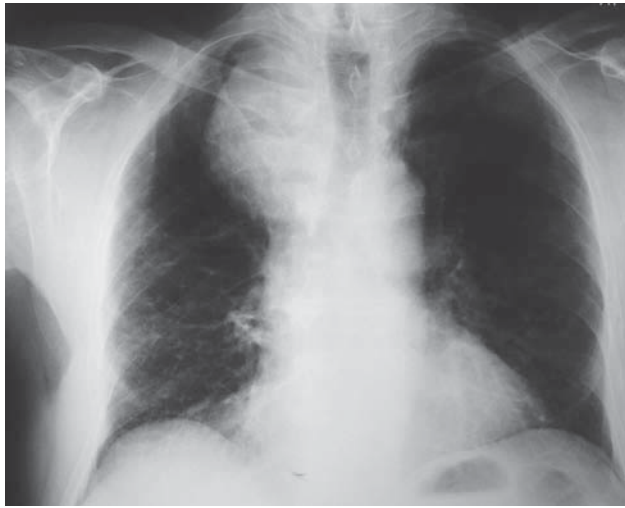

FIGURE 1. Chest x-ray revealed a mass in the superior mediastinum with tracheal deviation.

round mass, 60x50 mm in size, at the right side of the middle mediastinum (Figure 2). The T1 weighted coronal images of magnetic resonance imaging (MRI) showed a hypointense mass with regular contours near the superior vena cava and the right atrium. MRI was deemed necessary for preoperative assessment of the mediastinal mass in order to get information concerning possible vascular invasion. Preoperative staging of the mediastinal mass (abdomen, brain and bone scans) was negative for metastatic disease.

Subsequently, the patient was subjected to surgery. A typical right posterolateral thoracotomy was performed. Intraoperative findings revealed a firm and encapsulated mass in the middle mediastinum next to the superior vena cava and the trachea (Figure 3). The mass derived its blood supply from intrathoracic vessels and was easily excised (Figures 4 & 5). Frozen section was consistent with ectopic thyroid tissue. Histopathologic examination of the mass, using hematoxylin-eosin, revealed multinodular goiter (Figure 6). The postopera-

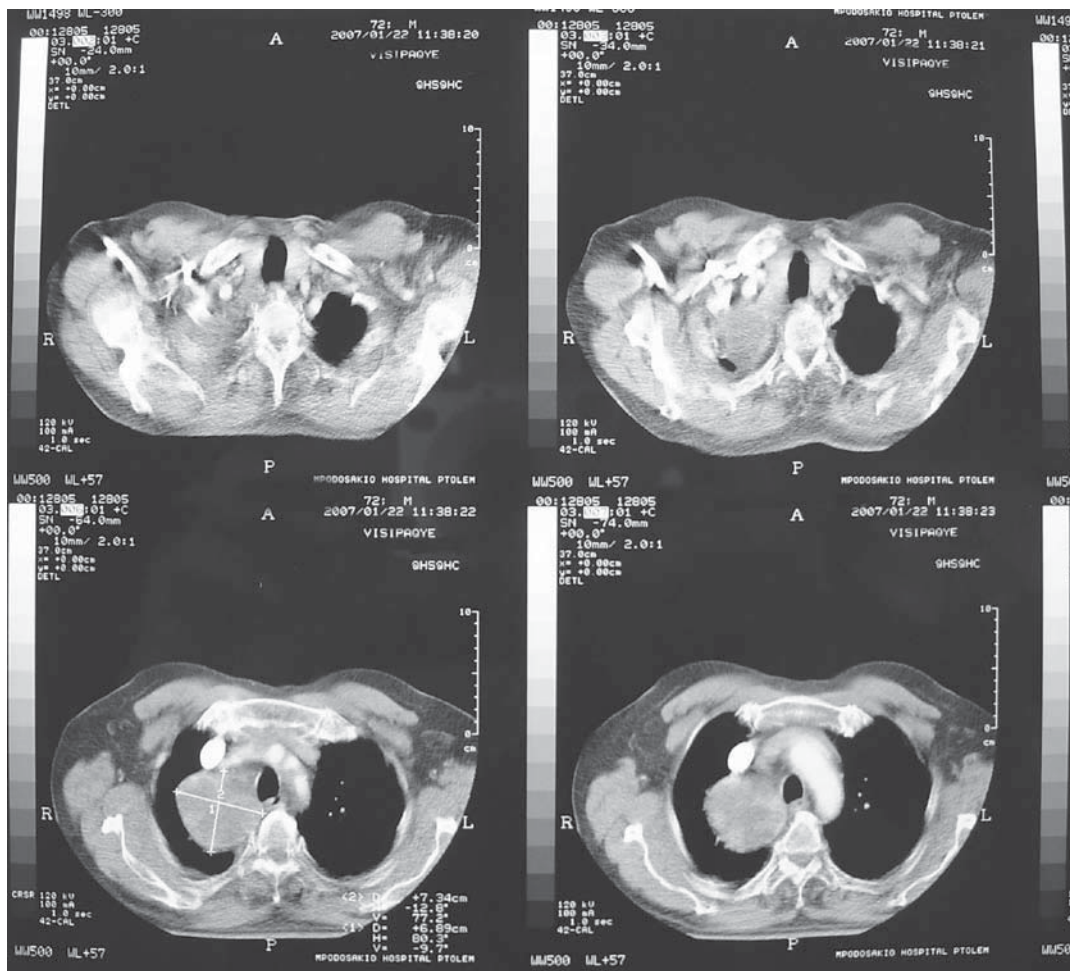


FIGURE 2. Computed tomographic scan of the chest showed a round mass, 60X50 mm in size, at the right side of the middle mediastinum.

ECTOPIC THYROID TISSUE

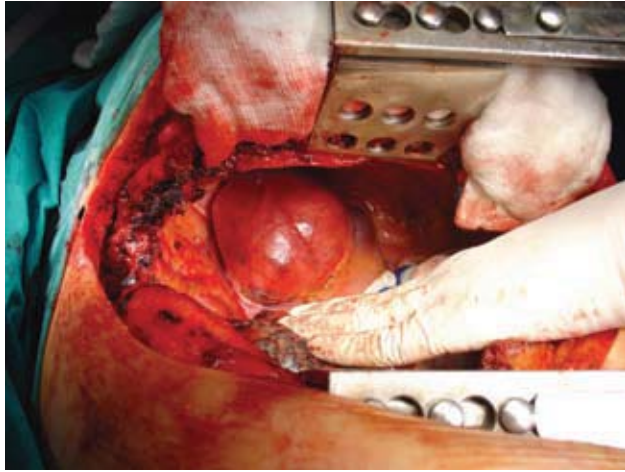


FIGURE 3. Intraoperative findings revealed a firm and encapsulated mass in the posterior mediastinum next to the superior vena cava and the trachea.

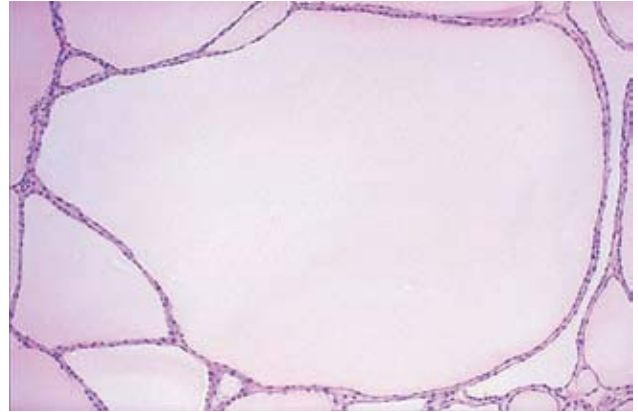
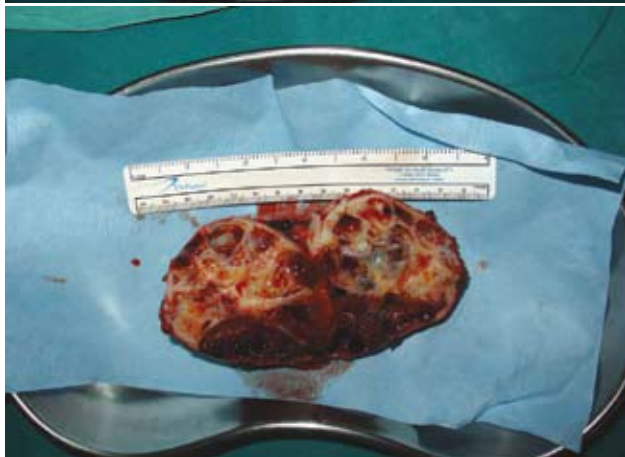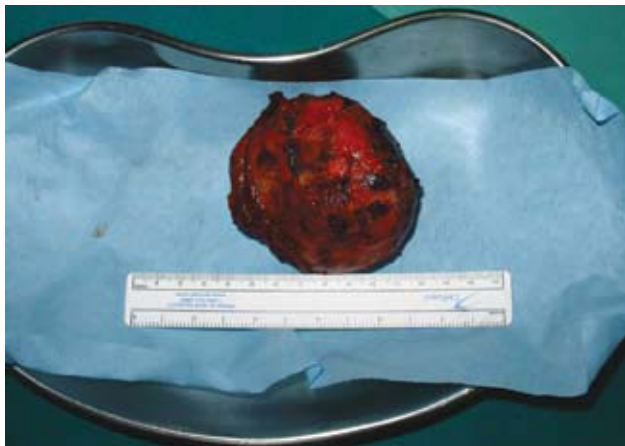


FIGURE 6. Histopathologic examination of the mass, using hematoxylin-eosin revealed multinodular goiter (irregularly enlarged follicles with flattened epithelium consistent with inactivity).



FIGURES 4,5. Macroscopic appearance of the resected specimen.

tive period was uneventful.

DISCUSSION

Ectopic thyroid tissue has been found along the midline from the base of the tongue to the mediastinum. Ninety percent of the reported cases are found at the base of the tongue, while only 10% lie in the anterior aspect of the neck superficial to the hyoid bone. Ectopic thyroid tissue is rarely found in other locations.^{3,4}

Heterotopic thyroid tissue in the anterior mediastinum has probably originated embryologically from rudiments of developing thyroid dragged into the chest during the descent of the heart and great vessels with the development of the embryonic neck and the unfolding of the embryo.⁵ Ectopic intrathoracic thyroid can be distinguished from substernal goiter or secondary intrathoracic goiter from the fact that the former receives its blood supply from mediastinal vessels rather than the neck and is not connected to the cervical thyroid except from a thin band of connective tissue.¹

Patients with intrathoracic thyroid are usually asymptomatic with the tumor reported as an incidental finding on chest roentgenogram. They are usually euthyroid as in the present case. Sometimes they may present with respiratory symptoms similar to those of this patient, like cough, dyspnea or hemoptysis. Less commonly, patients may present with dysphagia, weight loss, chest pain or superior vena cava syndrome.

Chest x-ray is usually diagnostic for a soft tissue mass. Other findings include tracheal displacement, tracheal compression and calcifications. Chest computed tomography and magnetic resonance imaging provide important information about the location of the ectopic thyroid tissue and its relation

with the great vessels and other mediastinal structures. Scintigraphy, when intrathoracic thyroid is suspected, is useful and effective for differential diagnosis of other mediastinal tumors. However, uptake of the ¹³¹I is not always observed in ectopic thyroid tissue and scintigraphy is not always diagnostic.⁶

True malignant transformation in ectopic thyroid tissue is extremely rare.⁷ Nevertheless, these masses should be resected surgically due to the risks of malignant transformation, progressive enlargement, hemorrhage within the mass causing respiratory failure, and compression of neighbouring vital mediastinal organs.⁸

With regards to the surgical approach, thoracotomy provides both surgical convenience and allows a complete resection with easy access and better visualization.⁹ According to our experience, axillary thoracotomy although muscle sparing, is not indicated for surgical treatment of mediastinal masses, especially in cases with no definite preoperative diagnosis. Thoracoscopic excision has also been reported with excellent results.¹⁰ Operability must be determined early and in many cases is not able to be confirmed until after thoracotomy or sternotomy. Surgery has a very low mortality rate (0-2%) and an acceptable morbidity.¹¹ Prognosis following a successful surgical excision is excellent.

REFERENCES

1. Sakorafas G, Vlachos A, Tolumis G, Kassaras G, Anagnostopoulos G, Gorgogiannis D. Ectopic intrathoracic thyroid. Case report. *Mt Sinai J Med* 2004;71(2):131-133.
2. Ozpolat B, Dogan OV, Gokaslan G, Ereku S, Yucel E. Ectopic thyroid gland on the ascending aorta with a partial pericardial defect. Report of a case. *Surg Today* 2007;37:486-488.
3. Mysorekar VV, Dandekar CP, Sreevathsa MR. Ectopic thyroid tissue in the parotid salivary gland. *Singapore Med J* 2004;45:437-438.
4. Kuffner HA, McCook BM, Swaminatha R, Myers EN, Hunt JL. Controversial ectopic thyroid. A case report of thyroid tissue in the axilla and benign total thyroidectomy. *Thyroid* 2005;15(9):1095-1097.
5. Gamblin TC, Jennings GR, Christie DB, Thompson WM Jr, Dalton ML. Ectopic thyroid. *Ann Thorac Surg* 2003;75:1952-1953.
6. Mack E. Management of patients with substernal goiters. *Surg Clin North Am* 1995;75:377-394.
7. Shah BC, Ravichand CS, Juluri S, Agarwal A, Pramesh CS, Mistry RC. Ectopic thyroid cancer. *Ann Thorac Cardiovasc Surg* 2007;13:122-124.
8. Guimaraes MJ, Valente CM, Santos L, Baganha MF. Ectopic thyroid in the anterior mediastinum. *J Bras Pneumol* 2009;35(4):383-387.
9. Bremerich J, Pippert H. Ectopic thyroid tissue: an unusual differential diagnosis of space-occupying mediastinal lesions [Article in German]. *Schweiz Med Wochenschr* 1997;127(7):266-270.
10. Grondin SC, Buenaventura P, Luketich JD. Thoracoscopic resection of an ectopic intrathoracic goiter. *Ann Thorac Surg* 2001;71:1697-1698.
11. Houck WV, Kaplan AJ, Reed CE, Cole DJ. Intrathoracic aberrant thyroid: identification critical for appropriate operative approach. *Am Surg* 1998;64:360-362.