

ATHENS CARDIOLOGY UPDATE 2008

Recurrent Stent Thrombosis After Rescue Angioplasty

Periklis A. Davlouros, MD

CASE REPORT

*Lecturer, Invasive Cardiology &
Congenital Heart Disease
Patras University Hospital*

A 70-year-old woman with hypertension and family history of coronary artery disease (CAD) was admitted with acute chest pain to Kalavrita general hospital. ECG was compatible with an anterior wall STEMI. The patient was on Killip class III heart failure. Thrombolysis (reteplase) was administered along with diuretics, heparine, ASA, clopidogrel, nitroglycerin and an ACE inhibitor. However the chest pain persisted as did the ST elevation. She developed cardiac arrest (VF), from which she was successfully resuscitated and transferred to the next larger on call hospital (“Agios Andreas” general hospital) in Patras. The chest pain persisted and the patient was next transferred to Patras University Hospital for possible rescue angioplasty.

Coronary angiography showed a proximal LAD occlusion and a 99% stenosis of mid RCA (Fig. 1 & 2). Heparin, abciximab, extra clopidogrel were administered and LAD angioplasty was performed (Figure 1). Intracoronary adenosine was administered before stenting and a 3/21 mm bare metal stent was placed successfully in the LAD, without residual stenosis and a TIMI-III flow. The patient had an uneventful course with peak CK of 3207 IU and an ejection fraction (EF) of 45-50%. Four days later the RCA lesion was treated with a 3/18 mm bare metal stent (Fig. 2).

The next day the patient developed acute chest pain with 7-10 mm anterolateral wall ST elevation and acute pulmonary edema. A new coronary angiography revealed a subacute stent thrombosis of the LAD (Fig. 3). Tirofiban was started and balloon angioplasty followed. A lot of thrombus was seen inside the LAD stent. Thrombus extraction was not helpful and two bare metal stents (3/15 & 3/10 mm) were placed in the LAD with good result and a TIMI-III flow. A new echocardiogram disclosed an EF of 35-40%.

Twenty-four hours later, while being in the CCU, the patient developed chest pain with recurrent anterior wall ST elevation. Thrombolysis was administered (half dose reteplase). The next day the patient developed confusion and right hemiplegia. A brain CT scan disclosed a large left parietal lobe hematoma. ASA and clopidogrel were stopped. Thirteen days later the patient was discharged only on ASA with right hemiplegia and an EF of 30%.

Three days latter the patient developed fever (39 °C) and vomiting and was admitted to Kalavrita general hospital. Acute gastroenteritis was diagnosed and antibiotics administered. Two days latter she developed acute epigastric pain with inferior wall ST elevation. She was transferred to Patras University Hospital with a view to primary angioplasty. The patient was in cardiogenic shock and supported with dopamine and dobutamine. Coronary angiography followed and disclosed an RCA stent thrombus creating an 80% stenosis. Tirofiban and clopidogrel loading were administered and angioplasty was done. A new bare metal stent (3/10 mm) was placed in the RCA (Fig.

Address for correspondence:
Periklis A. Davlouros, MD
Lecturer, Invasive Cardiology &
Congenital Heart Disease
Patras University Hospital
E-mail: pdav1@otenet.gr

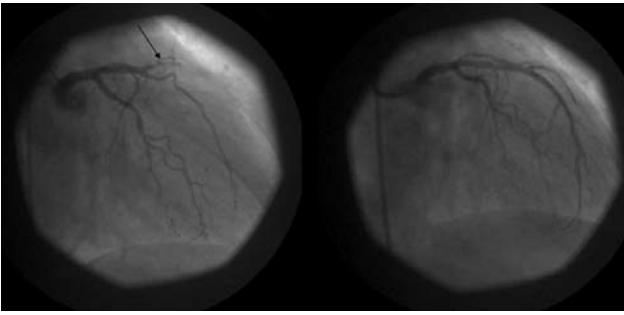


FIGURE 1. Rescue angioplasty. Occluded LAD (arrow), before (left) and after stenting (right)

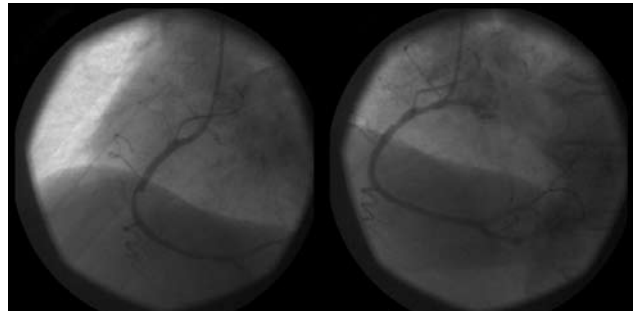


FIGURE 4. Late RCA stent thrombosis, before (left) and after stenting (right)

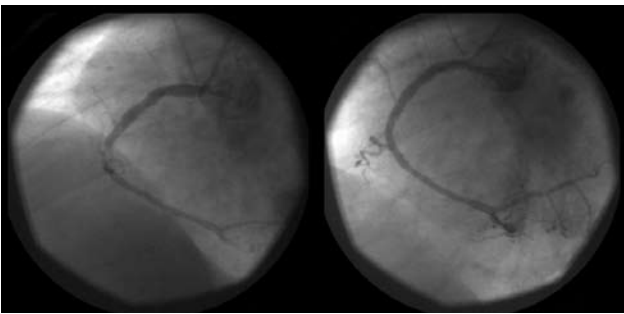


FIGURE 2. PCI on RCA, 4 days after rescue PCI of the LAD. RCA stenosis, before (left) and after stenting (right)

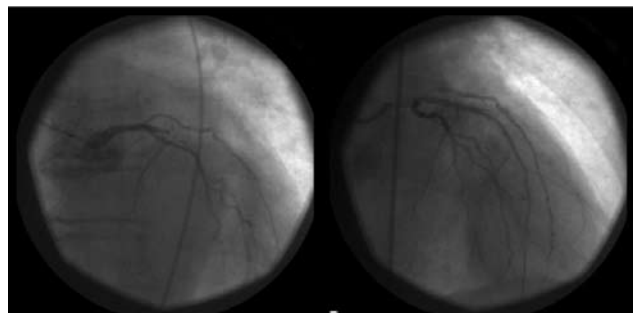


FIGURE 5. Late LAD stent thrombosis, before (left) and after plain balloon angioplasty (right)

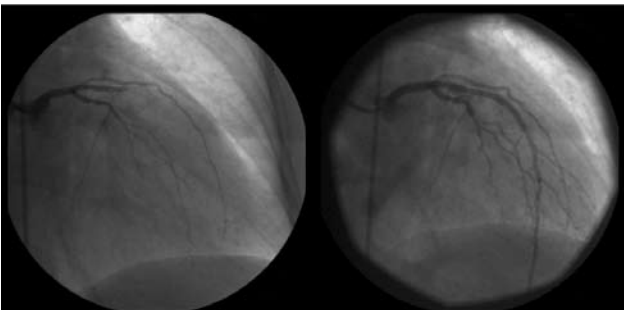

FIGURE 3. 24 hours after RCA PCI, LAD stent thrombosis, before (left) and after stenting (right)

4). When the LAD was checked we were surprised to unravel a total occlusion, which was treated with plain angioplasty (Fig. 5). Peak CK was 2230 IU and the EF 25-30%. The patient developed right lung pneumonia, from which she recovered and was discharged after a long hospital course (19 days) on both ASA and clopidogrel.