

ATHENS CARDIOLOGY UPDATE 2008

Clinical Utility of Cardiovascular Magnetic Resonance Imaging for Diagnosis of Acute Myocarditis

Emmanouil N. Karatzis, MD, Nikolaos Sourlas, MD,
George Tsakonas, MD, Athanasios G. Pipilis, MD, Nikolaos Kritikos, MD,
Peter G. Danias, MD, PhD

CASE PRESENTATION

*Cardiac MRI Center (ENK, NK, PGD)
and the 1st (NS, GT, AGP) and 2nd
(PGD) Cardiology Clinics, Hygeia
Hospital, Maroussi Athens Greece
and Tufts University School of
Medicine, Boston MA (PGD)*

A 49 year-old patient with past medical history significant for arterial hypertension (treated with telmisartan 80 mg daily), presented to the emergency department with 18-hour gastric discomfort and fatigue. Five days prior to this presentation the patient had an episode of febrile gastroenteritis. The evening prior to presentation the patient had blood chemistries performed at an outside institution, where an increase of myocardial enzymes (troponin and CPK-MB) were noted.

On presentation the patient was uncomfortable due to abdominal pain, but the clinical examination was almost normal. Blood pressure was 150/80 mmHg and heart rate was 60 beats/min. Cardiac S1 and S2 sounds were audible, without additional cardiac tones, murmurs, pericardial or pleural friction. There was no jugular venous distention, rales or peripheral edema present. Admission 12-lead electrocardiogram (ECG) demonstrated normal sinus rhythm with a rate of 60 beats/min, and early repolarization pattern with a slight J-point elevation in the lateral leads (I, aVL, V5, V6).

Initial chemistries showed elevated CPK-MB (>80 ng/ml, normal values <4.3 ng/ml), myoglobin (364 ng/ml, normal values <107 ng/ml), Troponin I (10.2 ng/ml, normal values < 0.40 ng/ml), C-reactive protein (3.2 mg/dl, normal values <0.5 mg/dl), and sedimentation rate (72 mm/1st hour, normal value <15 mm).

The patient was admitted to the ICU for close monitoring. A transthoracic echocardiogram was performed and revealed normal left ventricular systolic function with borderline thickness of interventricular septum (11 mm) and a slight hypokinesia in the mid-lateral wall. There was no pericardial effusion noted. The working diagnosis was myocarditis after the recent episode of viral gastroenteritis but an acute coronary syndrome could not be excluded, particularly since there were regional wall motion abnormalities. Therefore the patient underwent cardiac catheterization and coronary angiography, which demonstrated no atherosclerotic lesions. A 24-hour Holter recording was also performed and demonstrated no significant tachy- or bradyarrhythmias. A cardiovascular magnetic imaging (CMR) study was performed to establish the diagnosis and to assess for ongoing inflammation.

CMR demonstrated a normal size left ventricle (end diastolic left ventricular volume 68 ml/m²) with normal systolic function (ejection fraction 72% and indexed cardiac output 3.0 L/min/m²). The focal hypokinesia of the mid-lateral wall was also confirmed. Following gadolinium intravenous administration (0.2 mmol/kg) early enhancement of the lateral wall was noted in T1 imaging. Subepicardial – midwall

Address for correspondence:
Peter G. Danias MD, PhD,
Cardiac MR Center, Hygeia Hospital,
4 Erythrou Stavrou Street, Maroussi
15123 Greece. Tel/Fax +30 (210)
686-7057; E-mail: pdanias@hygeia.gr;
peter.danias@tufts.edu

late enhancement was also evident in the same territory. T2-weighted black blood images also showed increased signal in the same territory (Fig. 1).

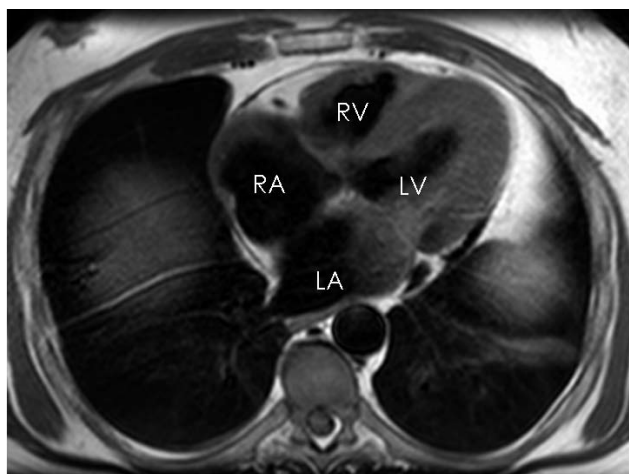
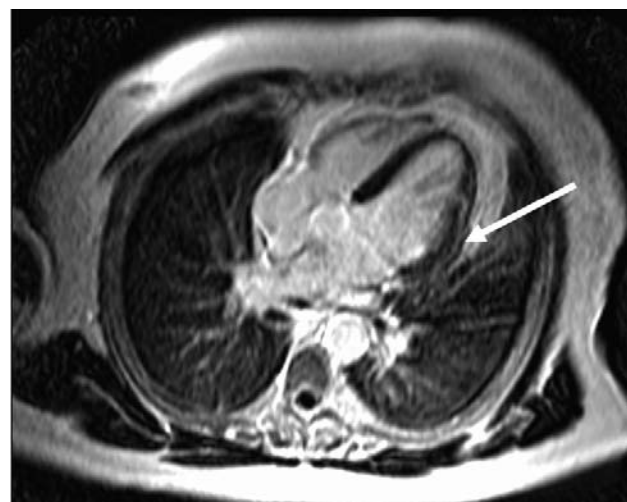
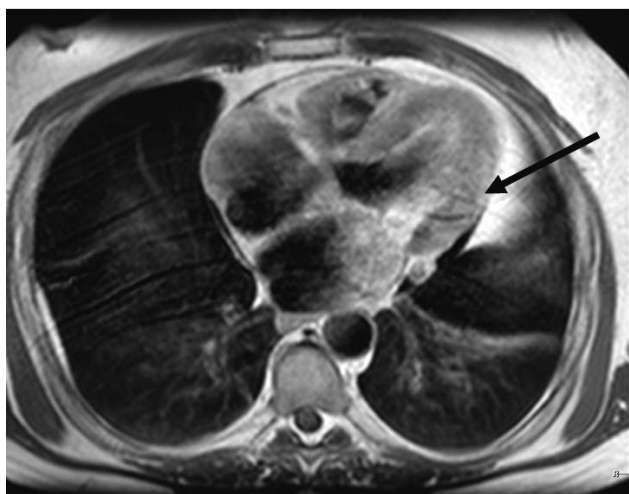


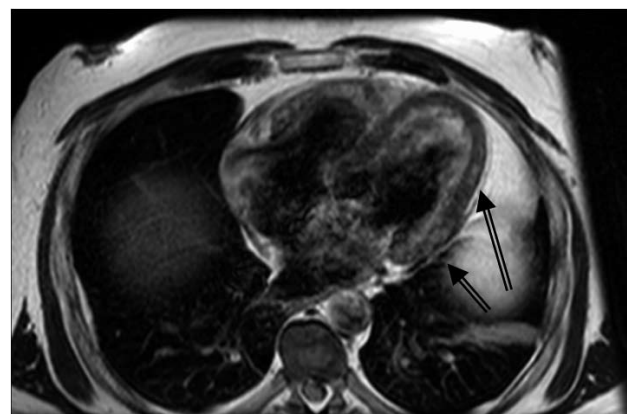
FIGURE 1. (a) T1-weighted black-blood transverse image. LA=left atrium, LV=left ventricle, RA=right atrium, RV=right ventricle



(c) Delayed contrast-enhanced image in the 4-chamber orientation. The lateral wall demonstrates subepicardial enhancement (white arrow).



(b) T1-weighted black blood image after administration of gadolinium (gadodiamide, 0,2mmol/kg). The epicardial layer of the mid-lateral wall demonstrates increased signal compared to the rest of the myocardium (arrow).



(d) T2-weighted black blood transverse image. The mid layer of the lateral wall demonstrates increased signal compared to the rest of the myocardium (open arrows).

Patient' symptoms improved over the subsequent days. Serologies for viral infection were ordered and demonstrated borderline IgM coxackie B5 titers (positive at dilution 1/128). Titers for echo-viruses, adeno-viruses, CMV, EBV, HSV 1 and 2, HZV, RSV, measles, mumps, influenza and parainfluenza were negative.

The patient remained stable and blood chemistries gradually returned to normal within 5 days. The patient was discharged home on b-blocker therapy in stable condition after a 7-day hospital stay.

COMMENTARY

The case that we hereby present is a rather typical case of viral myocarditis. The clinical, ECG and imaging data all corroborate the diagnosis. The case nicely demonstrates the role of CMR for the diagnosis of myocarditis and presents the typical findings of this disease.

CMR is a novel imaging technique that provides precise

anatomic and functional assessment of the heart. In patients with acute myocarditis regional systolic function may be normal or impaired, and in some cases it may be impossible to differentiate between myocarditis and acute coronary syndrome based on clinical, ECG and regional wall motion grounds alone (1,2). For the diagnosis of myocarditis CMR compares favorably to other imaging techniques because it also provides information on tissue consistency and characteristics (3,4).

T2-weighted black-blood sequences are very sensitive to increased water content (e.g. tissue edema), presenting areas of active inflammation as having high signal. With T1-weighted sequences, early gadolinium enhancement suggests increased blood flow and/or vascular permeability, suggestive of active inflammation. Delayed gadolinium enhancement suggests increased extravascular space (volume of distribution for the contrast agent), which is also consistent with active inflammation. The distribution of signal enhancement is epicardial or mid-layer, as opposed to subendocardial for myocardial infarction.

The location of myocardial involvement may be associated to the type of pathogenic virus. Infections with parvovirus B19 have been reported to have mostly lateral left ventricular wall findings, while infections from herpes virus 6 predominantly affect the septal wall (5). Patient prognosis may be associated with the CMR findings. Those with early resolution of signs of

myocardial inflammation likely have better prognosis (4,6).

In summary, CMR is a valuable tool for the accurate diagnosis and possibly for assessment of prognosis in patients with suspected acute myocarditis.

REFERENCES

1. Angelini A, Calzolari V, Calabrese F, et al. Myocarditis mimicking acute myocardial infarction: role of endomyocardial biopsy in the differential diagnosis. *Heart*. 2000;84:245-50.
2. Miklozek CL, Crumpacker CS, Royal HD, et al. Myocarditis presenting as acute myocardial infarction. *Am Heart J*. 1988;115:768-76.
3. Pipilis AG and Dianas PG. Cardiac magnetic resonance imaging in acute myocarditis. *Hellenic J Cardiol* 2004;45:176-177.
4. Friedrich MG, Strohm O, Schulz-Menger J, et al. Contrast media-enhanced magnetic resonance imaging visualizes myocardial changes in the course of viral myocarditis. *Circulation*. 1998;97:1802-9.
5. Mahrholdt H, Wagner A, Deluigi CC, et al. Presentation, patterns of myocardial damage, and clinical course of viral myocarditis. *Circulation*. 2006;114:1581-90.
6. Wagner A, Schulz-Menger J, Dietz R, Friedrich MG. Long-term follow-up of patients with acute myocarditis by magnetic resonance imaging. *MAGMA*. 2003;16:17-20.