

CASE REPORT

“Chasing the Dragon” – Toxic Leukoencephalopathy. A Case Report

Despina Kriketou, MD, MSc,¹ Santroninos Papadakis, MD, MSc, EDiR,¹
Antonis Tavernarakis, MD,² Demetrios Exarhos, MD, PhD¹

¹Department of Computed Tomography and Magnetic Resonance Imaging, Evangelismos Hospital, Athens, Greece
²Department of Neurology, Evangelismos Hospital, Athens, Greece

KEY WORDS: *chasing the dragon; heroin toxicity; toxic leukoencephalopathy; MRI*

ABSTRACT

Toxic leukoencephalopathy occurs as a result of exposure to a wide variety of drugs such as cocaine, ethanol, 3,4-ethylenedioxymethamphetamine, intravenous heroin, psilocybin, toluene as well as inhaled heroin pyrolysate. The leukoencephalopathy caused by inhaled heroin called “chasing the dragon” results in characteristic signal abnormalities on MRI but may present similarities to other toxic leukoencephalopathies as well. We present a case of heroin vapour abuse with a cerebral MRI presenting symmetrical T2 hyperintensities in both of the temporal lobes, the centrum semiovale, the right occipital lobe, and the splenium of the corpus callosum, with restricted diffusion. The MRI findings quickly improved and the patient gradually recovered.

INTRODUCTION

The use of heroin, a diacetyl derivate of morphine, is common among drug addicts. Heroin may be used in different ways: intravenously, subcutaneously, smoked, sniffed, or inhaled.

The term “**chasing the dragon**”, or “chinesing” or “chinese blowing” originates in the 1920s’ China and became rather popular in the 1950s in Hong Kong, since that impure drug form was cheap and thus widely consumed. To consume a small quantity of powder it is placed on an aluminum foil and then heated with a lighter. The heroin powder liquefies into a reddish brown glob (pyrolysate), emitting a white vapor, called “dragon” which is “chased” with the lighter underneath while the vapor is sucked through a straw or pipe. Heroin intended for smoking is usually 30% to 40% pure, since the purest forms degrade too quickly for effective smoking. Additionally, according to reports, heroin is mainly available in a non-intravenous base form¹.

That form is linked to toxic leukoencephalopathy although the exact pathogenesis is still unclear with characteristic and highly specific signal abnormalities on MRI, which can greatly aid in proper diagnosis². The term leukoencephalopathy generally refers to a disease of the white matter of the brain and therefore this entity involves motor, sensory and visual systems. Leukoencephalopathy can also disrupt cognitive and emotional functions. The clinical manifestations of the disease reflect the areas of the brain damaged as the disease processes. Clinical features range from inattention, forgetfulness and personality changes, to dysarthria, ataxia, dementia, coma and death.

ABBREVIATIONS

CT scan: computed tomography
DWI: diffusion weighted image
FLAIR: fluid attenuation inversion recovery
MRI: magnetic resonance imaging
NAA: N-acetylaspartate

Correspondence to:

Despina Kriketou, MD, MSc
Department of MRI/CT
45 Ypsilantou street, PC 106 76,
Athens, Greece;
Tel.: +30 6974706936;
E-mail: deskrik86@yahoo.gr

*Manuscript received June 18, 2015;
revised manuscript received March 15,
2018; Accepted July 12, 2018*

Conflict of Interest: none declared

CASE PRESENTATION

Our patient was a 23 year old female presenting in the ER with dysarthria, bradykinesia, and ataxia. The patient inhaled heroin one week before the onset of the symptoms. She was tachypneic, but hemodynamically stable (145/90 mmHg) with a normal sinus rhythm. Corneal reflexes were present bilaterally and the motor examination revealed axial myoclonus. General examination revealed no cardiac murmurs, whilst the chest and abdomen were unremarkable. No needle marks were observed on the skin.

A brain CT scan revealed low attenuation regions bilaterally involving the temporal lobes, the splenium of the corpus callosum and the centrum semiovale.

Further evaluation with MRI imaging (Fig. 1) showed symmetric hyperdensity concerning both the temporal lobes, the splenium of the corpus callosum, the centrum semiovale and an area in the right occipital lobe on T2W images and fluid-attenuated inversion recovery (FLAIR). Diffusion weighted imaging (DWI) showed abnormal restricted

diffusion in these areas, while contrast-enhanced axial T1W image demonstrated enhancement bilaterally in the temporal lobes and right occipital lobe.

The MRI findings (Fig. 2) improved in 13 days and the patient gradually recovered. After 13 days a new MRI revealed the absence of hyperdensity while the enhancement remained practically the same.

DISCUSSION

The first and largest outbreak of this type of toxic leukoencephalopathy linked to “chasing the dragon” was reported in 1982 in the Netherlands, and included 47 cases, 11 (23%) of whom died³. Since then, similar cases have been reported sporadically in both Europe and the United States. The primary hypothesis, although a specific etiology was not identified is that a contaminant in the heroin or a combustion by-product causes the lesions mentioned above⁴. Additionally, Buxton et al support that there is also a dose depending response effect

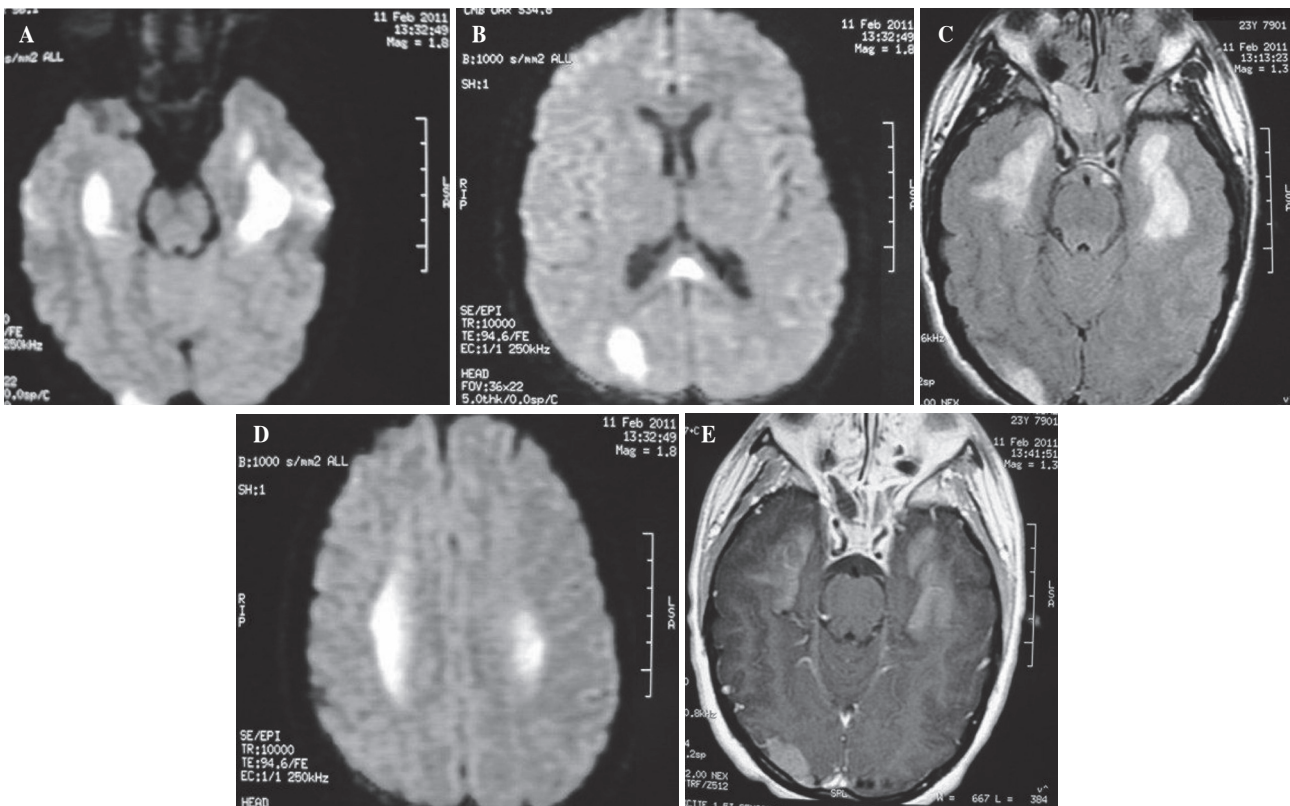


FIGURE 1. 23 year old female who had inhaled heroin 1 week before. (A) Axial T2-weighted MR image and (B) FLAIR image: hyperintensity in the temporal lobes and an area of hyperintensity in the right occipital lobe. (C) Axial DWI reveals restricted diffusion bilaterally in the temporal lobes and right occipital lobe, (D) in the right occipital lobe and splenium and in the centrum semiovale. (E) Contrast-enhanced axial T1W image demonstrates enhancement bilaterally in the temporal lobes and right occipital lobe.

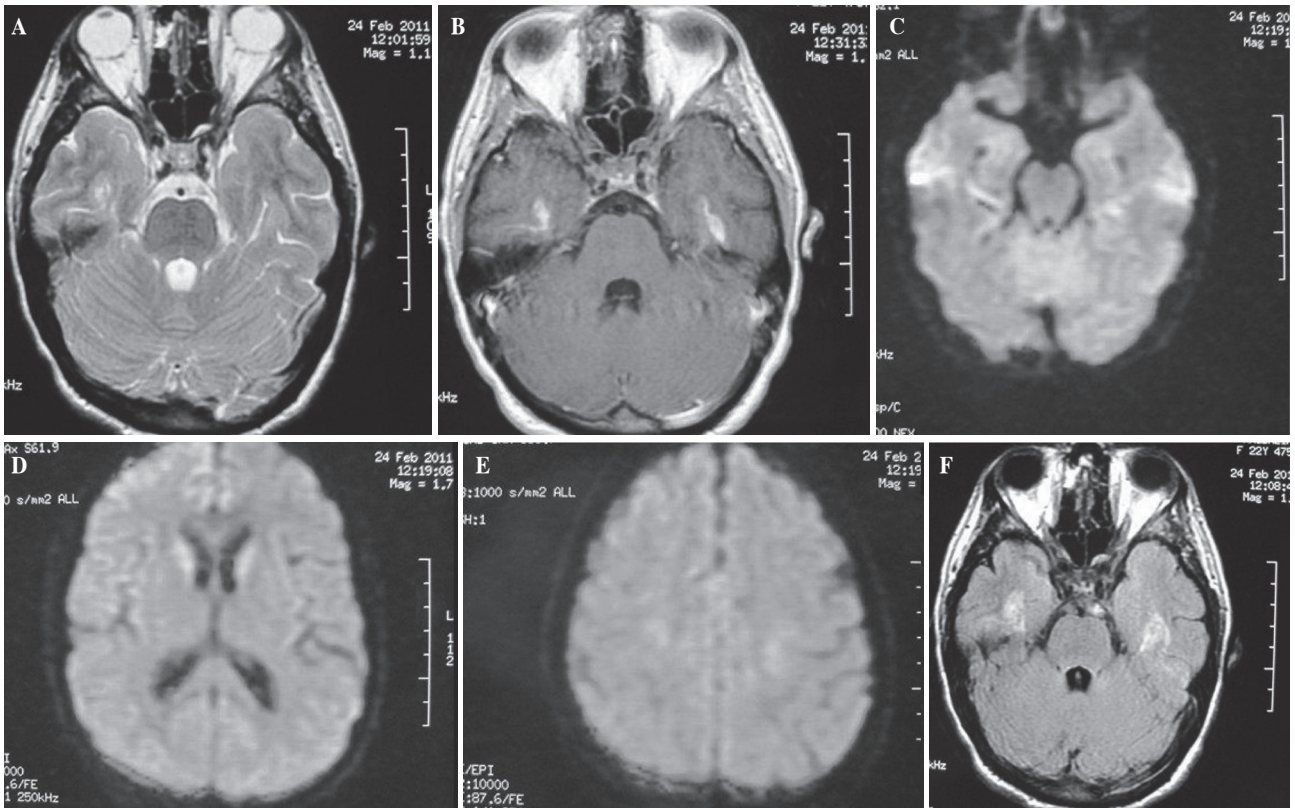


FIGURE 2. MRI findings after 13 days of hospitalization. (A) Axial T2-weighted MR image and (B) FLAIR image : demonstrate 13 days later absence of hyperintensity. (C) Axial DWI shows not restricted diffusion in the temporal lobes and right occipital lobe, (D) in the right occipital lobe and splenium and (E) in the centrum semiovale. (F) Contrast-enhanced axial T1W image demonstrates a reduction of the enhancement in the temporal lobes.

rather than a genetic predisposition to the manifestation of the disease⁵.

Thorough investigation revealed severe changes in the white matter, termed vacuolating myelinopathy, lesions that are characterized by the formation of vacuoles in the oligodendroglia, resulting in a spongiform degeneration⁶. Mitochondrial dysfunction may be critical as well in the development of heroin leukoencephalopathy, as suggested by mitochondrial changes on specimens from brain biopsies. Magnetic resonance spectroscopy may show abnormally elevated intracerebral lactate in the affected white matter as well as decreased levels of NAA in the white matter, gray matter and cerebellum, postulating that these findings reflect mitochondrial toxicity while Proton MR spectroscopy is not essential in the diagnosis but may help in elucidating the nature of the condition^{7,8}.

Clinical improvement after administering antioxidant therapy such as coenzyme Q and vitamin supplements may be beneficial as seen with our patient and reported in a few other cases⁷.

Gupta et al. reported a case of heroin vapour abuse manifested by altered sensorium and rhabdomyolysis-related

renal failure with symmetrical involvement of cerebellar hemispheres and hippocampi initially and delayed involvement of basal ganglia⁹.

There are also similarities to other toxic leukoencephalopathies with widespread white matter hyperdensity involving both supra and infratentorial compartments, with characteristic symmetrical involvement of the posterior limb of the internal capsules and the cerebellar white matter. The subcortical U-fibers seem to be spared. The frontal region may be relatively spared as well while affected areas show diffusion restriction. Since most part of the available literature so far has been selectively published in neurology and radiology journals in the form of clinical case reports, those isolated cases make it difficult to determine possible risk factors for this condition in biochemical and molecular level⁵.

CONCLUSION

Whilst the presented form of leukoencephalopathy seems to be clearly a drug abuse induced disease, we also decided

to record our case in order underline the lack of literature references concerning an entity which, taking for granted the economical and social changes in modern societies and the drug use tendencies, may present a greater prevalence among the general population affecting mostly young drug users of poor incomes unable to obtain pure forms of heroin. The understanding of the exact causes may help in the development of a precise early diagnostic tool and initiating an effective and evidence based treatment. MRI is the imaging modality which allows the diagnosis of toxic leukoencephalopathy, determines the extent of the pathology and assesses the effect of treatment during follow up exams.

REFERENCES

1. Huizer H. Analytical studies on illicit heroin. V. Efficacy of volatilization during heroin smoking. *Pharm Weekbl Sci* 1987; 9:203-211.
2. Offiah C, Hall E. Heroin-induced leukoencephalopathy: characterization using MRI, diffusion-weighted imaging, and MR spectroscopy. *Clin Radiol* 2008; 63:146-152.
3. Wolters EC, van Wijngaarden GK, Stam FC, et al. “Heroin” leukoencephalopathy. *Ned Tijdschr Geneesk* 1982; 126:111-112.
4. Brenneisen R, Hasler F. GC/MS determination of pyrolysis products from diacetylmorphine and adulterants of street heroin samples. *J Forensic Sci* 2002; 47:885-888.
5. Buxton JA, Sebastian R, Klearsky L, et al. Chasing the dragon - characterizing cases of leukoencephalopathy associated with heroin inhalation in British Columbia. *Harm Reduction J* 2011; 8:3.
6. Hill MD. Chasing the dragon - neurological toxicity associated with inhalation of heroin vapour: case report. *CMAJ* 2000; 162:236-238.
7. Kriegstein AR, Shungu DC, Millar WS, et al. Leukoencephalopathy and raised brain lactate from heroin vapor inhalation (“chasing the dragon”). *Neurology* 1999; 53:1765.
8. Kriegstein AR, Shungu DC, Millar WS, et al. Leukoencephalopathy and raised brain lactate from heroin vapor inhalation. *Neurology* 1999; 53:1765-1773.
9. Gupta PK, Krishnan PR, Sudhakar PJ. Hippocampal involvement due to heroin inhalation- “Chasing the Dragon”. *Clin Neurology Neurosurgery* 2009; 111:278-281.
10. Keogh CF, Andrews GT, Spacey SD, et al. Neuroimaging Features of Heroin Inhalation Toxicity: “Chasing the Dragon”. *AJR* 2003; 180:847-850.