

## CASE REPORT

# Pulmonary Hypertension Due to Chronic Thromboembolic Disease Complicated with Hemoptysis and Infection

<sup>1</sup>First Department of Critical Care Medicine & Pulmonary Services, Medical School of Athens University, Athens, Greece

<sup>2</sup>Fifth Department of Internal Medicine and Infectious Diseases Unit, Evagelimos Hospital, Athens, Greece

Andreas Asimakos, MD,<sup>1</sup> Hector Anninos, MD,<sup>1</sup>  
Vasileios Papastamopoulos, MD,<sup>2</sup> Spyros Mentzelopoulos, MD, PhD,<sup>1</sup>  
Spyros Zakyntinos MD, PhD<sup>1</sup>

## ABSTRACT

**KEY WORDS:** *pulmonary hypertension; pulmonary embolism; chronic thromboembolic pulmonary hypertension; hemoptysis; catheter related blood stream infection; fever.*

## ABBREVIATIONS:

CRBSI = catheter related blood stream infection;

CT = computer tomography;

CTEPH = chronic thromboembolic pulmonary hypertension;

CVC = central venous catheter;

FIO<sub>2</sub> = fraction of inspired oxygen;

ICU = intensive care unit;

INR = international normalized ratio;

MERS = Middle East respiratory syndrome;

PAH = pulmonary arterial hypertension;

PAP = pulmonary artery pressure;

SARS = severe acute respiratory syndrome;

SpO<sub>2</sub> = arterial oxygen saturation;

V/Q scan = ventilation/perfusion scan;

WHO-FC = World Health Organization functional class

## Correspondence to:

Andreas Asimakos, MD, Evagelimos Hospital, Athens, Greece;

Tel.: +30-6974-889429;

E-mail: silverakos@gmail.com

Manuscript received January 21, 2015;

Revised manuscript received March 11, 2015;

Accepted March 27, 2015

A 45-year-old woman developed exertional dyspnea after surgical removal of uterine fibroids. Cardiac ultrasound showed right ventricular dilation and dysfunction due to pulmonary arterial hypertension, whereas subsequent computed tomography (CT) angiography revealed pulmonary embolism. Anticoagulant therapy was initiated. Perfusion defects were noticeable in lung perfusion scan 6 months after the initiation of anticoagulant therapy, while CT angiography was negative for pulmonary embolism. The diagnosis of chronic thromboembolic pulmonary hypertension was initially entertained and subsequently confirmed by right heart catheterization. Deterioration of dyspnea and right ventricular dysfunction led to administration of intravenous epoprostenol through an indwelling central venous catheter. After 6 months, the patient was admitted to the intensive care unit with fever, hemoptysis, lung infiltrates, and acute-on-chronic hypoxemic respiratory failure. Bronchial artery embolization, oxygen therapy, and antibiotics led to clinical improvement.

## INTRODUCTION

According to the latest clinical classification, chronic thromboembolic pulmonary hypertension (CTEPH) belongs to group 4 of pulmonary hypertension.<sup>1,2</sup> The hemodynamic classification places CTEPH in the pre-capillary pulmonary hypertension group.<sup>1</sup> A clinical event of pulmonary embolism is not compulsory and nearly half the patients with CTEPH do not report one.<sup>3</sup> CTEPH may progress regardless of antithrombotic therapy since a vascular remodeling cascade is initiated after a thrombotic insult.<sup>1</sup> Ventilation/perfusion scan (V/Q scan) provides the highest sensitivity and specificity and is indispensable in the diagnostic algorithm of pulmonary hypertension to safely exclude or confirm CTPEH.<sup>1</sup> Therapy may comprise agents used to treat primary or idiopathic pulmonary arterial hypertension. Intravenous vasodilator agents are reserved for patients with advanced functional incapacity<sup>1</sup> and their administration through central venous catheters increases the risk of bloodstream infections.<sup>4</sup> Another potentially lethal complication is hemoptysis, with bronchial artery embolization being an effective and safe treatment.<sup>5,6</sup>

Conflict of Interest: none declared

CASE REPORT

A 45-year-old woman developed exertional dyspnea after surgical removal of uterine fibroids. Her past medical history included splenectomy at the age of 2 years due to leishmaniasis, heterozygous beta-thalassemia, and active smoking of 30 pack-years. She was mother to two healthy children. Cardiac ultrasound revealed right ventricular enlargement and dysfunction compatible with the presence of pulmonary arterial hypertension. Computer tomography (CT) angiography was positive for pulmonary embolism (Fig. 1) and anticoagulant therapy was initiated.

Six months after the initiation of anticoagulant therapy with a vitamin K antagonist and while the international normalized ratio (INR) was in the therapeutic range (2-3),<sup>1</sup> patient's exertional dyspnea substantially increased. Follow-up echocardiography showed that the systolic function of the right ventricle had deteriorated and the pressure in the pulmonary artery was further increased. Patient was suffering from respiratory failure and supplemental oxygen was administered.

CT angiography was negative for pulmonary embolism, and the lung perfusion scan revealed multiple perfusion defects (Fig. 2). The diagnosis of pulmonary arterial hypertension due to CTEPH was initially entertained. Patient was started on diuretics (furosemide), digoxin, and an endothelin-antagonist (bosentan).

In order to further confirm the diagnosis of CTEPH, and because the patient's functional status continued to deteriorate despite treatment, right heart catheterization was performed. Measurements revealed pre-capillary pulmonary hypertension, with a mean pulmonary artery pressure (PAP) of 65 mmHg. The vasoreactivity test performed with intravenous administration of epoprostenol showed a positive response,<sup>1</sup> with a mean PAP reduction >10 mmHg reaching a value of 40 mmHg without decreasing cardiac output (Table 1). The

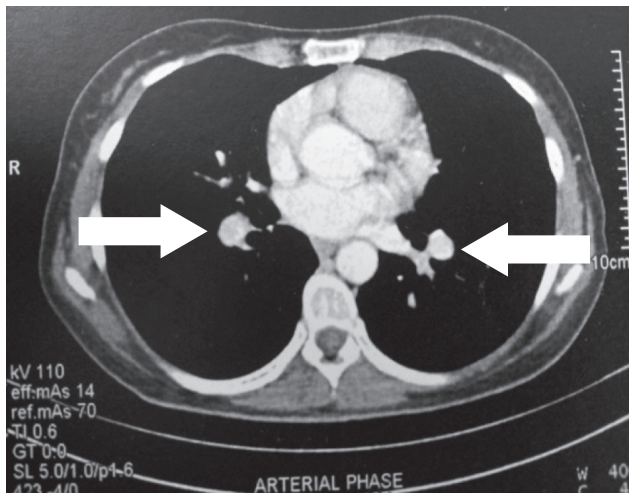


FIGURE 1. Computed tomography pulmonary angiography shows bilateral pulmonary emboli (arrows).

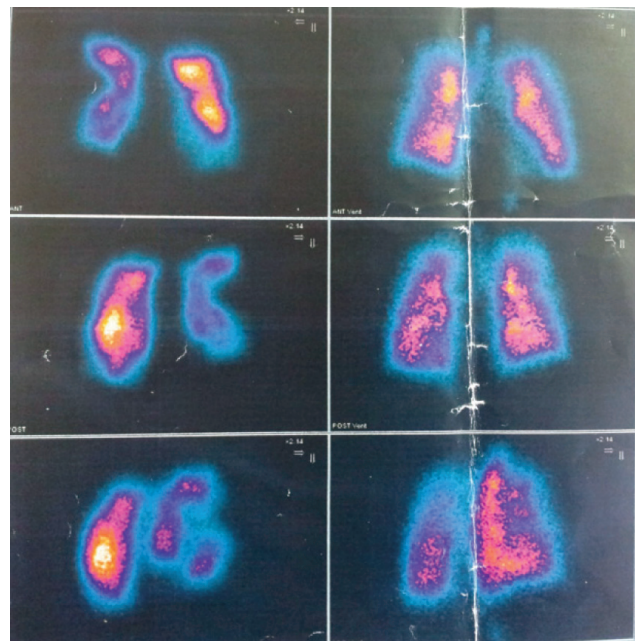


FIGURE 2. Lung perfusion scan with multiple perfusion defects. CT pulmonary angiography performed at the same time was negative for pulmonary embolism.

TABLE 1. Right heart catheterization measurements

Hemodynamic parameters	Obtained values	Normal values <sup>8</sup>	Values obtained after the vasoreactivity test
Systolic pulmonary artery pressure (mmHg)	109	<30	60
Diastolic pulmonary artery pressure (mmHg)	40	<12	20
Mean pulmonary artery pressure (mmHg)	65	<20	40
Pulmonary capillary wedge pressure (mmHg)	8	2-15	8
Pulmonary vascular resistance (Wood units)	16	<2	7.4
Cardiac index (L/min/m <sup>2</sup> )	2.2	2.5 – 4.0	2.7

patient was unable to carry out her daily activities and started feeling breathless at rest. She was classified as functional class 4 according to World Health Organization functional classification (WHO-FC),<sup>7</sup> and administration of intravenous epoprostenol through an indwelling central venous catheter (Hickman) was started.

At 6 months later, the patient was admitted to the intensive care unit (ICU) due to severe acute-on-chronic hypoxemic respiratory failure and high fever. Laboratory findings were remarkable for an elevated C-reactive protein (5.1 mg/dl; normal values <0.3 mg/dl) and white blood cell count (17,000/ $\mu$ L; 80% neutrophils). Arterial blood gas examination showed hypoxemia (pO<sub>2</sub> 58 mmHg, pCO<sub>2</sub> 28 mmHg, pH 7.51, HCO<sub>3</sub> 26 mmol/L, O<sub>2</sub> saturation 91%), while the patient was receiving 100% fraction of inspired oxygen (FIO<sub>2</sub>) administered via a full-face reservoir oxygen mask. Patient's fever pattern was characterized by two febrile waves per day for the preceding 8 days. Chest CT revealed multiple lung infiltrates (Fig. 3).

Seven days after ICU admission, repeated episodes of hemoptysis led to clinical deterioration and anticoagulation therapy had to be suspended. Multi-resistant *Klebsiella pneumoniae*, sensitive only to gentamycin, tigecycline and the combination of meropenem and colimycin, was isolated from a blood culture that was drawn through the Hickman catheter. The blood culture from a peripheral vein that was taken simultaneously was negative and the catheter entry site had no indication of skin inflammation. A coronavirus was detected in patient's sputum with polymerase chain reaction. Repeated sets of blood cultures drawn from the Hickman catheter and periphery were also negative and no other pathogen was detected from sputum, urine and blood through cultures and

molecular techniques. Transthoracic echocardiogram was negative for endocarditis and confirmed right ventricular dilation and dysfunction, and severe pulmonary hypertension. Transesophageal echocardiography could not be performed due to patient's respiratory status with marginal blood oxygenation (O<sub>2</sub> saturation 93%) despite administration of 100% oxygen. The left internal jugular vein, where the Hickman catheter was placed, was free of thrombus.

A second central venous catheter was placed via the right internal jugular vein for epoprostenol administration and the Hickman catheter was locked with a concentrated mixture of gentamycin and heparin that was renewed every 48 hours for 7 days. Systemic antibiotics were also administered. Notably, patient's hemodynamic status was rather stable, and no inotropic drug infusion (dobutamine or noradrenaline) was required. Hemoptysis was successfully treated with embolization of a hypertrophic supernumerary bronchial artery (Fig. 4), and anticoagulation was promptly reinitiated. Respiratory failure progressively improved, fever subsided, and lung infiltrates gradually resolved. The Hickman catheter was again used for the continuous administration of epoprostenol, and the right internal jugular venous catheter was removed. The patient was discharged after a 30-day stay in the ICU, afebrile, with continuous oxygen administration through a nasal cannula (~2 L/minute). Arterial blood gas examination reveal a pO<sub>2</sub> of 65 mmHg, a pCO<sub>2</sub> of 33 mmHg, a pH of 7.47, and a bicarbonate level of 25 mmol/L. The patient was subsequently referred to a specialized center to be evaluated for lung transplantation.

DISCUSSION

Chronic thromboembolic pulmonary hypertension (CTEPH) accounts for less than 1% of all cases of pulmonary hypertension, while left heart disease accounts for the majority

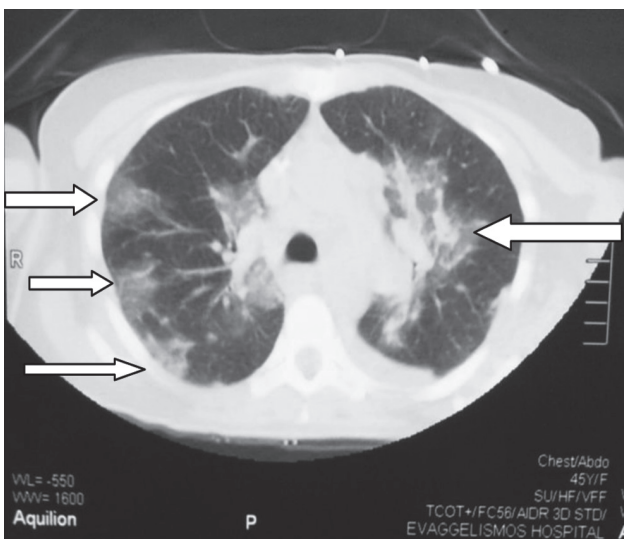


FIGURE 3. CT of the chest showing multiple ground glass infiltrates (arrows).

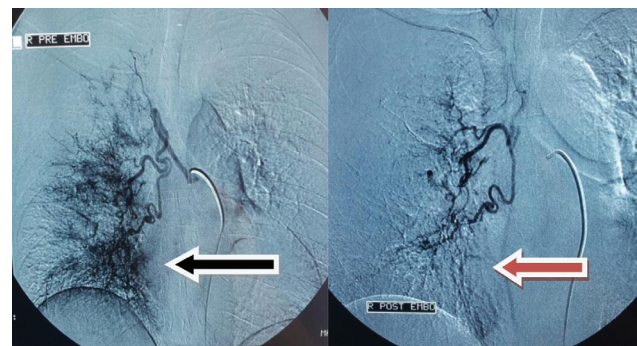


FIGURE 4. Embolization of a hypertrophic supernumerary right bronchial artery that was considered the origin of hemoptysis (the arrow on the left indicates the picture before and the arrow on the right the image after embolization).

of these cases, around 80%.<sup>9</sup> CTEPH may complicate up to 3.8% of acute pulmonary embolic events,<sup>10</sup> yet most experts believe this rather occurs at lower rates (0.5-2%).<sup>1</sup> Certain medical conditions are associated with an increased risk of CTEPH, including myeloproliferative disorders, chronic inflammatory bowel disease, and previous splenectomy.<sup>11</sup> Our patient had undergone splenectomy when she was 2 years-old.

Persistent pulmonary artery hypertension and/or right ventricular dysfunction following pulmonary embolism should raise the suspicion for CTEPH. Additionally, the differential diagnosis of “unexplained” pulmonary hypertension should definitely include CTEPH.<sup>1</sup> Ventilation/perfusion (V/Q) scan remains the cornerstone for the diagnosis of CTEPH. Despite the technological advances in CT imaging, V/Q scan yields higher specificity and sensitivity.<sup>1</sup> Indeed, our patient was suffering from CTEPH, but the follow-up CT angiography was negative for pulmonary embolism, whereas the lung perfusion scan revealed unmatched perfusion defects (Figure 2). A normal or low probability V/Q scan may safely exclude CTEPH.<sup>1</sup> Nevertheless, right heart catheterization is required to establish the diagnosis of CTEPH by the presence of precapillary pulmonary hypertension (mean PAP >25 mmHg) in conjunction with unmatched perfusion defects or organized thrombi attached to the pulmonary artery.<sup>1</sup>

The pathobiology of CTEPH is not fully elucidated; however, the mechanical obstructions by persistent embolic masses that adhere to the pulmonary vascular bed in conjunction with abnormalities in the coagulation cascade play a pivotal role.<sup>1</sup> Thrombus formation in the pulmonary vascular bed and the subsequent rise in pulmonary arterial pressure may trigger vascular remodeling leading to a self-sustained pulmonary hypertension without further provision of thrombotic material.<sup>12,13</sup> Vessel changes are not confined to pulmonary arteries. Indeed, bronchial artery hypertrophy is reported in nearly half the patients with pulmonary artery hypertension (PAH) (44%)<sup>14</sup> and in the majority of patients with CTEPH (73%).<sup>15</sup> Bronchial artery hypertrophy is linked to hemoptysis and is highly prevalent in patients with CTEPH.<sup>5</sup> In our case, embolization of a hypertrophic supernumerary bronchial artery (Figure 4) safely controlled hemoptysis and obviated intubation, which was otherwise imminent, as our patient suffered from severe hypoxemia. Bronchial artery embolization is reported as the treatment of choice for patients with hemoptysis on the ground of pulmonary hypertension.<sup>5,6</sup>

Lifelong anticoagulant therapy may be necessary, albeit not adequate, for all patients with CTEPH.<sup>1</sup> Supportive therapy for PAH that may also be administered to patients with CTEPH includes diuretics, oxygen therapy, and digoxin (especially in patients with tachyarrhythmias).<sup>1</sup> Surgery may help patients with proximal organized thrombi; however, proper selection of patients, surgical technique, and post-operative management in an experienced center dictates outcome.<sup>16</sup> However, our patient did not have proximal

organized thrombi, and thus she was rather not eligible for pulmonary endarterectomy.

According to the latest guidelines, specific drugs used in pulmonary artery hypertension may also be administered to patients with CTEPH who are inoperable, or before surgery in order to achieve clinical and hemodynamic improvement, or after surgery in patients who relapse.<sup>1</sup> Our patient was receiving intravenous epoprostenol due to inoperable CTEPH and a WHO functional class 4.<sup>7</sup> Epoprostenol is a synthetic prostacyclin analogue that is reserved for patients with primary pulmonary hypertension in advanced stages (WHO functional class 3 and 4), and may be given in addition to other specific medications in WHO class 4 when an inadequate clinical response is encountered.<sup>1</sup> Bosentan is an endothelin antagonist that proved to safely decrease pulmonary vascular resistance in inoperable patients with CTEPH.<sup>17</sup> Nonetheless, patients who continue to deteriorate despite treatment and are not suited for pulmonary endarterectomy should be evaluated in specialized centers for bilateral lung transplant.<sup>1</sup> Our patient was rather eligible for lung transplant and was referred to a specialized center for evaluation of lung transplantation.

Indwelling central venous catheters are frequently colonized with bacteria.<sup>18</sup> Indeed, in a study where the microbiological management of tunneled central venous catheters was investigated, about 1 out of 4 (26.2%) catheters was colonized with bacteria but less than 1 out of 10 (7.4%) was responsible for catheter related blood stream infection (CRBSI).<sup>18</sup> Patients receiving continuous intravenous therapy for PAH are at risk of catheter related sepsis, as was shown in the early studies that proved epoprostenol's efficacy and safety.<sup>4</sup> According to the latest guidelines, a definitive diagnosis of CRBSI requires the isolation of the same organism from blood drawn from the catheter hub and from a peripheral vein through percutaneous puncture.<sup>19</sup> A threefold greater colony count from catheter blood is required when quantitative blood cultures are available, while in semi-quantitative blood cultures, microorganisms in catheter blood should grow at least 2 hours before peripheral blood sample.<sup>19</sup> Central catheters should be removed if there are indications of severe sepsis, suppurative thrombophlebitis, endocarditis, or bloodstream infection persists for 72 hours after treatment.<sup>19</sup> Tunneled central venous catheters should also be removed if there are indications of tunnel infection.<sup>19</sup> Accordingly, we decided not to remove the Hickman catheter since a definite CRBSI could not be established, catheter tunnel and entry site had no pathology, patient was hemodynamically stable, and endocarditis or thrombophlebitis could not be detected. However, persistent fever, bilateral lung infiltrates and severe hypoxemia led us to administer broad spectrum antibiotics also effective against the multi-resistant strain of *Klebsiella pneumoniae* cultured from blood drawn from the Hickman catheter. Probably it was an overtreatment, but it is well known that in CTEPH, complications such as CRBSI or sepsis may lead to unfavorable outcome and must be promptly

treated in fine balance to an overwhelmed cardiopulmonary system.<sup>4,19</sup> Antibiotic lock was decided in an attempt to salvage the possibly colonized Hickman catheter, according to latest guidelines.<sup>19</sup>

Coronaviruses are common viruses that cause mild to moderate upper respiratory tract infection and most people are infected at least once in their life time. A viral cause was established in 366 out of 1029 patients (35.6%) with chronic underlying (predominantly pulmonary) conditions hospitalized for acute respiratory disease.<sup>20</sup> The association of coronavirus infection and severe respiratory complications (including pneumonia) in adults with underlying cardiopulmonary disease is also established.<sup>21</sup> Accordingly, we considered the isolated coronavirus to be the cause of the multiple infiltrates and worsening respiratory failure of our patient. To our knowledge there is no special therapy for coronavirus pneumonia<sup>22</sup> and supportive measures were applied.

## REFERENCES

- Galiè N, Hoeper MM, Humbert M, et al. Guidelines for the diagnosis and treatment of pulmonary hypertension: the Task Force for the Diagnosis and Treatment of Pulmonary Hypertension of the European Society of Cardiology (ESC) and the European Respiratory Society (ERS), endorsed by the International Society of Heart and Lung Transplantation (ISHLT). *Eur Heart J* 2009;30:2493-2537.
- Simonneau G, Gatzoulis MA, Adatia I, et al. Updated clinical classification of pulmonary hypertension. *J Am Coll Cardiol* 2013;62:D34-41.
- Hoeper MM, Mayer E, Simonneau G, Rubin LJ. Chronic thromboembolic pulmonary hypertension. *Circulation* 2006; 113:2011-2020.
- Barst RJ, Rubin LJ, Long WA, et al; Primary Pulmonary Hypertension Study Group. A comparison of continuous intravenous epoprostenol (prostacyclin) with conventional therapy for primary pulmonary hypertension. *N Engl J Med* 1996;334:296-301.
- Reesink HJ, van Delden OM, Kloek JJ, Jansen HM, Reekers JA, Bresser P. Embolization for hemoptysis in chronic thromboembolic pulmonary hypertension: report of two cases and a review of the literature. *Cardiovasc Intervent Radiol* 2007; 30:136-139.
- Cantu JA, Safdar Z. Hemoptysis requiring bronchial artery embolization in pulmonary arterial hypertension. *South Med J* 2010;103:887-891.
- Barst RJ, McGoon M, Torbicki A, et al. Diagnosis and differential assessment of pulmonary arterial hypertension. *J Am Coll Cardiol* 2004;43:S40-S47.
- Zipes DP, Libby P, Bonow RO. Braunwald's heart disease: A textbook of cardiovascular medicine. 7th ed. Philadelphia: Elsevier Saunders; 2005.
- Gabbay E, Yeow W, Playford D. Pulmonary arterial hypertension (PAH) is an uncommon cause of pulmonary hypertension (PH) in an unselected population: the Armadale echocardiography study. *Am J Resp Crit Care Med* 2007;175:A713.
- Pengo V, Lensing AW, Prins MH, et al. Incidence of chronic thromboembolic pulmonary hypertension after pulmonary embolism. *N Engl J Med* 2004; 350:2257-2264.
- Bonderman D, Wilkens H, Wakounig S, et al. Risk factors for chronic thromboembolic pulmonary hypertension. *Eur Respir J* 2009;33:325-331.
- Rubin LJ, Hoeper MM, Klepetko W, et al. Current and future management of chronic thromboembolic pulmonary hypertension: from diagnosis to treatment responses. *Proc Am Thorac Soc* 2006;3:601-607.
- Galiè N, Kim NH. Pulmonary microvascular disease in chronic thromboembolic pulmonary hypertension. *Proc Am Thorac Soc* 2006;3:571-576.
- Tio D, Leter E, Boerrigter B, et al. Risk factors for hemoptysis in idiopathic and hereditary pulmonary arterial hypertension. *PLoS One* 2013;8(10):e78132.
- Remy-Jardin M, Duhamel A, Deken V, Bouaziz N, Dumont P, Remy J. Systemic collateral supply in patients with chronic thromboembolic and primary pulmonary hypertension: assessment with multi-detector row helical CT angiography. *Radiology* 2005;235:274-281.
- Dartevelle P, Fadel E, Mussot S, et al. Chronic thromboembolic pulmonary hypertension. *Eur Respir J* 2004;23:637-648.
- Jais X, D'Armini AM, Jansa P, et al. Bosentan for treatment of inoperable chronic thromboembolic pulmonary hypertension: BENEFIT (Bosentan Effects in iNoperable Forms of chronic Thromboembolic pulmonary hypertension), a randomized, placebo controlled trial. *J Am Coll Cardiol* 2008;52:2127-2134.
- Guembe M, Martín-Rabadán P, Echenagusia A, et al. How should long-term tunneled central venous catheters be managed in microbiology laboratories in order to provide an accurate diagnosis of colonization? *J Clin Microbiol* 2012;50:1003-1007.
- Mermel LA, Allon M, Bouza E, et al. Clinical practice guidelines for the diagnosis and management of intravascular catheter-related infection: 2009 Update by the Infectious Diseases Society of America. *Clin Infect Dis* 2009;49:1-45.
- Glezen WP, Greenberg SB, Atmar RL, Piedra PA, Couch RB. Impact of respiratory virus infections on persons with chronic underlying conditions. *JAMA* 2000;283:499-505.
- El-Sahly HM, Atmar RL, Glezen WP, Greenberg SB. Spectrum of clinical illness in hospitalized patients with "common cold" virus infections. *Clin Infect Dis* 2000;31:96-100.
- Pene F, Merlat A, Vabret A, et al. Coronavirus 229E-related pneumonia in immunocompromised patients. *Clin Infect Dis* 2003;37:929-932.