

IMAGES IN MEDICINE

Bifocal Right Ventricular Pacing: Alternative to Biventricular Pacing for Cardiac Resynchronization Therapy?

Antonis S. Manolis, MD, Sofia Metaxa, MD, Nikolaos Sakellaris, MD

Department of Cardiology,
Evangelismos Hospital, Athens, Greece

KEY WORDS: heart failure; cardiac
resynchronization therapy; biventricular
pacing; bifocal right ventricular pacing

A 59-year-old patient with dilated cardiomyopathy, severe systolic left ventricular dysfunction and drug-refractory advanced heart failure (New York Heart Association-NYHA class III-IV symptoms) and prior history of mitral valve replacement was scheduled for implantation of a biventricular pacing system (cardiac resynchronization therapy-defibrillator or CRT-D device). The coronary sinus was cannulated after some effort and a venous coronary angiogram was performed (**Panel A**). Although a posterolateral cardiac venous branch (**Panel A, arrow**) was identified to accommodate the left ventricular pacing lead, placement of the lead in this tributary (**Panel B**) was accompanied by phrenic nerve stimulation, which could not be remedied by moving to more proximal positions where the lead could not be stabilized. Having no other

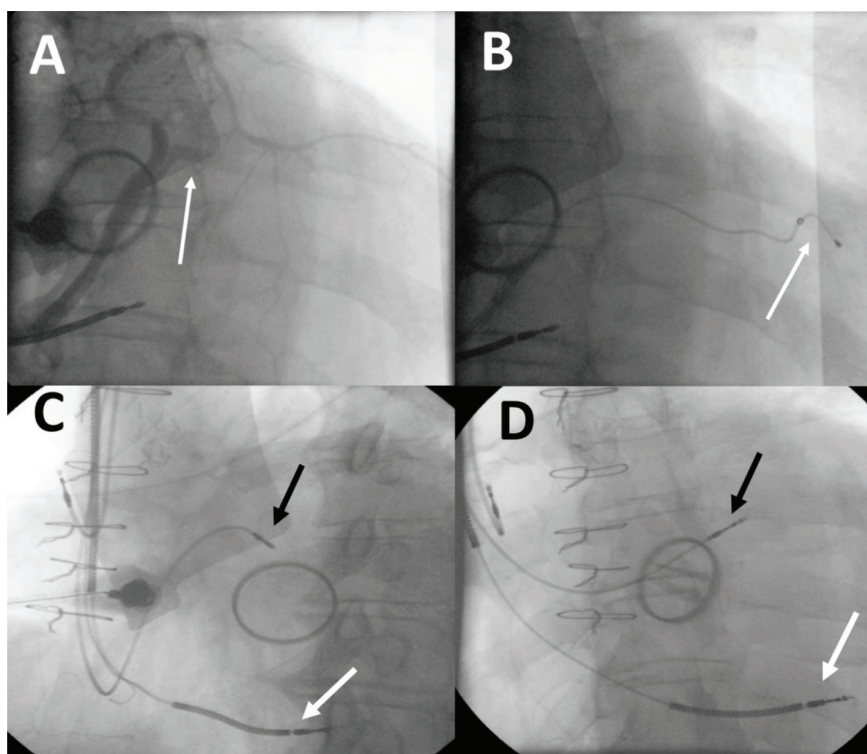
ABBREVIATIONS

CRT = cardiac resynchronization therapy;
CRT-D = CRT defibrillator;
CRT-P = CRT-pacemaker;
ICD = implantable cardioverter
defibrillator;
LBBB = left bundle branch block;
NYHA = New York Heart Association

Correspondence to:
Antonis Manolis, MD,
Department of Cardiology,
Evangelismos Hospital,
Athens, Greece;
E-mail: asm@otenet.gr

Manuscript received September 20,
2014; Revised manuscript received and
accepted September 29, 2014

Conflict of Interest: none declared



option except for sending the patient to surgery for epicardial lead placement, albeit a most difficult and high-risk procedure due to prior history of cardiac surgery, we attempted bifocal right ventricular pacing by placing the composite pacing-defibrillating lead at a low septal position (**Panels C and D, white arrow**) and an active fixation bipolar pacing lead at a very high right ventricular outflow tract position (**Panels C and D, black arrow**). The procedure was otherwise uncomplicated and the patient's post-procedural course remained uneventful. The patient had a good clinical response to this type of bifocal right ventricular pacing over the subsequent days and months with amelioration of his dyspneic symptoms and improvement of his quality of life. At the three-year follow-up he remains in NYHA class II category.



In patients with heart failure of New York Heart Association (NYHA) functional class II, III and ambulatory IV and a wide QRS (>120-130 ms), mainly in the form of left bundle branch block (LBBB), in sinus rhythm, cardiac resynchronization therapy (CRT) has proven most beneficial over the last 20 years.^{1,2} CRT is effected via biventricular pacing by placing a right ventricular lead, either at the right ventricular apex or the septum and the left ventricular lead via the coronary sinus into a lateral or posterolateral coronary vein tributary.¹ The procedure may be technically challenging, mostly due to difficulties in cannulating the coronary sinus and also finding a suitable coronary vein branch, but this can be attained in >90% of the cases.^{1,2} The device that resynchronizes the left ventricle may be a biventricular pacemaker device (CRT-P device) or in the majority of cases a biventricular implantable cardioverter defibrillator (ICD) device also providing additional protection from sudden cardiac death in this heart failure patient population (CRT-D device). CRT offers significant symptomatic benefit and improvement of quality of life to these patients, but most importantly it confers a significant survival benefit by prolonging life by 20-40% in this group of patients with most benefit observed in patients with true LBBB and a QRS duration >150 ms.^{1,2}

However, apart from reaching the right target vein, obtaining an adequate pacing threshold and avoiding phrenic nerve stimulation while placing the left ventricular lead is an additional challenge for applying this electrical therapy. In the present case, placement of the left ventricular lead was hampered by phrenic nerve stimulation when placed distally at the posterolateral branch, while at more proximal positions it was impossible to stabilize the lead. In such cases alternate lead positions are sought and when not available, as in this case, one may resort to a surgical approach for epicardial placement of the left ventricular lead, though with its attendant surgical risks and observed problematic chronic pacing thresholds. However, this was not an easy decision and option for this patient who

had prior cardiac surgery and the surgical approach would be difficult owing to the presence of pericardial adhesions and scarring. Thus, an alternative approach was chosen that of bifocal right ventricular pacing at two right ventricular sites at some distance from each other (Panels C and D). This particular approach worked well for this patient, but it is nevertheless considered inferior to true biventricular pacing.

Bifocal right ventricular pacing has been used as an alternative approach for CRT in patients with unsuccessful left ventricular lead implantation.³⁻⁹ Favorable results of resynchronization have been obtained with this approach, but the number of patients included in these reports is small (case reports or case series)^{3,4} and there have been no randomized studies comparing these two approaches. Acute hemodynamic studies have reported that bifocal pacing improves left ventricular hemodynamics, by decreasing the inter- and intraventricular conduction delays, and they have pointed out that the leads in the right ventricle should be placed at the longest achievable distance.⁵ They also indicated that biventricular pacing appears superior to bifocal pacing.^{5,6}

There was one randomized trial, the BRIGHT study, which though compared bifocal pacing to control (inactive) mode (ventricular inhibited back up pacing at 40 bpm) in 42 patients.⁷ The study showed a clinical benefit of bifocal pacing over the study period of 3 months. In a prospective non-randomized comparison of the two techniques, bifocal vs biventricular pacing, in 36 heart failure patients, the authors reported favorable results of resynchronization obtained with both techniques, with no significant differences between the two groups, except for more QRS narrowing in the biventricular group, and a trend for a lower number of hospital admissions in the biventricular group.⁸ However, when the groups were analyzed separately and compared before and after the procedures, improvement was much more significant in the biventricular group.⁸ Thus, biventricular pacing should be the first line therapy for patients in need for CRT, but in difficult cases, such as the one presented herein, bifocal right ventricular pacing may be a viable alternative.⁹

REFERENCES

1. Manolis AS. Cardiac resynchronization therapy in congestive heart failure; ready for prime time? *Heart Rhythm* 2004; 1:355-363.
2. Leyva F, Nisam S, Auricchio A. 20 years of cardiac resynchronization therapy. *J Am Coll Cardiol* 2014;64:1047-1058.
3. O'Donnell D, Nadurata V, Hamer A, Kertes P, Mohammed W. Bifocal right ventricular cardiac resynchronization therapies in patients with unsuccessful percutaneous lateral left ventricular venous access. *Pacing Clin Electrophysiol* 2005; 28:S27-S30.
4. Chudzik M, Piestrzeniewicz K, Klimczak A, et al. Bifocal pacing in the right ventricle: An alternative to resynchronization when left ventricular access is not possible in end-stage heart failure

patients. *Cardiol J* 2010;17:35–41.

5. Bulava A, Lukl J. Usefulness of bifocal pacing in patients with heart failure and intraventricular conduction delay. *Eur J Heart Fail* 2007;9:300-305.
6. Lane RE, Mayet J, Peters NS, Davies DW, Chow AW. Comparison of temporary bifocal right ventricular pacing and biventricular pacing for heart failure: evaluation by tissue Doppler imaging. *Heart* 2008;94:53-58.
7. Res JC, Bokern MJ, de Cock CC, van Loenhout T, Bronzwaer PN, Spierenburg HA; BRIGHT Investigators. The BRIGHT study: bifocal right ventricular resynchronization therapy: a randomized study. *Europace* 2007;9:857-861.
8. Rocha EA, Gondim TP, Abreu S, et al. Ventricular resynchronization: comparing biventricular and bifocal right ventricular pacemakers. *Arq Bras Cardiol* 2007;88:674-682.
9. Barold SS, Audoglio R, Ravazzi PA, Diotallevi P. Is bifocal right ventricular pacing a viable form of cardiac resynchronization? *Pacing Clin Electrophysiol* 2008;31:789-794.