

**CARDIOLOGY UPDATE 2006**

## Use and Abuse of Coronary Stenting

Bernhard Meier, MD

*Swiss Cardiovascular Center Bern,  
University Hospital Bern, Bern,  
Switzerland*

**KEY WORDS:** *Coronary angioplasty;  
coronary stenting; drug eluting stents*

---

### ABSTRACT

---

The introduction of the coronary stent in 1986 remains the only real asset to balloon angioplasty introduced about 10 years earlier. Unfortunately, the undeniable advantages of stenting in terms of preventing abrupt closure and reducing restenosis are not fully exploited. The prognostic benefit to be expected from judicious stenting has been given up by default stenting. Infarctions and lives saved initially by stenting are lost again by stent thrombosis after hospital discharge fraught with a mortality of about 50% by late infarctions. They do not exist after plain balloon angioplasty and are due to stent thrombosis. Because of the comfort benefit that prevails (reduced need for intervention), virtually all interventional cardiologists have subscribed to a policy of 100% stenting and are currently about to adopt active (drug eluting) stents as their default devices for it. Once more, active stents do not confer any prognostic benefit over passive stents but they further reduce restenosis and are appealing to operators and patients. Evidence based medicine condones stenting only in about 50% and active stents in may be 80%. Yet this is ignored for rather irrational reasons.

---

### INTRODUCTION

---

Coronary stents were developed in the early eighties primarily to remedy (bail-out) abrupt vessel closure during coronary angioplasty (PCI). The first stent implantation was performed by Jacques Puel on March 28, 1986 electively in a patient with a restenosis after coronary balloon angioplasty [1]. Although reduction of restenosis had been in the back of the minds of the stent developers [1-4], scaffolding intimal flaps was the primary task [3]. The publication launching widespread clinical use of coronary stents [4], however, already put prevention of restenosis in the forefront. It had turned out that the prevention of elastic recoil by the stent more than compensated for the disadvantage of more intimal proliferation induced by the foreign body implanted upon the lacerated endothelium of the coronary lesion.

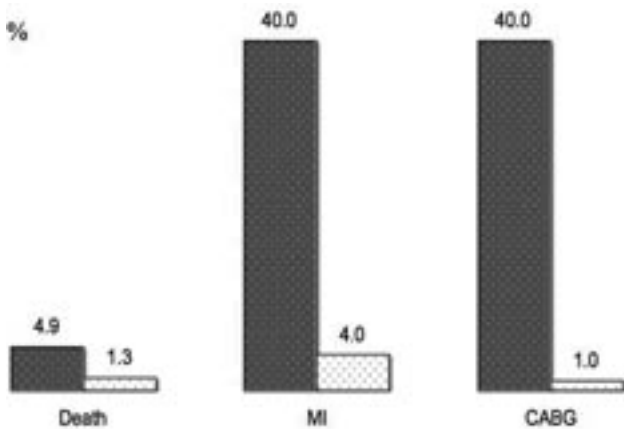
---

### BARE STENTS VERSUS BALLOON ANGIOPLASTY

---

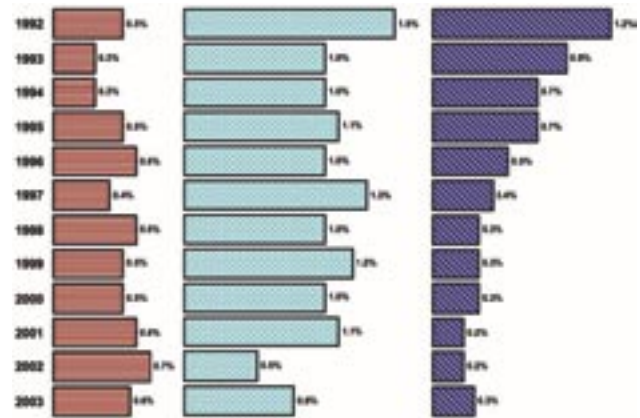
The initial (non-randomized) comparisons between plain balloon angioplasty and bare stents showed a marked safety advantage of the stents (Figure 1) [5,6]. Nonetheless, stenting took off slowly because of a misconception of many an interventional cardiologist. Stenting was initially used almost exclusively for salvaging complications or bad results after balloon angioplasty. This resulted in rather dismal outcomes of the stented patients [7]. One-year-results with a mortality of 8% and 24% stent occlusions were

*Address for correspondence:*  
Bernhard Meier, MD  
Professor and Chairman of Cardiology  
Swiss Cardiovascular Center Bern  
University Hospital Bern  
3010 Bern, Switzerland  
Tel: +41 31 632 30 77  
Fax: +41 31 382 10 69  
E-mail: bernhard.meier@insel.ch



**FIGURE 1.** Non-randomized comparison of complications on 1,801 patients with plain balloon angioplasty of whom 122 (7%) suffered a threatened or accomplished abrupt closure [5] and 4,595 patients of whom 339 (7%) had a threatened or accomplished abrupt closure that was treated with stent implantation [6]. There is a highly significant stent advantage in terms of mortality (death) myocardial infarction (MI), or the need for emergency coronary bypass surgery (CABG) before hospital discharge.

no match for general balloon angioplasty results. Only when randomized trials using stents in one arm in all patients proved a significant advantage of stenting over balloon angioplasty in terms of soft endpoints, such as need for re-intervention [8,9], interventional cardiologists literally jumped on this technique, adopting default stenting within a few years. Nobody seemed to question why there no longer was an advantage in the most important endpoints such as mortality and myocardial infarction [10,11]. All seemed content with the conspicuous reduction in need for emergency coronary bypass surgery and later revascularizations of any kind. After full implementation of routine coronary stenting, a continuous European registry encompassing data of a population over 500 patients showed no decrement in mortality or myocardial infarction (Figure 2) [12]. The stents had certainly helped to reduce the need for emergency coronary artery bypass surgery. However, the trend to resort less often to such a drastic measure had already started before the introduction of coronary stents. Mortality rates of 20%-50% in patients undergoing emergency coronary artery bypass surgery had made clear that this procedure was not beneficial in all angioplasty procedures that ended with a poor local result or even an occluded coronary artery [13]. The lack of impact on prognostic endpoints such as mortality and infarction has to be blamed on the overuse of stents. First, the obsession to put a stent into every lesion leads to additional complications as it prolongs to procedure and imparts additional trauma to the coronary arteries on the way to the lesion to be stented. Second, side branches in jeopardy



**FIGURE 2.** In-hospital mortality (left panel), myocardial infarction (center panel), or need for emergency coronary bypass surgery (right panel) in a comprehensive European registry from 1992-2003 [12]. In spite of full adoption of coronary stenting, only the need for bypass surgery decreased significantly.

actually occluded in 5% in the pre-stent era [14] but in about 20% when stents were generously used [15]. These data did not even account for the new and grave problem that stents introduced, i.e., late thrombotic occlusion of the treated site. Even with bare stents, this problem that has been talked about little before active (drug eluting) stents were introduced was there and occurred in about 2% [16] of cases, while it had been virtually inexistent before stents were available. Hence, the interventional cardiology community appeared to behave rationally by abstaining from expanding their activity in a single session to too many vessels. In fact, figure 3 shows that multivessel angioplasty in a single session did not increase from 1992-2003 [12].

The impression that stenting had made coronary angioplasty more comfortable for both operators (nicer angiographic results, less concern about abrupt closure in the catheterization laboratory or before hospital discharge) and patients (less need for a re-intervention) but not safer (this latter point was usually played down if not blatantly denied) was corroborated by a meta-analysis of randomized trials between balloon angioplasty and coronary stenting using bare (passive) stents [17]. On the basis of the stenting rates used in the balloon arm which varied according to the bravery of the operators from 0% to 60%, this meta-analysis proved that the need for repeat angioplasty could indeed be reduced from 16% to about 5% but the bulk of the effect was already attained at a stenting rate of about 20%. This was based on 29 trials encompassing 9,918 patients and made perfect sense but it was largely ignored by interventional cardiologists. Without even having to analyze such a large host of patients, one could have estimated a similar percentage of stenting yielding virtually the full benefit. Before stenting, 70% of patients neither had an

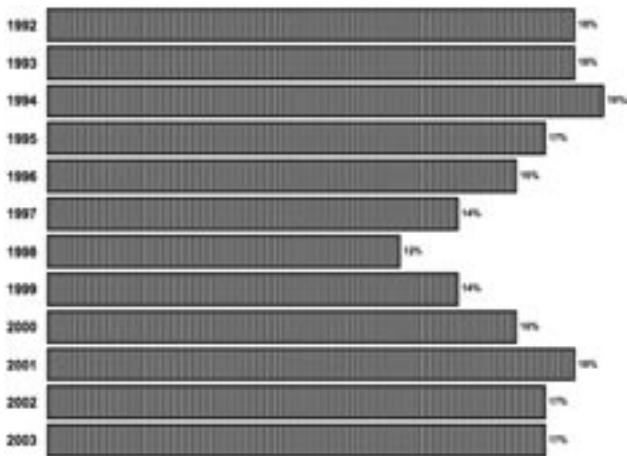


FIGURE 3. Coronary angioplasty to >1 vessel area in a single session in the European registry from 1992-2003 [12]. Against common belief, there was no increase.

acute nor a chronic problem after balloon angioplasty such as a vessel occlusion or restenosis. In these 70%, stenting cannot possibly improve the outcome but it can deteriorate it, e.g., by adding the risk of late stent thrombosis unknown to balloon angioplasty. Assuming that 5% to 10% of these patients would have a problem in spite of being equipped with a stent, the 20% rate found by the meta-analysis [17] is accurately forecast. It is understandable that no interventional cardiologist will operate with a 20% stenting rate as the patients finally benefiting from a stent are difficult to predict. However, it looks amateurish (and is not in the interest of patients overall) to not even try to predict them and insert stents in 100% of patients. A true professional should be able to stent no more than half of his patients and still have the vast majority of those needing a stent among the ones also receiving it. A non-randomized study comparing a stenting rate of 70% by one operator to a stenting rate of 50% by another one in the same interventional group, found no difference in over 300 patients pertaining to in-hospital or 1-year mortality, major adverse cardiac events, or restenosis [18].

Another new feature brought about by stenting was initially ignored. In-stent restenosis occurred less often than restenosis without a stent. However, some of these restenoses were diffuse and much more difficult to treat than a restenosis after plain balloon angioplasty. Hence studies comparing restenosis after balloon angioplasty or stenting should have used a conversion factor counting double each in-stent restenosis (or at least the diffuse ones). Only when a new method to treat that problem (brachytherapy) was introduced, this problem was brought to light. Notwithstanding, brachytherapy never stood a chance to become a routine procedure. One had to irradiate about 10 patients to save 1 from an additional intervention, hardly a bargain considering the wasted money and

time used in the 9 patients who would not have had a further problem with a simple balloon dilatation or had one in spite of brachytherapy. Yet, to bring out the advantages of their technique, protagonists of brachytherapy emphasized the intricacy of in-stent restenosis.

ACTIVE (DRUG ELUTING) VERSUS PASSIVE (BARE) STENTS

Putting drugs on stents that reduce the intimal proliferation was a logical thing to do because the foreign material increased the tendency for endothelial overgrowth. In small vessels, such as the coronary arteries, 1 mm of overgrowth (also named late loss) means a decrease in the lumen of 2 mm translating into a stenosis of at least 50%. After the initial results of the RAVEL trial showing no restenosis whatsoever with active stents, a veritable frenzy broke out. Strangely, the very bare stents that had had a low recurrence rate when they had been compared with plain balloon angioplasty all of a sudden were reported with recurrence rates in the realm previously typical for balloon angioplasty (Figures 4, 5) [19].

As with the transition from balloon angioplasty to passive stenting, the introduction of active stenting did by no means

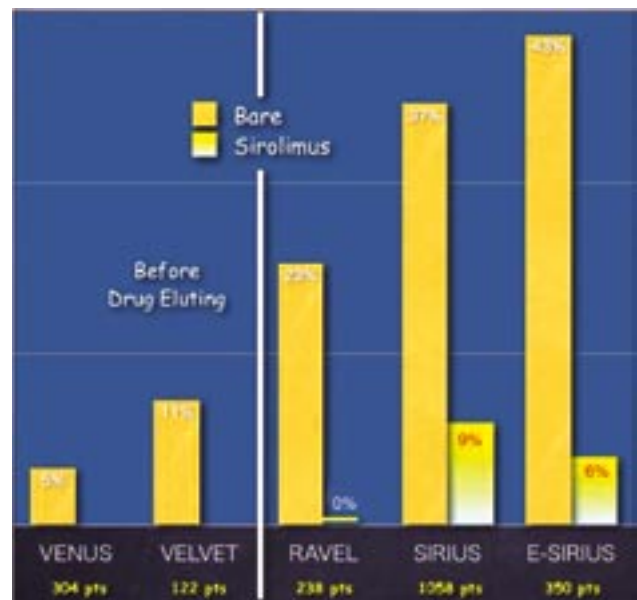


FIGURE 4. Restenosis rates of the Bx-Velocity stent in randomized trials when compared with plain balloon angioplasty (to the left of the white line) or its new active sibling, the Cypher stent (to the right of the white line). The initially favorable restenosis rates (5% and 11%) looked far less favorable (23% to 43%) when the same passive stent was used as a background for the new active stent. This clearly is good for publicity for the active stent but is rather difficult to explain.

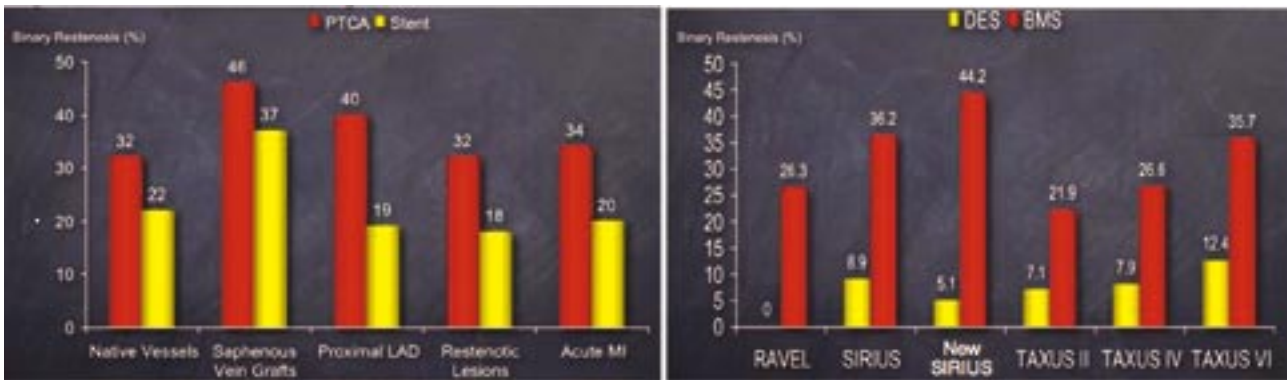


FIGURE 5. Summary of randomized trials comparing plain balloon angioplasty (PTCA) to passive stents (stent) in the left panel and active stents (DES) to passive stents (BMS) in the right panel. The restenosis rates of passive stents surprisingly increased drastically when moving from comparing them with balloon angioplasty to comparing them with the novel active stents. There is no plausible explanation for this.

improve safety of the procedure. Only this time this was anticipated and made sense. There was even an initial concern that late thrombosis may significantly increase as endothelial coverage was intentionally curbed and delayed. Fortunately this concern did not materialize, although currently some voices are raised that perhaps very late thrombosis may be increased due to a number of factors, such as incomplete coverage of the stent or late allergy to the polymer. In fact, mortality at 2 years appeared to be slightly higher with active versus passive stents [19], somewhat defying single randomized trials or registries yielding overall thrombosis rates below 2%, i.e., in the range of passive stents [16].

Moreover, it has to be feared that the beneficial restenosis pattern of active stents fosters an overly generous application of these modern devices. If too many and too long active stents are implanted, late thrombosis rates will inevitably increase. The risk of such an event grows at least linearly with every additional millimeter of stent. This has to be kept in mind even with extreme cases such as the one illustrated in figure 6.

### CONCLUSIONS AND PERSPECTIVES

Apparently, interventional cardiologists have sold themselves to stenting all lesions they perform coronary angioplasty upon. Furthermore, they also will use active stents in all cases before long. There are no data that support neither of these two policies but they are both appealing to operators and patients alike. There is even a possibility that the subscription to these habits will cost lives in exchange for some patient comfort, particularly if the numbers and length of stents implanted get out of hand. However, irrational behaving is a human feature and thus not estrange to interventional cardiologists either. If they insert a drug eluting stent and the outcome is not favor-

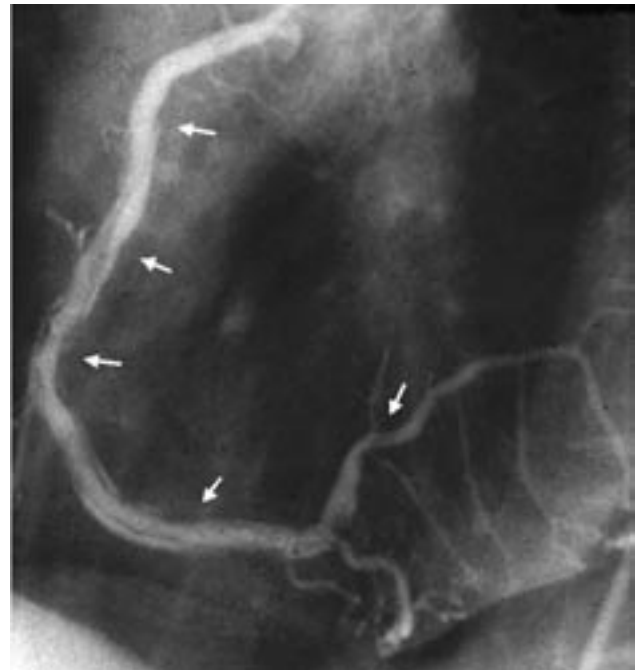

FIGURE 6. Extensive spiral dissection in a right coronary artery extending from the first third to the postero-lateral branch (arrows). Provided the flow is unimpeded, such lesions commonly healed well with a low potential for immediate and no potential for late closure. Today, such a situation is likely to be remedied by several active stents with an overall length of 50 mm or more. They are not only costly but they carry a substantial risk of late thrombosis, a more ominous problem than a restenosis.

able, nobody will blame them for it. If they insert a passive stent and the patient has a restenosis, they will be ridiculed. If they insert no stent and the patient has a restenosis, let alone

an abrupt closure, they will probably be called irresponsible and maybe even sued for it. The industry is enchanted and the tab is picked up by the patient.

## REFERENCES

1. Puel J, Joffre F, Rousseau H, Guermonprez B, Lancelin B, Valeix B, Imbert G, Bounhoure JP. Endo-prothèses coronariennes auto-expansives dans la prévention des resténoses après angioplastie transluminale. *Arch Mal Coeur* 1987; 8:1311-1312.
2. Schatz RA, Palmaz JC, Tio FO, Garcia F, Garcia O, Reuter SR. Balloon-expandable intracoronary stents in the adult dog. *Circulation* 1987; 76:450-457.
3. Roubin GS, Robinson KA, King III SB. Early and late results of intracoronary arterial stenting after coronary angioplasty in dogs. *Circulation* 1987; 76:891-897.
4. Sigwart U, Puel J, Mirkovitch V, Joffre F, Kappenberger L. Intravascular stents to prevent occlusion and restenosis after transluminal angioplasty. *N Engl J Med* 1987; 316:701-706.
5. Detre KM, Holmes DR, Jr., Holubkov R, et al. Incidence and consequences of periprocedural occlusion. The 1985-1986 National Heart, Lung, and Blood Institute Percutaneous Transluminal Coronary Angioplasty Registry. *Circulation* 1990; 82:739-750.
6. Schomig A, Kastrati A, Mudra H, Blasini R, Schuhlen H, Klauss V, Richardt G, Neumann FJ. Four-year experience with Palmaz-Schatz stenting in coronary angioplasty complicated by dissection with threatened or present vessel closure. *Circulation* 1994; 90:2716-2724.
7. Serruys PW, Strauss BH, Beatt KJ, Bertrand ME, Puel J, Rickards AF, Meier B, Goy JJ, Vogt P, Kappenberger L, Sigwart U. Angiographic follow-up after placement of a self-expanding coronary-artery stent. *N Engl J Med* 1991; 324:13-17.
8. Serruys PW, De Jaegere P, Kiemeneij F, et al. A comparison of balloon-expandable-stent implantation with balloon angioplasty in patients with coronary artery disease. *N Engl J Med* 1994; 331:489-495.
9. Fischman DL, Leon MB, Baim DS, et al. A randomized comparison of coronary-stent placement and balloon angioplasty in the treatment of coronary artery disease. *N Engl J Med* 1994; 331:496-501.
10. Weaver WD, Reisman MA, Griffin JJ, et al. Optimum percutaneous transluminal coronary angioplasty compared with routine stent strategy trial (OPUS-1): a randomised trial. *Lancet* 2000; 355:2199-2203.
11. Kiemeneij F, Serruys PW, Macaya C, et al. Continued benefit of coronary stenting versus balloon angioplasty: five-year clinical follow-up of Benestent-I trial. *J Am Coll Cardiol* 2001; 37:1598-1603.
12. Cook S, Togni M, Walpoth N, et al. Percutaneous Coronary Interventions in Europe 1992-2003. *Eur Intervent*; in press.
13. Meier B. Surgical standby for percutaneous intervention. In: Topol EJ, ed. *Textbook of Interventional Cardiology*, 4th edition. Philadelphia: Saunders Elsevier Science; 2003:p. 475-479.
14. Meier B, Gruentzig AR, King SB, Douglas JS, Hollman J, Ischinger T, Aueron F, Galan K. Risk of side branch occlusion during coronary angioplasty. *Am J Cardiol* 1984; 53:10-14.
15. Aliabadi D, Tilli FV, Bowers TR, Benzuly KH, Safian RD, Goldstein JA, Grines CL, O'Neill WW. Incidence and angiographic predictors of side branch occlusion following high-pressure intracoronary stenting. *Am J Cardiol* 1997; 80:994-997.
16. Wenaweser P, Rey C, Eberli FR, et al. Stent thrombosis following bare-metal stent implantation: success of emergency percutaneous coronary intervention and predictors of adverse outcome. *Eur Heart J* 2005; 26:1180-1187.
17. Brophy JM, Belisle P, Joseph L. Evidence for use of coronary stents. A hierarchical bayesian meta-analysis. *Ann Intern Med* 2003; 138:777-786.
18. Mehta H, Hotz R, Windecker S, Eberli FR, Meier B. Influence of frequency of stenting on acute and one-year follow-up results. *J Invasive Cardiol* 2003; 15:630-633.
19. Hill RA, Dundar Y, Bakhai A, Dickson R, Walley T. Drug-eluting stents: an early systematic review to inform policy. *Eur Heart J* 2004; 25:902-919.