

CASE REPORT

Redo Ventricular Tachycardia Ablation in a Frail Patient with Ischemic Cardiomyopathy: Benefit of Survival versus Risk of Complications

Dimitris Tsiachris, MD, Petros Arsenos, MD, Nikos Apostolopoulos, MD,
Anna Kefala, MD, Konstantinos A. Gatzoulis, MD

*Electrophysiology Laboratory,
First Department of Cardiology,
Hippokraton Hospital, University of
Athens, Athens, Greece*

KEY WORDS: *ventricular tachycardia;
transcatheter ablation; implantable
cardioverter defibrillator; late potentials;
incessant ventricular tachycardia*

ABSTRACT

We present a case of repeat successful ventricular tachycardia ablation in an elderly frail post-myocardial infarction patient who presented with recurrent and often incessant episodes of slow ventricular tachycardia. An 85-year old thin male fitted with an implantable cardioverter defibrillator (ICD) device presented with a hemodynamically stable, slow ventricular tachycardia, temporarily terminated after multiple anti-tachycardia pacing attempts. A previous recent ventricular tachycardia ablation procedure due to multiple ICD activations yielded poor result. Identification and elimination of late potentials was accompanied by final non-inducibility and a free from ventricular tachycardia mid-term outcome.

INTRODUCTION

Ventricular tachycardia (VT) is an important cause of morbidity and mortality in patients with a previous myocardial infarction. Electrical storm is a life-threatening arrhythmia complication affecting patients treated with an implantable cardioverter defibrillator (ICD).¹ ICDs are currently the mainstay of treatment for patients with ischemic cardiomyopathy or non-ischemic cardiomyopathy, who are at risk for sudden cardiac death due to VT.² However, ICDs effectively terminate VT, but do not prevent VT episodes. Defibrillator shocks increase mortality and worsen quality of life.³ Anti-arrhythmic combined therapy of beta-blocker and amiodarone reduces ICD shocks in a significant proportion of patients; however, amiodarone has significant side effects, resulting in drug discontinuation in nearly 25% of the patients.⁴

Catheter ablation of VT has made significant strides over the recent years with new evidence from prospective randomized trials on outcome in patients with ischemic heart disease.⁵⁻⁷ The role of catheter ablation is extremely important especially in order to control incessant VT and to reduce or prevent recurrent episodes of sustained VT.⁵ In the present manuscript, we present a case of repeat successful VT ablation in an elderly frail post-myocardial infarction patient who presented with recurrent and often incessant episodes of slow VT.

ABBREVIATIONS

ICD = implantable cardioverter
defibrillator

LPs = late potentials

VF = ventricular fibrillation

VT = ventricular tachycardia

Correspondence to:

Dimitris Tsiachris, MD, Pontou 5,
Athens 115 28, Greece;

Tel: 2107473161;

E-mail: dtsiachris@yahoo.com

Manuscript received March 19, 2014;

*Revised manuscript received and
accepted September 15, 2014*

Conflict of interest and sources of financial support: None declared

CASE REPORT

An 85-year old thin male (body mass index $<20 \text{ kg/m}^2$) was admitted to our department due to dizziness and palpitations caused by an incessant, though hemodynamically stable, slow ventricular tachycardia (VT) with blood pressure of 85/50 mmHg and heart rate of 145 bpm. VT was detected by his dual-chamber ICD (VT zone between 140 and 200 bpm and VF zone >200 bpm) but only temporarily terminated after multiple anti-tachycardia pacing attempts. Bolus and subsequent loading dose of intravenous amiodarone suppressed the incessant VT. Laboratory examination was unremarkable for abnormal findings.

Our patient had suffered from an inferior wall myocardial infarction treated conservatively 20 years earlier. He had also had a history of dual-chamber pacemaker implantation 14 years ago due to sick sinus syndrome. His pacing system was upgraded to ICD 7 years later after a clinical episode of VT. At that time and thereafter serial transthoracic echocardiograms revealed the presence of mild systolic dysfunction (left ventricular ejection fraction $\sim 45\text{-}50\%$) with postero-inferior wall akinesia. He reported numerous appropriate ICD activations during the last 7 years, treated initially with metoprolol and amiodarone. He was in chronic atrial fibrillation and had only exertional dyspnea (New York Heart Association class II). Seven months prior to admission, the patient underwent VT ablation due to recurrent VT episodes despite the administration of combined anti-arrhythmic therapy. Based on the report of the initial procedure, induced VT was ablated during activation mapping. No VT was inducible after the final programmed ventricular stimulation with up to 3 extrastimuli delivered at the right ventricular apex. The patient was discharged on mexiletine instead of amiodarone due to imaging findings suggestive of pulmonary fibrosis. His post-procedural course was characterized by 42 episodes of silent termination of recurrent slow VT until this episode of incessant slow VT occurred.

Despite the initial VT suppression after amiodarone administration, the old age and the frail condition of our patient (based on the low body mass index), it was decided to proceed with a repeat ablation procedure aiming to discontinue the precarious use of amiodarone (prior history of possible pulmonary toxicity). The procedure was performed under mild sedation with continuous monitoring of invasive arterial pressure.

A 3.5-mm distal-tip irrigated catheter (Navistar Thermo-cool SF, bidirectional D-F, Biosense Webster Inc, Diegem, Belgium) served as the mapping catheter using the retrograde transaortic approach. High-density substrate mapping with a fill threshold of 5 mm in low voltage areas (LVA) and 10 mm elsewhere was performed using the Carto[®] 3 workstation (Biosense Webster, Diamond Bar, California, USA). LV endocardial bipolar dense scar was defined as an area with a

bipolar voltage of $\leq 0.5 \text{ mV}$ and areas with a bipolar voltage $>0.5 \text{ mV}$ and $<1.5 \text{ mV}$ were defined as bipolar border zone. Scar was present in the basal part of the infero-postero-lateral wall (Fig. 1).

A color-coded map of sinus rhythm activation delay was drawn on the same anatomical shell by manual tagging the end of all electrograms (Late Potentials - LPs map). The definition of LPs included either continuous fragmented activity bridging from the main component within the QRS to the latest signal recorded outside the QRS (fractionated LPs), or isolated potentials recorded after the QRS offset (isolated LPs); the annotation on the mapping system was always taken at the latest recorded activity. LPs were present also in the basal part of the infero-postero-lateral wall (Fig. 1).

During high-density substrate mapping, the clinical VT was mechanically provoked while moving the catheter (cycle length 500 ms, monophasic R V1-3, transition zone in V4, rS in I, aVL, QS in II, qr in III, aVF) (Fig. 2). VT was ablated using activation mapping and directly terminated in the basal part of the posterior wall (Fig. 3). Pace-mapping maneuver at the termination site also revealed a nearly perfect matching with the clinical VT (Fig. 4). Ablation continued in spontaneous rhythm aiming at the complete abolition of LPs with a power setting of 30–35 Watts and a temperature limit of 43°C . Remapping documented the absence of LPs after ablation. Programmed ventricular stimulation with up to 3 extrastimuli from the right ventricular apex was performed without inducing any VT (Fig. 5).

The procedure was completed uneventfully and the patient was discharged home 48 hours later. Amiodarone was discontinued 1 month later. The patient remains asymptomatic and in good clinical condition without ICD activation after a short follow-up period of 10 months.

DISCUSSION

Selection of catheter ablation for an individual patient should consider risks and benefits that are determined by patient characteristics, as well as the availability of appropriate facilities with technical expertise. In patients with structural heart disease, episodes of sustained VT are a marker of increased mortality and reduced quality of life in those who have ICDs.^{1,3,5} Anti-arrhythmic medications can reduce the frequency of ICD therapies, but have modest efficacy and side effects.^{4,5} Advances in technology and understanding of VT substrates now allow ablation of multiple and unstable VTs with acceptable safety and efficacy, even in patients with advanced heart disease.⁸ It has also been reported that catheter ablation within a dedicated VT unit, prevents long-term VT recurrences and may favorably affect survival in structural heart disease patients who have VT.⁸

Inducibility of sustained monomorphic VT is considered

REDO VENTRICULAR TACHYCARDIA ABLATION

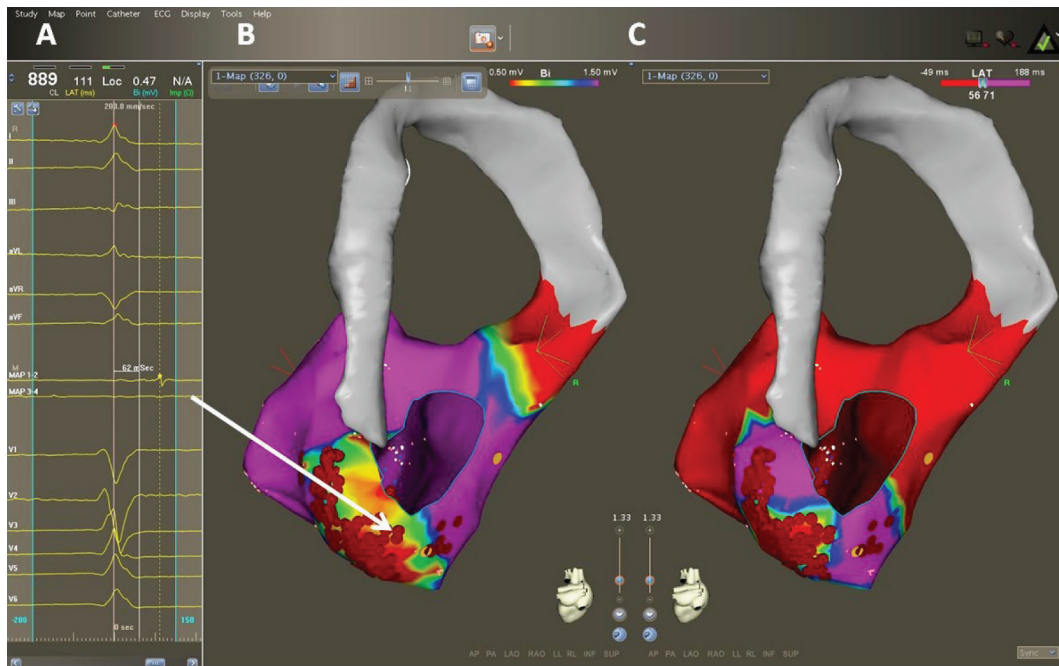


FIGURE 1. Isolated late potential recorded after the QRS offset (A). Endocardial bipolar dense scar was defined as an area with a bipolar voltage of ≤ 0.5 mV and areas with a bipolar voltage >0.5 mV and <1.5 mV were defined as bipolar border zone. Scar was present in the basal part of the infero-postero-lateral wall (B). Fractionated and isolated late potentials recorded after the QRS offset, annotated on the mapping system during sinus rhythm, were also present within the scar in the basal part of the infero-postero-lateral wall (C).

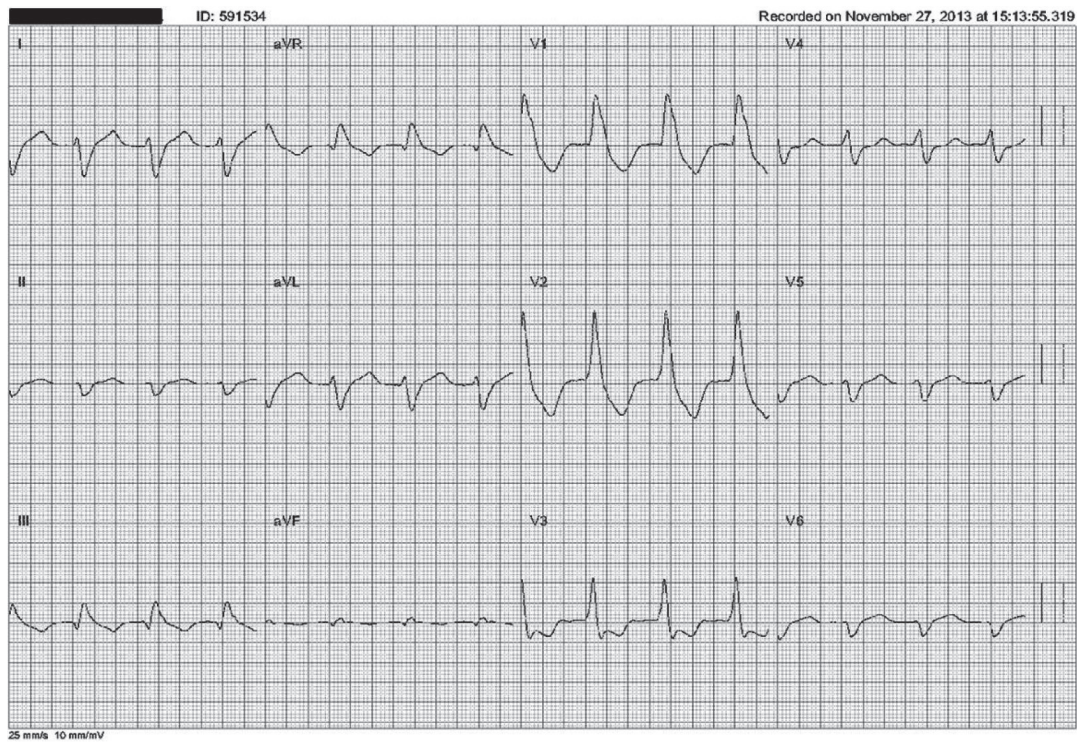


FIGURE 2. Twelve lead ECG of the clinical and spontaneously induced ventricular tachycardia.

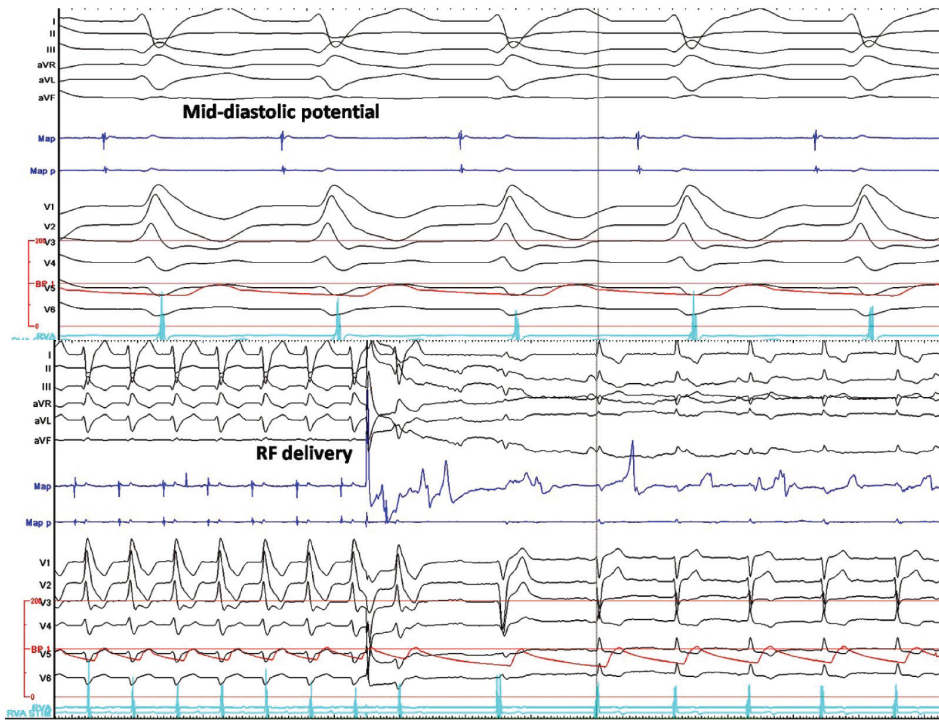

FIGURE 3. Ventricular tachycardia was ablated during activation mapping and directly terminated in the basal part of the posterior wall.

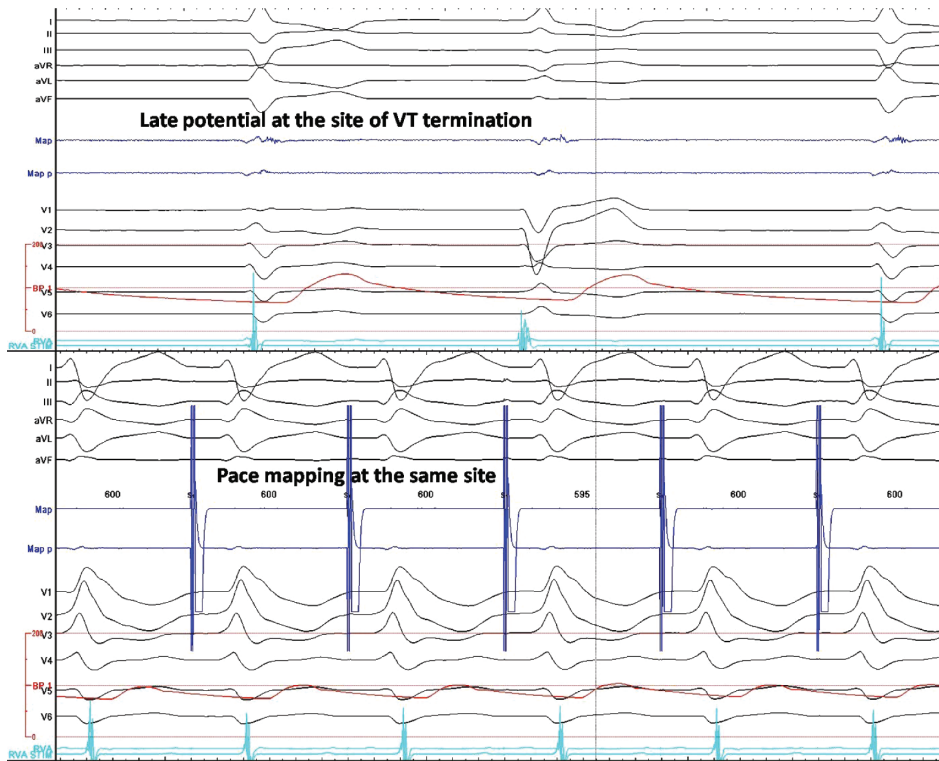


FIGURE 4. Pace-mapping maneuver at the termination site, where late potential was present, also revealed a nearly perfect matching with the clinical ventricular tachycardia.

- S. EHRA/HRS Expert Consensus on Catheter Ablation of Ventricular Arrhythmias: developed in a partnership with the European Heart Rhythm Association (EHRA), Registered Branch of the European Society of Cardiology (ESC), and the Heart Rhythm Society (HRS); in collaboration with the American College of Cardiology (ACC) and the American Heart Association (AHA). *Europace* 2009; 11:771–817.
6. Gatzoulis KA, Ioannidis P, Vassilopoulos HB. Electrical storm 11 years after ICD implantation in a patient with dilated cardiomyopathy: the role of RF ablation. *Hospital Chronicles* 2006; 1(sup):58-61.
 7. Gatzoulis KA, Dilaveris P, Sideris S. Electrical Storm ablation in a post-myocardial infarction patient before the ICD Implantation. Long term outcome. *Hospital Chronicles* 2006; 1(sup): 58–61.
 8. Della Bella P, Baratto F, Tsiachris D, et al. Management of ventricular tachycardia in the setting of a dedicated unit for the treatment of complex ventricular arrhythmias: long-term outcome after ablation. *Circulation* 2013; 127:1359-1368.
 9. Soejima K, Suzuki M, Maisel WH, et al. Catheter ablation in patients with multiple and unstable ventricular tachycardias after myocardial infarction: short ablation lines guided by reentry circuit isthmuses and sinus rhythm mapping. *Circulation* 2001; 104:664-669.
 10. Stevenson WG, Wilber DJ, Natale A, et al, for the Multicenter Thermocool VT Ablation Trial Investigators. Irrigated radiofrequency catheter ablation guided by electroanatomic mapping for recurrent ventricular tachycardia after myocardial infarction: The Multicenter Thermocool Ventricular Tachycardia Ablation Trial. *Circulation* 2008; 118:2773-2782.
 11. Bogun F, Good E, Reich S, et al. Isolated potentials during sinus rhythm and pace-mapping within scars as guides for ablation of post-infarction ventricular tachycardia. *J Am Coll Cardiol* 2006; 47:2013-2019.
 12. Vergara P, Trevisi N, Ricco A, et al. Late potentials abolition as an additional technique for reduction of arrhythmia recurrence in scar related ventricular tachycardia ablation. *J Cardiovasc Electrophysiol* 2012; 23:621-627.