

IMAGES IN MEDICINE

# Anomalous Left Circumflex Coronary Artery: Not Always Benign. A Worm-Like Thrombus Can Be Housed in This Most Common Coronary Anomaly

Antonis S. Manolis, MD, Spyridon Koulouris, MD

*First Department of Cardiology,  
Evangelismos General Hospital of  
Athens, Athens, Greece*

**KEY WORDS:** *coronary anomaly;  
ectopic left circumflex; acute  
myocardial infarction; intracoronary  
thrombus; coronary angioplasty;  
coronary stenting; thromboaspiration*

**ABBREVIATIONS**

ECG = electrocardiogram  
LAD = left anterior descending (coronary artery)  
LCx = left circumflex (coronary artery)  
NSTEMI = non-ST elevation myocardial infarction

*Correspondence to:*  
Antonis S. Manolis, MD, Evangelismos Hospital, Athens, Greece; e-mail: asm@otenet.gr

*Manuscript received and accepted June 30, 2012*

Conflict of Interest: none declared

---

**ABSTRACT**

---

A case of an anomalous left circumflex (LCx) coronary artery originating from the right coronary ostium is presented in a patient with acute myocardial infarction, whereby a long worm-like thrombus was retrieved from the proximal segment of this artery, which was subsequently stented. This case illustrates that the anomalous LCx is not always benign, and may well predispose to an acute coronary syndrome, requiring interventional management.

---

**CASE**

---

A 47-year-old smoker and hypertensive gentleman was admitted via the emergency room with chest pain and ECG displaying ischemic changes (ST depression) in the precordial leads. Cardiac troponin was elevated and a diagnosis of non-ST elevation myocardial infarction (NSTEMI) was entertained. He was initially stabilized with medical therapy and was submitted to coronary angiography the next day after his admission. During contrast injection into the left coronary ostium, a single coronary artery was visualized having a course consistent with the left anterior descending (LAD) coronary artery (left anterior oblique view with caudal angulation, Panel A). This artery was free of any significant disease. Subsequently, the right coronary ostium was engaged and contrast injection revealed the right coronary artery at its normal course, while an ectopic left circumflex (LCx) coronary artery could also be visualized originating from the same ostium and following a retro-aortic course to the posterolateral wall of the left ventricle (left anterior oblique view, Panel B). This view also demonstrated a significant long smooth narrowing of the artery at its proximal segment (Panel B, arrow). In spite of an initial diagnosis of NSTEMI, the absence of disease in the LAD and in the presence of a stenosis in the ectopic circumflex together with the ECG changes of “anterior” subendocardial ischemia, it was considered that these ST-T wave changes in the precordial leads rather represented mirror image of a true posterior myocardial infarction. Thus, before proceeding with angioplasty and

## ECTOPIC LEFT CIRCUMFLEX

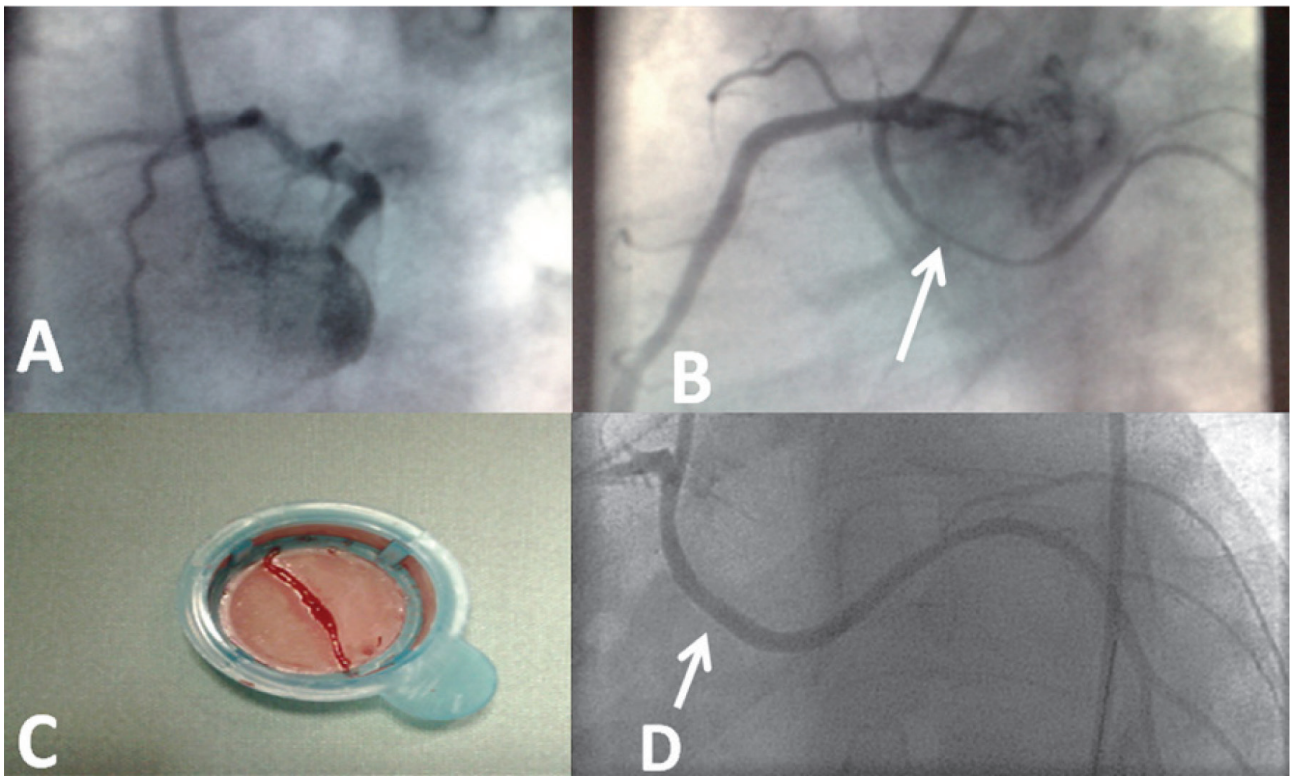


FIGURE 1.

stenting, an aspiration catheter was employed and to our surprise it retrieved a long worm-like thrombus from the artery (Panel C), which was subsequently stented (Panel D, arrow). The patient had an uneventful hospital course and has been doing well during a subsequent 3-year follow-up.

•••

Congenital coronary anomalies are encountered in 0.6%-1.6% of patients undergoing coronary angiography.<sup>1,2</sup> Apart from a quite frequent occurrence of separate ostia for the two left coronary arteries, LAD and LCx (absent left main trunk),<sup>2,4</sup> an anomalous LCx from the right coronary ostium is the second most common coronary anomaly observed in 0.4-0.7% of all patients. Occasionally, detection of an ectopic LCx may be elusive and this, of course, may have serious consequences for the management of patients with this aberration. This coronary anomaly has generally been classified as benign and may be asymptomatic in the majority of patients. However, a few cases of sudden death, myocardial infarction and angina have been reported in the absence of typical coronary atherosclerosis.<sup>5-7</sup> Angioplasty and stenting of this anomalous coronary artery, when needed, poses certain technical difficulties related to engaging the ostium with the guiding catheter and advancing balloons and stents through the anomalous course of the artery.<sup>8-10</sup>

In the present case, it remains doubtful whether typical atherosclerosis was responsible for the occurrence of occlusive thrombus or compression of that retroaortic segment of the artery predisposed to its development. Nevertheless, thromboaspiration combined with coronary stenting remedied the patient's problem. To our knowledge, this is the first reported case of acute posterior myocardial infarction in an ectopic LCx managed with thrombus aspiration and stenting of a possibly compressed proximal segment of a LCx with the anomalous course. Thus, this patient illustrates that in certain circumstances the anomalous LCx may not be just a normal variant and always considered benign, but it may well predispose to acute coronary syndrome. Fortunately, if promptly detected and appropriately managed, the prognosis is favorably influenced.

## REFERENCES

1. Yamanaka O, Hobbs RE. Coronary artery anomalies in 126,595 patients undergoing coronary arteriography. *Cath Cardiovasc Diagn* 1990; 21:28-40.
2. Yildiz A, Okcun B, Peker T, Arslan C, Olcay A, Bulent Vatan M. Prevalence of coronary artery anomalies in 12,457 adult patients who underwent coronary angiography. *Clin Cardiol* 2010;33:E60-64.

3. Stalikas D, Metaxa S, Koulouris S, Manolis AS. Phantom stent thrombosis. *Hosp Chronicles* 2011;6:96-97.
4. Manolis AS, Koulouris S, Kappos K, Avramidis D, Pyrros J, Kalogeropoulos H. Pseudo left main coronary artery disease. *Hosp Chronicles* 2007; 2:94.
5. Rozenman Y. Anomalous origin of the circumflex coronary artery from the right sinus of Valsalva as a cause of ischemia at old age. *Clin Cardiol* 1993, 16:900-1.
6. Corrado D, Penelli T, Piovesana P, Thiene G. Anomalous origin of the left circumflex coronary artery from the right aortic sinus of Valsalva and sudden death. *Cardiovasc Pathol* 1994, 3:269-71.
7. Grasso AE, Pennell DJ. Myocardial infarction related to aberrant left circumflex artery. *Int J Cardiol* 2010;138:e51-2.
8. Blanchard D, Ztot S, Boughalem K, et al. Percutaneous transluminal angioplasty of the anomalous circumflex artery. *J Interv Cardiol* 2001, 14:11-16.
9. West NE, McKenna CJ, Ormerod O, Forfar JC, Banning AP, Channon KM. Percutaneous coronary intervention with stent deployment in anomalously-arising left circumflex coronary arteries. *Catheter Cardiovasc Interv* 2006;68:882-890.
10. Manolis AS, Bronis K, Haviatsos T, Koulouris S. "Real world" adhoc percutaneous coronary interventions with use of sirolimus eluting stents: A single operator experience and long-term follow-up. *Hosp Chronicles* 2011;6:182-194.