

HOW TO SESSION: TECHNIQUES & PRACTICE

Endovascular Treatment of Aortic Aneurysms: the Role of the Multilayer Stent

¹*Hemodynamic & Interventional Cardiology, Evagelismos Hospital Athens, Greece*

²*Nancy France*

³*Thoracic & Vascular Surgery, Evagelismos Hospital Athens, Greece*

⁴*1st Surgical Department University of Thessaloniki, Greece*

⁵*5th Surgical Department, University of Thessaloniki, Greece*

⁶*2nd Cardiac Surgery, Evagelismos Hospital Athens, Greece*

⁷*Pediatric division of Cardiology, Onassis Cardiac Surgery Center, Athens, Greece*

⁸*Radiology Department, Nicosia General Hospital Cyprus*

⁹*Vascular Surgery, Internal Medicine, Cardiology Departments, Airforce Hospital, Greece*

¹⁰*Radiology Department, Sismanogleio General Hospital, Greece*

¹¹*Radiology Department, Evagelismos Hospital, Athens, Greece*

¹²*1st Cardiology Department, Evagelismos Hospital, Athens, Greece*

KEY WORDS: *aortic aneurysm; stent; multilayer stent*

Correspondence to:

Antonios Polydorou, MD,
Catheterization Laboratory,
Evagelismos Hospital, Athens,
Greece;

e-mail: antonios.polydorou@gmail.com

Conflict of Interest: none declared

Antonios Polydorou, MD,¹ Michel Henry, MD,² Ion Bellenis, MD,³ Dimitrios Kiskinis, MD,⁴ Konstantinos Papazoglou, MD,⁵ Kalliopi Athanasiadou, MD,³ Charalambos Zisis, MD,³ Gregory Nacopoulos, MD,³ Athanasios Portinos, MD,³ John Kokotsakis,⁶ Spyros Rammos, MD,⁷ Chrysa Tziakouri, MD,⁸ Theodosios Perdikides, MD,⁹ Adamantia Polydorou, MD,⁹ Victoria Polydorou, MD,⁹ John Stavrou, MD,¹⁰ Elias Samiotis, MD,³ Iacovos Ttofis, MD,³ Eleni Antypa, MD,¹¹ Eleni Testebasi, MD,¹¹ Xenia Stathopoulou, MD,¹² Dimitris Belesiotis, MD,¹² Ageliki Baladima, MD,¹² Sofia Metaxa, MD,¹² Antonis S. Manolis, MD¹²

ABSTRACT

AIM: The purpose of this study was to evaluate the safety and effectiveness of the multilayer flow modulator and its delivery system for totally endovascular repair of aortic aneurysms in high risk patients and to demonstrate deployment success and preservation of all side-branch vessels.

METHODS AND RESULTS: We report on 22 cases (mean age 67 ± 5 years all males) with thoracic, thoracoabdominal and abdominal aneurysm considered high risk patients for surgical treatment. In all patients, treated with a multilayer stent, there were side branches arising from the aneurysm sac and maintained patency after the procedure. Two patients died after the procedure: 1 patient who developed a stroke two weeks post procedure and 1 patient who sustained a myocardial infarction two days post-procedurally. No vascular or systematic complications were observed in the other 20 patients in the short and long term follow-up.

CONCLUSIONS: Our preliminary results indicate that the use of the multilayer stent is feasible and seems to be safe for the management of aortic aneurysm with side branches.

INTRODUCTION

Aortic aneurysms represent the 13th leading cause of death in the U.S. Aortic aneurysm is a significant disease that usually leads to death from rupture if not treated in time. Each year, about 15,000 people in the United States die of a ruptured aneurysm.

Fortunately, not all aneurysms rupture right away. Many grow very slowly and cause no symptoms.

Most aneurysms occur in people aged 55 years or older and are 4 times more common in men than in women. Aortic aneurysm is most common in the abdominal aorta (AAA) than in the thoracic aorta (TAA). The management of aortic aneurysm may be medical, surgical or endovascular. In our laboratory we follow the endovascular treatment whenever it is indicated. Furthermore, many cases, especially when collaterals are arising throughout the aneurysm are not suitable for endovascular treatment by use of the classical covered endografts and a new method of treatment with a multilayer stent is used.

Aneurysms are classified into several different types. According to aneurysm position, we have thoracic aneurysms of the ascending aorta, the aortic arch, or the descending aorta; abdominal aneurysms of suprarenal, juxtarenal, or infrarenal location, and; thoracoabdominal aneurysms. According to their morphology, we have fusiform and saccular aneurysms. According to their formation, we have true aneurysms and false or pseudo aneurysms. According to their pathogenesis, aneurysms are classified into degenerative/atherosclerotic, traumatic, dissecting, infective (bacterial / syphilitic), connective tissue disorders (Marfan / Ehlers – Danlos syndromes), arteritis (Takayasu), congenital, drug-induced (cocaine / amphetamines, etc).

Three recently published reports have demonstrated that the application of the multilayer stent results in effective treatment of aortic dissection, thoracoabdominal and renal aneurysm.¹⁻³ Our study was conducted to prove the feasibility of using the multilayer stent in order to treat a patient with high surgical risk, who has an aortic aneurysm with side branches.

METHODS

A study protocol was designed to examine the safety and efficacy of the Cardiatis Multilayer Stent in high risk patients with aortic aneurysms. Between December 2006 and December 2011, 22 male patients were enrolled in the study: 1 patient with thoracic aneurysm (diameter, 57 mm), 3 abdominal (mean diameter 76 mm) and 18 thoracoabdominal (mean diameter 58 mm).

STUDY PROCEDURE

Prior to the endovascular treatment with the multilayer stent, patients underwent baseline evaluation that included physical examination, review of medications and full screening of biochemical profile. A pre-procedural thoracic, abdominal or thoracoabdominal computed tomography (CT) angiogram was performed in each patient.

The device was inserted via the right or left femoral artery and was placed at the aneurysm.

RESULTS

The multilayer stent was successfully deployed in all patients (100% technical success). Mean follow-up for the thoracic aneurysm was 28 months, for the aortic aneurysms was 12 months and for thoracoabdominal aneurysm 12 months. The one-month follow up CT angiogram for the thoracic, the abdominal and thoracoabdominal aneurysms, showed patent arterial side branches and reduced blood flow inside the sac. The 6 and 12 month follow up CT angiogram showed patent arterial side branches, thrombus inside the sac or shrinkage of the sac.

DISCUSSION

The multilayer self-expandable stent consists of a 3D braided tube; it is built as a structure involving several interconnected layers, as shown in Figure 1.

The number of layers is adaptable to the application site, femoral or carotid stenosis, cerebral or aortic aneurysm. It has a high kinking resistance and high resistance to fatigue due to the interlocked layers (Fig. 2).

When the aneurysm is saccular without branch, we have an organized stable thrombus. It will resorb with time.

The particle image velocimetry (PIV) method was used to show that we can follow the movement of 1 vortex with




FIGURE 1. 3D structure.




FIGURE 2. High kinking resistance.

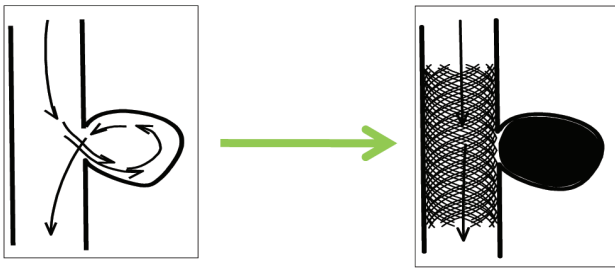


FIGURE 3.

time at a rate of 25 images/s. We can see that more the vortex moves along the aneurismal wall more it becomes stronger (like a hurricane with an eye). This vortex will be followed by another one, etc (Fig. 4).

Figure 5 shows, at equal time, that the stent slows down the movement speed of the vortex and reduces its force. The speed reduction creates a kind of “traffic jam” like in the high way which leads to thrombosis.

In Figure 6, the image on the left shows that the vortices do not follow the same way when they enter in the aneurysmal sac, however in the image on the right the vortices are aligned, they follow the same trajectory, that’s why it leads to thrombosis. Now this behavior is effective when the stent has enough density of the mesh as the multilayer (this is not possible with the monolayer stent).

When the aneurysm has a branch, there is no thrombus formation. The whole flow entering the aneurysm is aspirated by the branch and no flow stagnates along the aneurysmal wall;

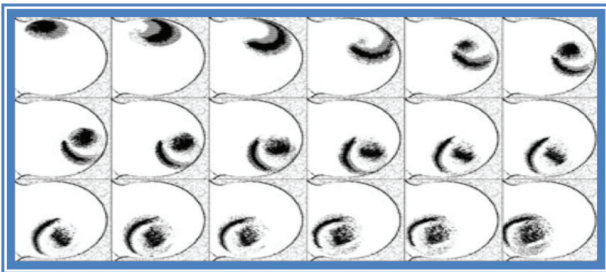


FIGURE 4.

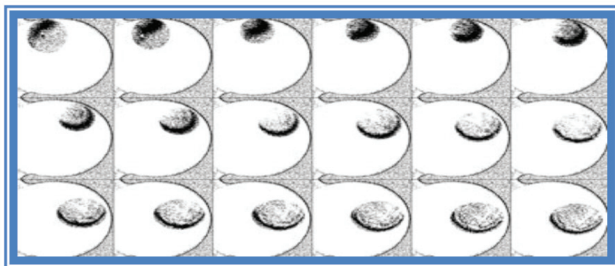


FIGURE 5.

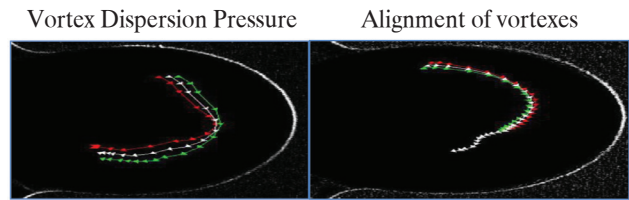


FIGURE 6.

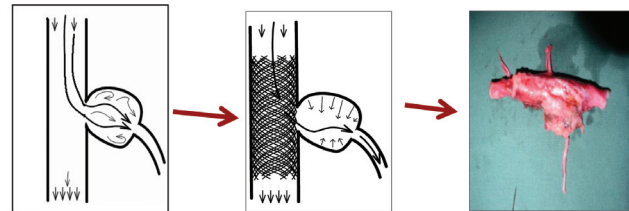


FIGURE 7.

what is happening is that the wall falls down which leads to its shrinkage. This unique behavior keeps the branch patent.

All the flow is directed to the branch. The more the flow is moving toward the branch the more it creates a barrier between the aneurysmal wall of the branch. This is directed by the layers, this is not possible by a normal stent. If we add the 2 types of the aneurysm discussed above we get an abdominal aortic aneurysm. When the sac of the aneurysm is stretched the flow is laminated and the area where we have the mesenteric or other arteries is shrunk. It should be noted that the large stents for the aortic applications can be inserted percutaneously.

CONCLUSION

The Cardiatis Multilayer Stent seems to be efficacious as the side branches remain patent and the aneurysm is excluded. The question remains about the time needed to reach the optimum result after stenting the aneurysm in large arteries such as the thoracic and abdominal aorta. We believe this phenomenon is related to the number and size of the side branches within the aneurysm. A larger multi center study is underway to confirm the suitability of Cardiatis Multilayer Stent for the large thoracic, abdominal and thoracoabdominal aneurysms.

REFERENCES

1. Chocron S, Vaislic C, Kaili D, Bonneville J-F. Multilayer stents in the treatment of thoraco-abdominal residual type B dissection. *Interact CardioVasc Thorac Surg* 2011;12:1057-1059.
2. Benjelloun A, Henry M, Ghannam A, et al. Endovascular treatment of a tuberculous thoracoabdominal aneurysm with the multilayer stent. *J Endovasc Ther* 2012;19:115-120.
3. Henry M, Polydorou A, Frid A, et al. Treatment of renal aneurysm with the multilayer stent. *J Endovasc Ther* 2008;15:231-236.