

IMAGING CARDIOLOGY UPDATE

The Pivotal Role of Three-Dimensional Transesophageal Echocardiography in Non-Coronary Intervention Procedures

Ioannis Felekos, MD, Emmanuel Poulidakis, MD, Constantina Aggeli, MD

ABSTRACT

The recent availability of real-time 3-dimensional (3D) transesophageal echocardiography (TEE) can drive forward the diagnostic capability of ultrasound imaging. Real time 3D TEE has evolved into the imaging modality of choice when it comes to percutaneous interventions, as in many cases it serves as the ‘eyes of the operator’ to evaluate, guide, and assess the results of the procedures in the catheterization laboratory. Moreover, it has been shown to provide additional insight into the anatomical, morphological and hemodynamic status. Up to date, real time 3D TEE has been integrated into the following percutaneous non-coronary procedures: closure of atrial or ventricular defects, aortic valve replacement, paravalvular leak occlusion, mitral valve repair with clips, and more recently left atrial appendage occlusion with use of closure devices. Further technological advancements will lead to more accurate and wider use of this imaging technique.

*1st Cardiology Department,
Hippokraton Hospital, Athens
University Medical School, Athens,
Greece*

KEY WORDS: *echocardiography;
three-dimensional echo; non-
coronary percutaneous interventions;
transcutaneous aortic valve
implantation; percutaneous mitral
valve repair; atrial septal defect closure*

INTRODUCTION

Over the past few years transesophageal echocardiography (TEE) has emerged as one of the most innovating imaging modalities available today in modern clinical cardiology, as it has served as a valuable adjunct in clinical decision making.¹ The 2-dimensional (2D) multiplane TEE though widely used in a variety of clinical scenarios, it has the inherent limitation of obtaining non-simultaneous and limited cutting planes that occasionally are unable to provide comprehensive and diagnostic cardiac images. Moreover the existence of only 2 spatial dimensions often necessitates the acquisition of multiple planes in order to mentally reconstruct three dimensional structures.²

In this setting, novel real-time three-dimensional (3D) echocardiography appears as the holy grail of cardiovascular imaging, as it can produce multiple anatomic views of any given structure, thus avoiding any geometrical assumptions. The recent availability of real-time 3-dimensional transesophageal echocardiography might drive forward the diagnostic capability of ultrasound imaging.

LIST OF ABBREVIATIONS

2D = two-dimensional

3D = three-dimensional

RT 3D TEE = real-time three-dimensional transesophageal echocardiography

TAVI = transcatheter aortic valve implantation

TEE = transesophageal echocardiography

Correspondence to:

Constantina Aggeli, MD,

Ippokraton University Hospital,

Athens, Greece;

e-mail: dina.aggeli@gmail.com

Conflict of interest: none declared

TECHNICAL CONSIDERATIONS

Current real-time three-dimensional transesophageal echocardiography (RT 3D TEE) employs a dedicated novel matrix-array technology, with a large number of transducer elements, containing more than 2500 active elements as opposed to conventional phased array transducer that contains only 128. It is of similar size when compared with a conventional multiplanar 2D TEE probe, measuring 1.5 cm in width, 1.0 cm in height, and 4.5 cm in length, with a cross-sectional area of 14 mm.³

Depending on the clinical scenario, there are three major modes of data acquisition, during RT-3D-TEE. A *full-volume* mode enables the acquisition of data as a pyramidal volume. This mode has the distinct advantage of allowing the acquisition of wider data volume and enables a complete overview of cardiac chambers. However, stitching artifacts may impede the quality of obtained images, leading in diagnostic difficulties. *Three-dimensional (3D) zoom* enables focusing in a specific structure, such as a heart valve, with the cost of lower temporal resolution though. Finally, *live 3D* allows real-time imaging of the cardiac structure, which is extremely useful during interventional procedures as it enables accurate visualization of catheters and devices within its surrounding environment.⁴

The obtained data can be processed off-line using a dedicated software package which allows cropping and rotation of the 3D images, as well as quantification analysis.

CLINICAL APPLICATIONS

In this article, we will briefly discuss the clinical applications of RT3D TEE in evaluating patients who are suitable for percutaneous interventions, before, during and after completing the procedure. Up to date, RT 3D TEE has been integrated in the following percutaneous non-coronary procedures: the closure of atrial or ventricular defects, the aortic valve replacement, paravalvular leak occlusion, as well as the mitral valve repair with clips. More recently left atrial appendage occlusion has also become feasible and available.

Real time 3D TEE has evolved into the imaging modality of choice when it comes to percutaneous interventions, as in many cases it serves as the 'eyes of the operator' to evaluate, guide, and assess the results of the procedures in the hemodynamic laboratory. Moreover, it has been shown to provide additional insight into the anatomical, morphological and hemodynamic status.

Importantly, the success of these procedures is predicated upon careful case selection based on anatomic considerations. A characteristic example of the previous statement is the pre-procedural selection of patients who are candidates for the mitral clip implantation. Pre-procedural assessment by

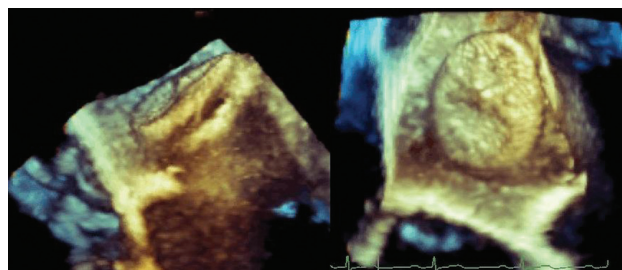


FIGURE 1. Monitoring ASD closure. ASD = atrial septal defect.

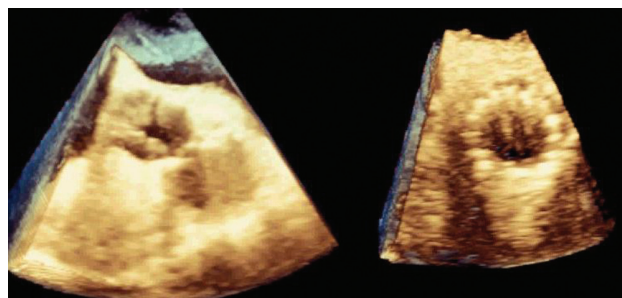


FIGURE 2. RT 3D TEE, short axis view in a patient undergoing TAVI. (a) pre, and (b) post implantation. RT 3D TEE = real time three-dimensional transesophageal echocardiography; TAVI = transcatheter aortic valve implantation.

RT 3D TEE provides incremental information not obtainable with 2D TEE through the use of en face views. These en face views allow better to identify exactly the morphology of each cardiac region of interest. After off-line analysis accurate measurements can be obtained. Also, the use of color Doppler in full volume data detects any abnormal flow in the cardiac chambers. The operator can easily detect the origin of regurgitant jets, as well as the existence of multiple jets. All this incremental information leads to better selection of cases and better planning of the interventional procedures.⁵

The main advantage of RT 3D TEE is the ability to visualize the entire length of intracardiac catheters as well as the balloons or devices attached to the catheters, their position and their anatomical relation to neighboring landmarks or to important cardiac structures. This is extremely helpful, for instance, during the transcatheter aortic valve implantation (TAVI) procedure, where the accurate imaging of coronary vessel orifice is of paramount importance. Real time 3D TEE can provide the interventional cardiologist with the proper anatomic information needed for the safe landing of the prosthetic aortic valve. An important consideration during performance of aortic stenting using the Core Valve system is the position of the device inside the left ventricular outflow tract. Imprecise positioning can lead to severe aortic regurgitation, especially

when the device has been drawn back too much into the aorta. In contrast, malpositioning of the device too much inside the left ventricle might lead to restricted movement of the anterior leaflet of the mitral valve.⁶

One step further, in the post-procedure period, RT 3D TEE imaging is advantageous over 2D TEE in that off-angle device placement is more easily appreciated. Recognition of off-angle device placement by 2D TEE imaging requires multiple imaging angles to demonstrate the spatial relationship between the device and the cardiac structures. On the contrary, the employment of RT 3D TEE allows the acquisition of multiple views which can be cropped and rotated accordingly in order to visualize proper device placement. Finally, color Doppler confirms the success of the procedure. In cases that residual problems are defined, the device needs to be recaptured or deployed.⁷

Real time 3D TEE has many other advantages. It has high spatial and temporal resolution, which allows unique detailed views of cardiac structures. This additional structural information helps guide interventional procedures leading to safer and shorter procedures with higher technical success, decreased radiation exposure and improved patient outcomes. So far, 2D TEE and intracardiac echocardiography are frequently used during the procedure to guide device placement. While these modalities suffer from poor spatial resolution, on the contrary, RT 3D has excellent spatial resolution.

LIMITATIONS - FUTURE DIRECTIONS

The RT 3D TEE as a new technique being evaluated in clinical practice has limitations that will probably be overcome in the near future. These include the need for additional training, reduced temporal resolution, particularly while the 3D zoom mode is used. Furthermore, the lack of standardized views and tissue dropout are also limitations needing experience to improve the communication between the echocardiographer and the interventionalist.

We are in anticipation of major improvements in technology, in order to be able to acquire all the information in a single beat even in TEE procedure. Moreover, the advancements in software, the miniaturization of transducer matrix technology and probably the online quantitative software will lead to more accurate and wider use of this imaging technique.

So far, the 2D technology, while it seems adequate, it can be combined perfectly well with the 3D technology. It seems that 2D TEE quickly loses luster and appeal. Modern skilled echocardiographers will undoubtedly be eager to replace their previous 2D technology with a new 3D one.

REFERENCES

1. Nihoyannopoulos P, Kisslo J (eds): *Echocardiography* (book), Spingel-Verlag, edition 2009.
2. Lee AP, Lam YY, Yip GW, Lang RM, Zhang Q, Yu CM. Role of real time three-dimensional transesophageal echocardiography in guidance of interventional procedures in cardiology. *Heart* 2010; 96:1485-1493.
3. Brochet E, Vahanian A. Echocardiography in the catheterisation laboratory. *Heart* 2010; 96:1409-1417.
4. Balzer J, Kelm M, Kühl HP. Real-time three-dimensional transoesophageal echocardiography for guidance of non-coronary interventions in the catheter laboratory. *Eur J Echocardiogr* 2009; 10:341-349.
5. Balzer J, Kühl H, Rassaf T, et al. Real-time transesophageal three-dimensional echocardiography for guidance of percutaneous cardiac interventions: first experience. *Clin Res Cardiol* 2008; 97:565-574.
6. Perk G, Lang RM, Garcia-Fernandez MA, et al. Use of real time three-dimensional transesophageal echocardiography in intracardiac catheter based interventions. *J Am Soc Echocardiogr* 2009; 22:865-882.
7. Aggeli C, Bellamy M, Sutaria N, Stefanadis C, Nihoyannopoulos P. Real-time 3-dimensional transoesophageal echocardiography: an indispensable resident in the catheter laboratory. *Hellenic J Cardiol* 2012; 53:1-5.