

VIDEO SESSION - CASE REPORT

Idiopathic Effusive-Constrictive Pericarditis

Anastasios Papaspyropoulos, MD, Eirini Andrikou, MD,
Eleni Kalkandi, MD, Athanasios Kranidis, MD

*Cardiology Department of General
Hospital of Western Attica, Athens,
Greece*

KEY WORDS: *aortic isthmus;
coarctation; pseudoaneurysm;
computed tomography;
thromboembolism*

ABBREVIATIONS / ΣΥΝΤΗΜΗΣΕΙΣ

AVR = χειρουργική αντικατάσταση
αορτικής βαλβίδας (aortic valve
replacement)
BAV = διαδερμική αορτική βαλβιδοτομή
με μπαλόνι (balloon aortic
valvuloplasty)
EF = κλάσμα εξώθησης (ejection fraction)
TAVI = διαδερμική εμφύτευση
προσθετικής βαλβίδας (transcatheter
aortic valve implantation)

Correspondence to:
Eleni Kalkandi, MD
E-mail: elkalakndi@yahoo.gr

ABSTRACT

We herein describe the case of a 71-year-old man, who presented with clinical manifestations of congestive heart failure, in whom non-invasive imaging techniques played a decisive role in arriving at the correct diagnosis of effusive-constrictive pericarditis.

INTRODUCTION

Effusive-constrictive pericarditis is characterized by constriction of visceral pericardium with a coexisting tense pericardial effusion. Effusive constrictive pericarditis is a relatively uncommon pericardial condition.¹ We present a case of idiopathic effusive-constrictive pericarditis.

CASE REPORT

A 71-year-old gentleman was admitted to the Department of Cardiology due to a large pericardial effusion detected at a transthoracic echocardiographic examination performed in the emergency room. The patient had no medical history, while the only clinical manifestations were dyspnea on exertion and lower extremity edema during the preceding 4 months. Clinical examination revealed diminished heart sounds and mild jugular venous distension, without Kussmaul's sign or pulsus paradoxus. ECG showed low QRS voltage, while chest X-ray showed enlarged cardiac silhouette. Chest and abdominal CT-scan revealed no significant pathological findings. Laboratory blood tests showed only mild leukocytosis and moderate elevation of erythrocyte sedimentation rate. Screening tests for tuberculosis were negative. Despite the anti-inflammatory drug therapy, the patient showed no signs of improvement and he gradually developed clinical and echocardiographic signs of tamponade. Pericardiocentesis was performed with almost complete pericardial fluid removal and the patient was able to be discharged from the hospital, hemodynamically stable, under treatment with methylprednisolone. After 6 months the patient was readmitted to Cardiology due to clinical signs and symptoms of right-sided heart failure. New echocardiographic examination showed: i) possible thickening of the pericardium, ii) small pericardial effusion, iii) abnormal motion of the interventricular septum (septal bounce) and

Conflict of Interest: none declared

IDIOPATHIC EFFUSIVE-CONSTRICTIVE PERICARDITIS

ventricular interdependence during the respiratory cycle iv) dilated inferior vena cava (IVC) without respiratory variation, v) mitral inflow Doppler morphology indicating abnormal left ventricular diastolic filling patterns, but with increased mitral inflow propagation velocity (>100 cm/s)(Fig. 1 and 2). Cardiac magnetic resonance imaging (MRI) revealed diffuse thickening of the pericardium (Fig. 3).

Despite medical treatment and the disappearance of the effusion, there was no significant improvement in patient's condition. Pericardiectomy was finally recommended but the patient refused it.

DISCUSSION

Effusive-constrictive pericarditis represents 1.3% of all causes of pericardial disease – 7% of patients presenting with cardiac tamponade. Effusive-constrictive pericarditis is a condition of tense pericardial effusion in the presence of visceral pericardial constriction. The hallmark of this entity is the continued elevation of right atrial pressure after the aspiration of pericardial fluid and restoration of intrapericar-

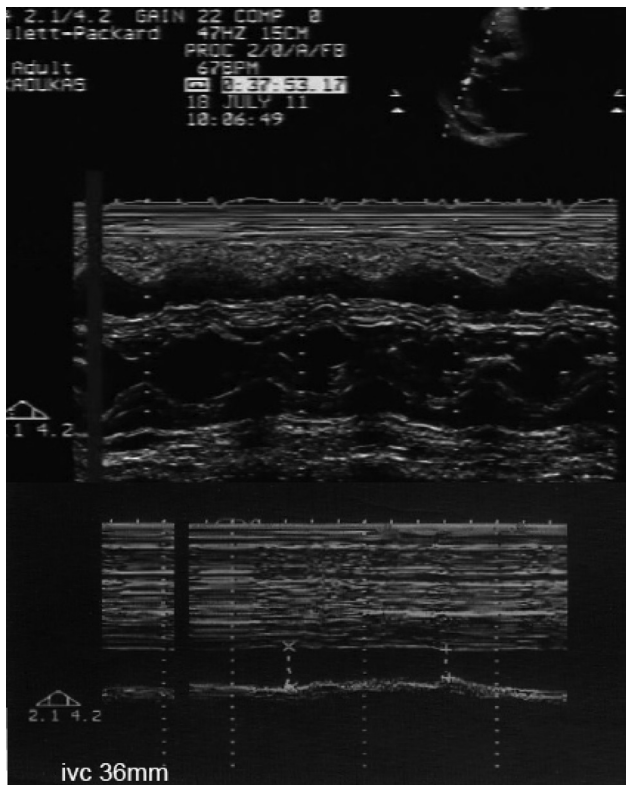


FIGURE 1. Ventricular interdependence during the respiratory cycle and dilated inferior vena cava (IVC) without respiratory variation.

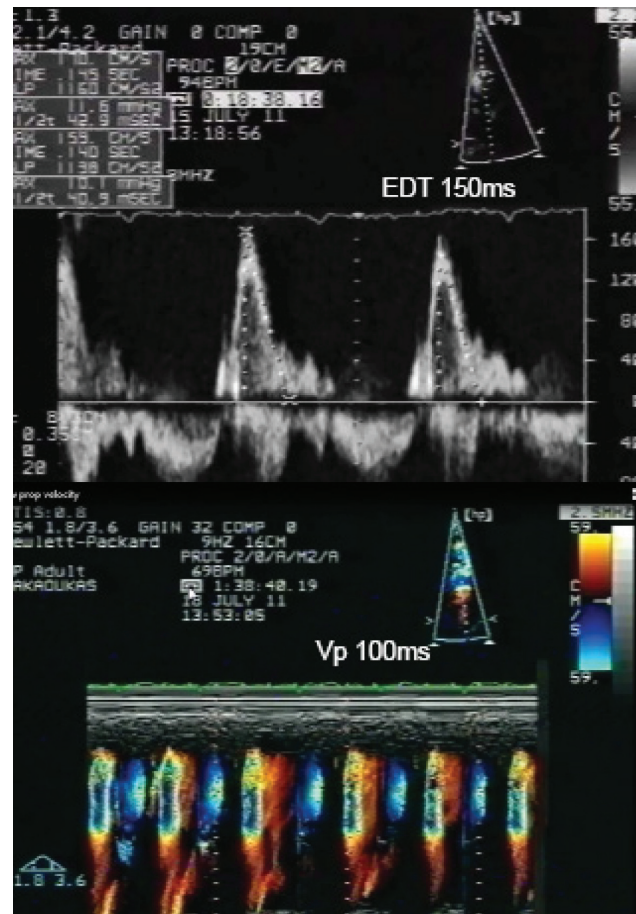


FIGURE 2. Mitral inflow Doppler shows a restrictive pattern and increased mitral inflow propagation velocity.

dial pressure to zero. The most common causes of effusive-constrictive pericarditis are the same as those of chronic constrictive pericarditis, including idiopathic or presumed viral pericarditis, tuberculosis, neoplastic infiltration of the pericardium and mediastinal radiation.² Although effusive-constrictive pericarditis can be suspected on clinical grounds, the diagnosis traditionally is made invasively by recording right heart and intrapericardial pressures both before and after pericardiocentesis. After pericardiocentesis there is persistent elevation and equalization of right atrial and right and left ventricular diastolic pressures. Surgery or autopsy of affected patients exhibit extensive thickening of both the visceral and parietal pericardium with adhesions between them. Surgical removal of only the parietal pericardium is ineffective when visceral pericardial constriction is also present. Visceral and parietal pericardial stripping is an extensive procedure with significant morbidity and mortality but it is widely considered as the only effective treatment. The combined death rate across the studies is 22%.¹ Fortunately, recent studies suggest that

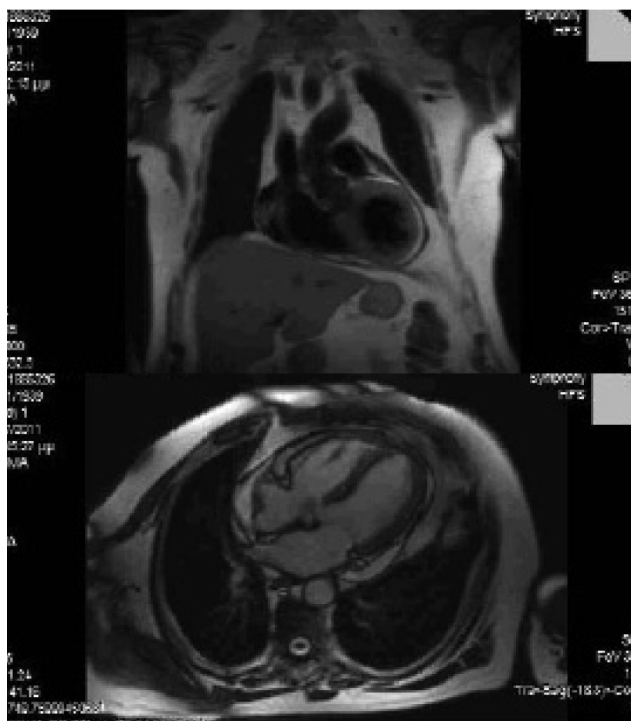


FIGURE 3. Cardiac magnetic resonance imaging (MRI) shows pericardial thickness of greater than 4 mm, which is considered evidence of constrictive pericarditis in the appropriate clinical setting.

up to 10% of constriction may be reversible.³

The present case is a typical case of effusive-constrictive pericarditis which underlines the fact that diagnosis can be made based on clinical, echocardiographic and cardiac MRI findings, not requiring necessarily cardiac catheterization.⁴⁻⁸ Nowadays, it is well known that echocardiography and MRI (with or without CT) can confirm the diagnosis of constrictive pericarditis as well as effusive-constrictive pericarditis.⁹ The latter can be the early stage of constrictive pericarditis. It should be noted that while echocardiography can show the consequences of the constriction on cardiac chambers and pressures, it has a limitation in the accurate assessment of the pericardial thickness.

Cardiac magnetic resonance imaging provides excellent visualization of the pericardium. Additionally, MRI provides assessment of pericardial thickening, IVC diameter, presence or absence of pericardial or pleural effusion, pericardial edema, pericardial enhancement and septal “bounce”. The presence of delayed pericardial hyper-enhancement on MRI is common in patients with constrictive pericarditis and its presence is associated with histological features of organizing pericarditis, which may be the target for future focused pharmacological interventions. Patients with constrictive pericarditis without delayed pericardial hyper-enhancement have more pericardial fibrosis and calcification, as well as lesser degrees of pericardial thickening.⁶⁻⁹

REFERENCES

1. Ntsekhe M, Shey Wiysonge C, Commerford PJ, Mayosi BM. The prevalence and outcome of effusive constrictive pericarditis: a systematic review of the literature. *Cardiovasc J Afr* 2012; 22:1-5.
2. Spodick DH, Kumar S. Subacute constrictive pericarditis with cardiac tamponade. *Dis Chest* 1968;54:62-66.
3. Garg R, Singh A, Chockalingam A. Effusive constrictive pericarditis. *Congest Heart Fail* 2009;15:199-201.
4. Hancock EW. Subacute effusive-constrictive pericarditis. *Circulation* 1971; 43:183-192.
5. Cameron J, Oesterle SN, Baldwin JC, Hancock EW. The etiologic spectrum of constrictive pericarditis. *Am Heart J* 1987; 113:354-360.
6. Permanyer-Miralda G, Sagristu-Sauleda J, Soler-Soler J. Primary acute pericardial disease: a prospective series of 231 consecutive patients. *Am J Cardiol* 1985; 56:623-630.
7. Service of Cardiology, Hospital General Vall D'Hebron. Protocol for the diagnosis and management of pericardial diseases. In: Soler-Soler J, Permanyer-Miralda G, Sagristu-Sauleda J, eds. *Pericardial disease: new insights and old dilemmas*. Vol. 108 of *Developments in Cardiovascular Medicine*. Dordrecht, the Netherlands: Kluwer Academic, 1990: pp. 217-222.
8. Fowler N, Bove KE, Dunbar S, Meyer R. Fatigue, dyspnea, and abdominal swelling in a 13-year-old boy. *Am Heart J* 1978; 96:533-542.
9. Almeida AR, Lopes LR, Cotrim C, et al. Effusive-constrictive pericarditis: the role of noninvasive imaging. *Rev Port Cardiol* 2011; 30:433-443.