

**VIDEO SESSION - CASE REPORT**

## Adenosine for Unmasking Latent Pre-Excitation: an Unpleasant Surprise

Georgios Servos, MD, Georgios Almpanis, MD,  
Pantelis Papathanassiou, MD, Dimitrios Dimopoulos, MD,  
Maria Militsopoulou, MD, Persefoni Koutsogiannou, MD,  
Andreas Mazarakis, MD, PhD

### CASE REPORT

*First Cardiology Department of Agios  
Andreas General Hospital of Patras,  
Patras, Greece*

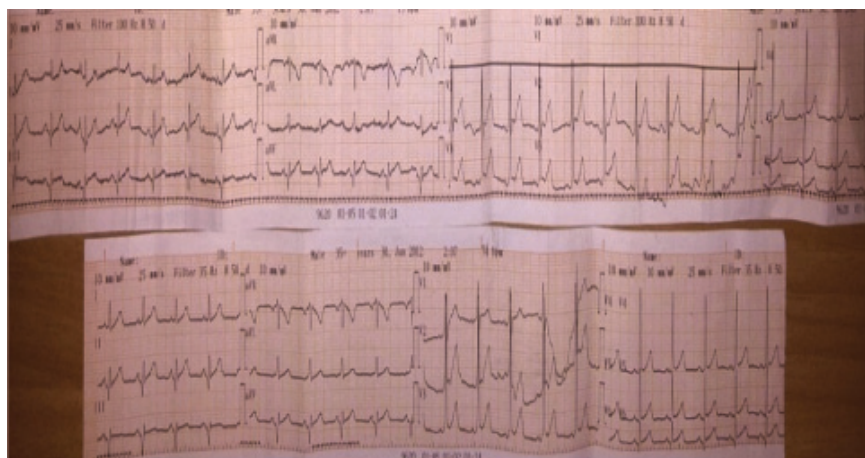
A 33-year-old kickboxing athlete presented to the emergency room (ER) with an intermittent chest pain, which had started an hour earlier. ECG on arrival revealed q wave in the inferior leads, minimal ST elevation in the same leads, without depolarization abnormalities (Fig. 1). The patient was able to recall having been kicked in the chest a few months back during training. While being in the ER the pain recurred. The second ECG had no repolarization changes, but revealed a positive QRS (R>S) in lead V1 (Fig. 2). He had an unremarkable physical examination, negative cardiac enzymes at presentation and after 8 and 24 hours. An echocardiogram revealed no regional wall motion abnormalities, normal right ventricle and normal diastolic function of the left ventricle. There was no pericardial effusion. He denied having syncope or symptoms suggestive of tachycardia in the past and no family history of sudden cardiac death existed.

#### ABBREVIATIONS

ECG = electrocardiogram  
ER = emergency room

#### Corresponding author:

Georgios Almpanis, MD, Agios  
Andreas General Hospital of Patras,  
Patras, Greece;  
E-mail galmpan@gmail.com



**FIGURE 1.** In the first recorded ECG V1 lead is absent for technical reasons. The physician interpreted it as sinus rhythm, q wave in the inferior leads, minimal ST elevation in the same leads, without depolarization abnormalities.

**Conflict of Interest:** none declared

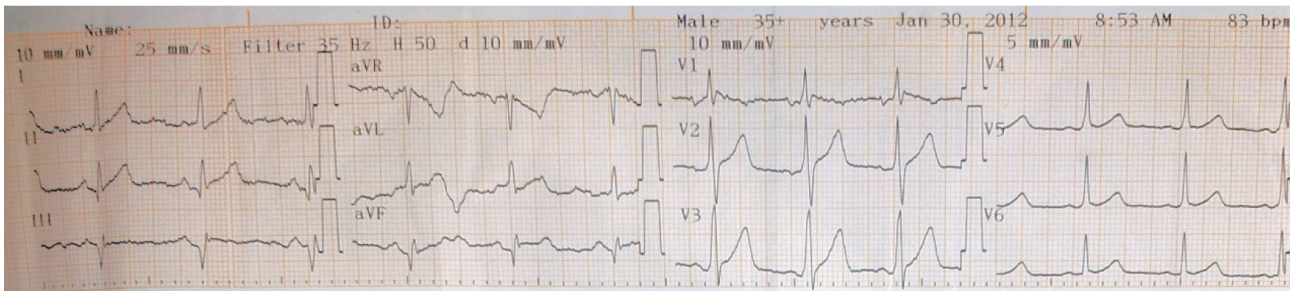


FIGURE 2. In this ECG the slurred QRS upstroke in leads V2 and V3 raise the suspicion of pre-excitation syndrome.

Since ischemia had been ruled out, we decided to proceed to intravenous adenosine test to unmask intermittent pre-excitation. A dose of 12 mg of adenosine was injected as single-bolus followed by rapid saline flush (Fig. 3). Adenosine not only unmasked pre-excitation but also induced a very fast atrial fibrillation through the accessory pathway that was self-terminated in approximately 22 seconds. Patient remained conscious and asymptomatic during the tachycardia.

period favoring anterograde conduction through an accessory pathway. The adenosine test seems to have good sensitivity for unmasking pre-excitation (76-100% in small series).<sup>1,2</sup> When using adenosine in narrow-complex tachycardia to restore normal sinus rhythm, a 12%-15% incidence of conversion to atrial fibrillation has been reported.<sup>3,4</sup> It is not known though what the incidence of atrial fibrillation is when administrating adenosine while in sinus rhythm.

The patient was prescribed propafenone 150 mg tid and nebivolol 5 mg qd. He had an exercise stress test a few days later achieving 85% of target heart rate. No evidence of pre-excitation was noted before, during the test and at peak of exercise (Fig. 4). Although the absence of pre-excitation during

## DISCUSSION

Adenosine shortens the atrioventricular node refractory

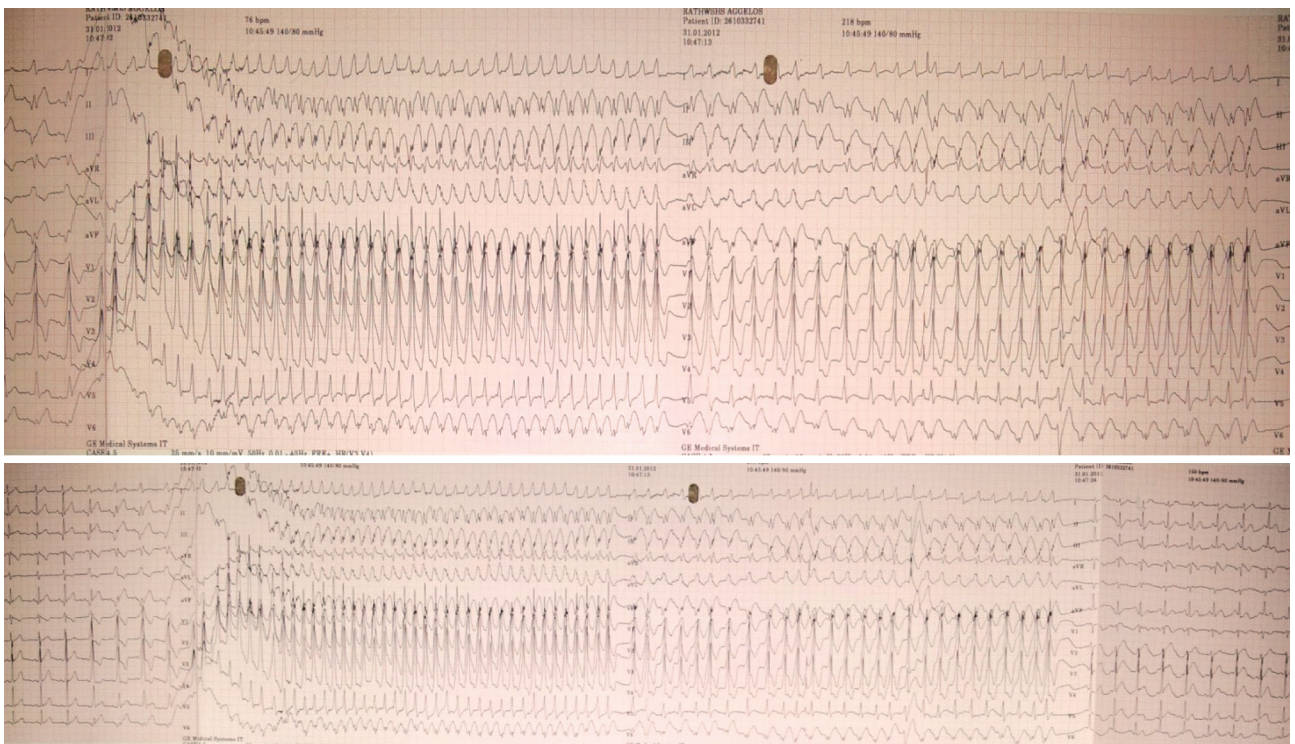


FIGURE 3. ECG after infusion of 12 mg of adenosine. A very fast wide-QRS irregular tachyarrhythmia developed. See text for discussion.

ADENOSINE FOR UNMASKING LATENT PRE-EXCITATION: AN UNPLEASANT SURPRISE

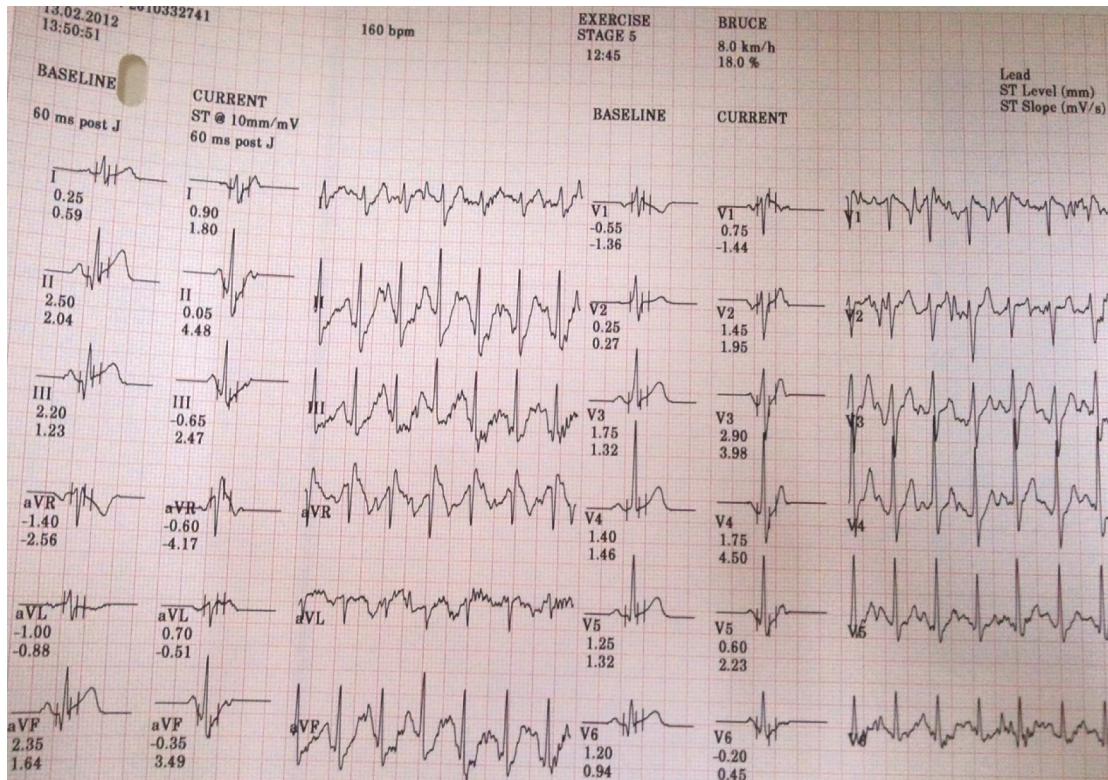


FIGURE 4. ECG at peak exercise after stress test using the Bruce protocol.

the stress test is a good prognostic sign for these patients, indicating a long refractory period of the accessory pathway, the risk of fast atrial fibrillation provoked by adenosine infusion prompted us to refer him for an electrophysiology study and catheter ablation.

REFERENCES

- Garratt CJ, Antoniou A, Griffith MJ, Ward DE, Camm AJ. Use of intravenous adenosine in sinus rhythm as a diagnostic test for latent preexcitation syndrome. *Am J Cardiol* 1990; 65:868-873.
- Belhassen B, Fish R, Viskin S, Glick A, Glikson M, Eldar M. Adenosine-5'-triphosphate test for the noninvasive diagnosis of concealed accessory pathway. *J Am Coll Cardiol* 2000; 36:803-810.
- Strickberger SA, Man KC, Daoud EG, et al. Adenosine-induced atrial arrhythmia: a prospective analysis. *Ann Intern Med* 1997; 127:417-422.
- Blomström-Lundqvist C, Scheinman MM, Aliot EM, et al; ACC; AHA Task Force on Practice Guidelines; ESC Committee for Practice Guidelines. Writing Committee to Develop Guidelines for the Management of Patients With Supraventricular Arrhythmias. ACC/AHA/ESC guidelines for the management of patients with supraventricular arrhythmias-executive summary: a report of the ACC/AHA Task Force on Practice Guidelines and the ESC Committee for Practice Guidelines (Writing Committee to Develop Guidelines for the Management of Patients With Supraventricular Arrhythmias). *Circulation* 2003; 108:1871-1909.