

TECHNIQUES

# Technique of Transcatheter Aortic Valve Implantation

Konstantinos Kalogeras, MD,  
Manolis Vavuranakis, MD, PhD, FACC, FESC, FSCAI

First Department of Cardiology,  
Hippokraton Hospital, Medical  
School, National & Kapodistrian  
University of Athens, Greece

**KEY WORDS:** aortic stenosis; aortic valve replacement; transcatheter aortic valve implantation (TAVI); aortic balloon valvuloplasty

**ABBREVIATIONS**

AS = aortic stenosis  
AVR = aortic valve replacement  
MSCT = multi slice computed tomography  
PCI = percutaneous coronary intervention  
TAVI = transcatheter (transcatheter) aortic valve implantation  
TEE = transesophageal echocardiogram  
VARC = Valve Academic Research Consortium

*Correspondence to:*

Manolis Vavuranakis, MD, Assistant Professor, 13 Astypaleas str., Anoixi, Attiki-14569, Greece;  
Tel: +30-210-2088286,  
Fax: +30-210-7485039 /  
E-mail: vavouran@otenet.gr

*Manuscript received January 25, 2012;  
Revised manuscript received March 11, 2012; Accepted March 16, 2012*

**ABSTRACT**

Transcatheter aortic valve implantation (TAVI) has emerged recently as an accepted treatment option for high-risk patients with symptomatic severe aortic stenosis, who are poor surgical candidates. Increasing numbers of successful TAVI procedures have already been performed, with encouraging short- and mid-term results, while the first randomized double blind trials have already been published confirming efficacy of the procedure and a satisfactory outcome. Thus, TAVI has emerged as a very promising alternative to surgical aortic valve replacement over the recent years. In this brief overview, the patient selection process and the technique of TAVI are described together with some important clinical data.

**INTRODUCTION**

Aortic stenosis is the most common valvular abnormality in the western world.<sup>1</sup> Transcatheter aortic valve implantation (TAVI) has emerged recently as an accepted treatment option for high-risk patients with symptomatic severe aortic stenosis (AS), for whom conventional surgical replacement has been previously denied.<sup>2-4</sup> During the last few years, increasing numbers of successful TAVI procedures have been performed, with encouraging short- and mid-term results, while the first randomized double blind trials have already been published enhancing the initial enthusiasm.<sup>5-7</sup>

With regards to the technical aspect, TAVI is currently performed with use of two commercially available prosthetic valves, the CoreValve (Medtronic, Inc.) and the SAPIEN (Edwards Life Sciences, Inc.), both of which can be introduced transfemorally (Fig. 1). Furthermore, the former may potentially be introduced through a subclavian artery<sup>8,9</sup> or more recently via a transaortic route,<sup>10</sup> while the latter can be introduced transapically.<sup>11</sup> Meanwhile, the surgical involvement during the procedure has been avoided with the use of 18F sheaths, converting TAVI into a truly percutaneous method and permitting the procedure performance even without general anesthesia.<sup>12</sup>

**PATIENT SELECTION/ SCREENING PROCESS**

Patients who suffer from severe, symptomatic aortic stenosis are considered as

**Acknowledgment of financial support:** none; **Conflict of Interest:** none declared



FIGURE 1. The two commercially available prosthetic valves: CoreValve (Medtronic, Inc.) and SAPIEN (Edwards Life Sciences, Inc.).

TAVI candidates if the risk for surgical aortic valve replacement is high (logistics Euroscore >20%) or diagnosed as ‘inoperable’, e.g. due to liver cirrhosis, respiratory insufficiency, hostile thorax, frailty, or porcelain aorta. All patients undergo an intensive screening process before the implantation, including a thorough echocardiography study, an angiography of the aorta, the coronary arteries and the arteries of the lower extremities, while finally a multi slice computed tomography (MSCT) angiography is conducted (Fig. 2).<sup>12</sup> Importantly, the “Heart Team”, including cardiologists, cardiac surgeons and anesthesiologists, specialized in TAVI indications and procedure, reach consensus whether the candidate patient is suitable to undergo the intervention.

#### TAVI PROCEDURE

Historically, the first percutaneous transcatheter implantation of an aortic valve was conducted with an antegrade approach through the right femoral vein and after transseptal catheterization. Using a 24F sheath, the prosthetic device was inflated within the diseased stenotic aortic valve after performing balloon valvuloplasty.<sup>4</sup>

The TAVI procedure with use of the CoreValve prosthesis is carried out via the femoral or subclavian artery, through an

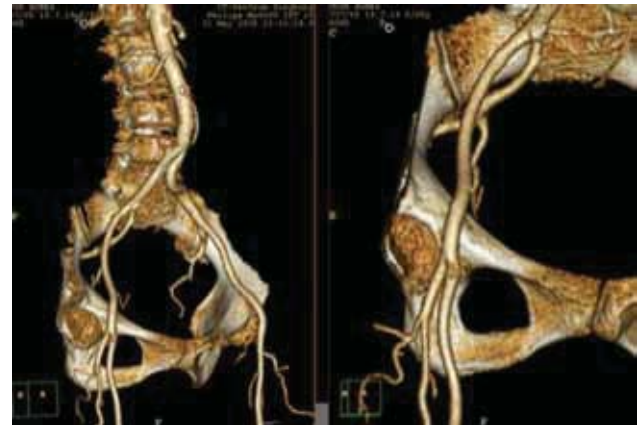

FIGURE 2. 3D reconstructed image of iliofemoral arterial tree, conducted with multi slice computed tomography (MSCT), used for patient screening.

18F sheath, with the puncture guided by a crossover technique (in case of femoral access), or surgical artery cut-down (in case of subclavian access). The percutaneous closure is achieved using a preloaded Prostar XL suture device (Abbott Vascular, Abbott Park, IL).<sup>13</sup> Prior to implantation of the prosthesis, aortic angiography is conducted and subsequently, balloon valvuloplasty is performed under rapid ventricular pacing. The whole procedure is under continuous hemodynamic and arterial blood gas (oximetry) monitoring.

The CoreValve prosthesis is then advanced retrogradely over a stiff guidewire and deployed within the aortic annulus. A 26 mm and 29 mm bioprosthesis is implanted for aortic annulus diameter of 20-23mm and 24-27mm, respectively. Recently, a 31 mm CoreValve prosthesis has been introduced for aortic annulus of 27-29 mm. Deployment of the prosthetic valve consists of three stages. During the first stage, the operator has full control of the valve expansion, without being forced to rapidly deploy the valve, since the valve is being deployed under the patient’s native rhythm. During the second stage, the partially deployed prosthesis obstructs the aortic valve flow, blood pressure is compromised and the operator performs deployment in an uninterrupted mode until blood pressure returns to baseline. The third step is then completed, without

TABLE 1. Main Characteristics of the two Commercially Available Transcatheter Aortic Valve Devices.

	Approach	Sheath size	Expansion	Valve size	Balloon valvuloplasty
CoreValve (Medtronic, Inc.)	Transfemoral-subclavian-transaortic	18Fr	Self-expanded	26 mm-29 mm-31 mm	Yes
SAPIEN (Edwards Life Sciences, Inc.)	Transfemoral-transaortic-transapical	18Fr	Balloon-expanded	23 mm-26 mm	Yes

any need for hurry, since sufficient blood flow is maintained through the deployed valve (Fig. 3).<sup>12</sup> Finally, hemodynamic outcomes, proper prosthesis placement, potential aortic valve regurgitation or vascular complications at the puncture site, are assessed serially by aortograms and managed properly.

The TAVI procedure using the Edwards prosthesis has many similarities with the procedure of the CoreValve prosthesis. Valve implantation is also preceded by balloon valvuloplasty, but contrary to the self-expanding prosthesis of the CoreValve, the Edwards prosthesis is expanded at the aortic annulus site using a balloon under rapid right ventricular pacing.<sup>14</sup> Nevertheless, apart from a transfemoral approach, the Edwards valve can also be implanted through a mini-thoracotomy in the fifth or possibly sixth intercostal space via a transapical approach, offering an extra therapeutic opportunity to patients with severe stenoses throughout their arterial tree.<sup>15</sup>

Alternative approaches have been proposed and used in individualized cases but their implementation is currently limited. Such techniques, include transaortic or transcatheter approach for valve implantation.<sup>10</sup>

---

**COMPLICATIONS AND MANAGEMENT**

---

Transcatheter aortic valve implantation is a technically demanding procedure, which sometimes may be accompanied by simple or severe complications. Hemodynamic complications, such as aortic regurgitation or hemodynamic collapse due to malignant arrhythmias can be managed with post-implantation balloon inflation in the first case<sup>16</sup> or bioprosthesis deployment

without angiographic injection guidance (using the new Accutracc system) in the latter case.<sup>17</sup>

Several repositioning techniques have been evolved in order to deal with non-proper site deployment of the valve. The ‘Snare’ technique is a ‘bail-out’ method applied when the prosthesis is implanted too low.<sup>18</sup> In addition, the “Removing and Repositioning” technique can be used in the case of too-high initial positioning of the prosthesis, by retrieving the semi-deployed valve out of the body, inspecting and reinserting it for a successful implantation.<sup>18</sup> Furthermore, the ‘valve in valve’ technique can be performed, using a second prosthesis within the first one, in cases where the initial valve has not been implanted properly.<sup>18</sup>

Vascular complications at the access site represent another common group of TAVI complications. Rupture, dissection or pseudoaneurysms of the access vessel, despite the use of the closure device, are managed with balloon inflation or covered stent implantation at the site. It has been shown that extensive calcification, sheath to femoral artery ratio, and vessel tortuosity and angulation are factors contributing to major vascular complications.<sup>19</sup> Recently the Valve Academic Research Consortium (VARC) has established criteria and definitions for TAVI not only regarding vascular complications but many of the procedural aspects.<sup>20</sup>

Conduction disorders following TAVI are a known, common complication resulting in permanent pacemaker implantation. It seems that implantation depth and proximity of aortic valve to conduction system facilitate the development of conduction disorders (Fig. 4).<sup>21</sup> Contrary to surgical aortic valve replacement (AVR) (3.2-8.5%),<sup>22</sup> the prevalence of

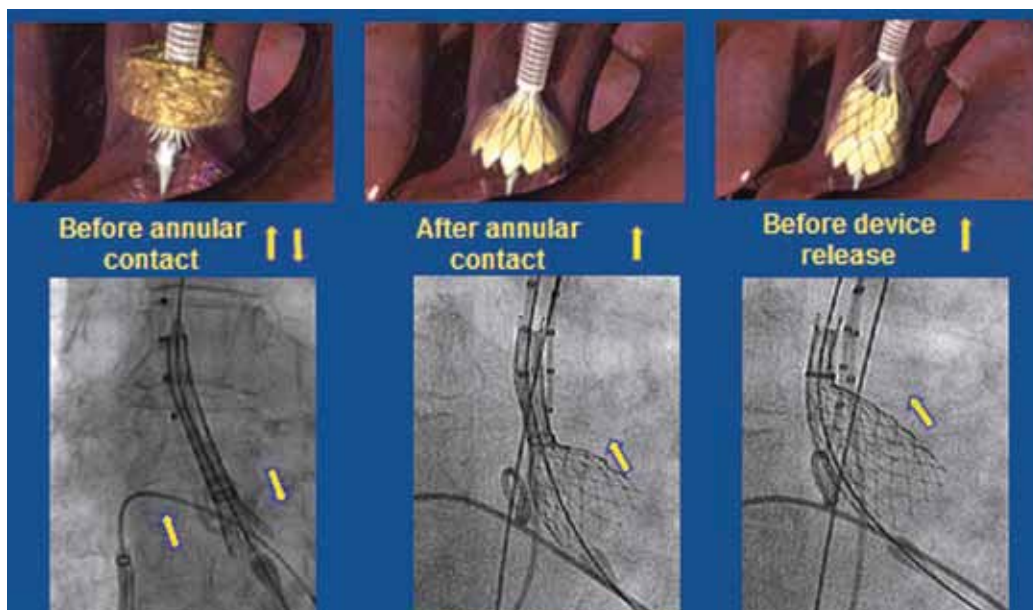


FIGURE 3. The three stages of CoreValve deployment.

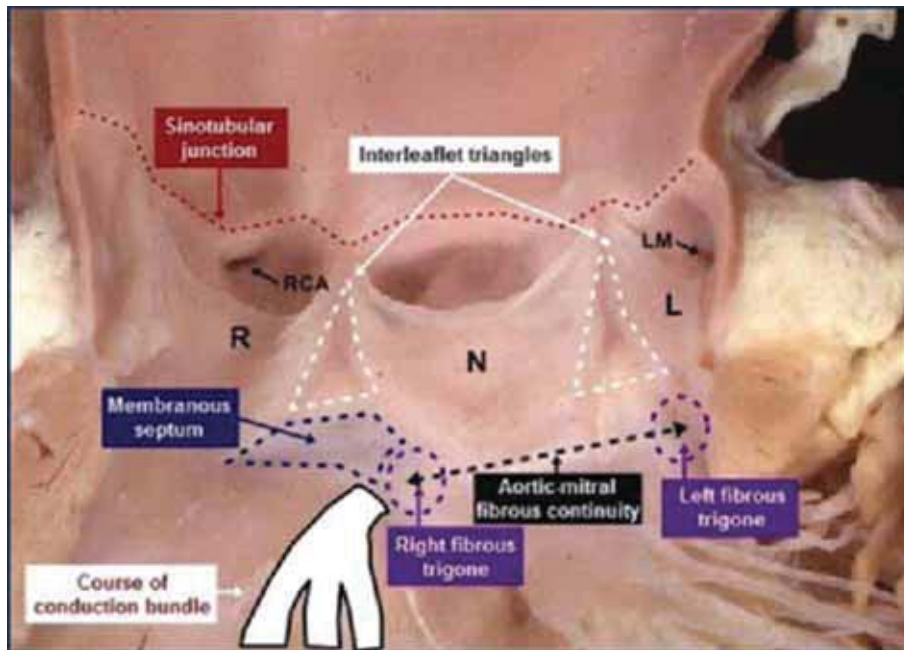


FIGURE 4. Native aortic valve and conduction system.

permanent pacemaker implantation after TAVI ranges from 12-35% in a series of studies.<sup>23,24</sup> The conduction disorders frequency is significantly higher with the CoreValve than the Edwards prosthesis, resulting in approximately 21% of permanent pacemaker implantation and a 6% respectively. That difference can be explained by the self-expandable character of the CoreValve device and its longer size expanded in the left ventricle, leading to higher pressures applied to the vicinal native conduction system. A higher prosthesis implantation may potentially prevent the development of conduction disorders.

In order to diminish the complication percentages, the use of transesophageal echocardiography (TEE) has been proposed and used by many operators. Thus, it has been used for the measurement of the aortic annulus size preoperatively,<sup>25</sup> while real-time 3-D TEE has been applied in procedure guidance in percutaneous and transapical approach.<sup>26,27</sup> Moreover, studies have been conducted using TEE, regarding the change of aortic annulus dimensions and geometries after TAVI.<sup>28</sup> However, its use has not been routinely implemented.

Left main occlusion or obstruction is a rare but serious complication reported during or after TAVI, conducted by transcatheter or transapical approach.<sup>29,30</sup> This dreadful complication is managed with an emergency percutaneous coronary intervention (PCI) and stent deployment in the left main ostium.

---

#### RANDOMIZED TRIALS/FUTURE PROSPECTS

---

A variety of studies have shown the efficacy of the method compared with the conventional treatment. The PARTNER trial was the first randomized trial comparing TAVI (Edwards) with standard therapy (cohort B) and surgical AVR (cohort A). Regarding the first arm, it was shown that TAVI results in significant reduction of mortality compared with standard therapy (30.7% vs. 50.7%;  $p < 0.001$ ) and reduction of death or hospitalization (42.5% vs. 71.6%,  $p < 0.001$ ).<sup>5</sup> Concerning the second arm, it was shown that TAVI was non-inferior for mortality compared with surgical AVR (24.2% vs. 26.8%;  $p$  for noninferiority = 0.001) and 30-day mortality (3.4% vs. 6.5%,  $p = 0.07$ ) (Fig. 5).<sup>6</sup>

Undoubtedly, TAVI has emerged as a very promising alternative to surgical AVR over the recent years. Patients, who were considered to be left untreated or undergo surgical replacement with high surgical risk, are now offered an alternative, secure and non-inferior treatment. However, further studies are required to evaluate the long-term durability of the prosthetic valve, so that the appropriate patient population for this procedure may be expanded.

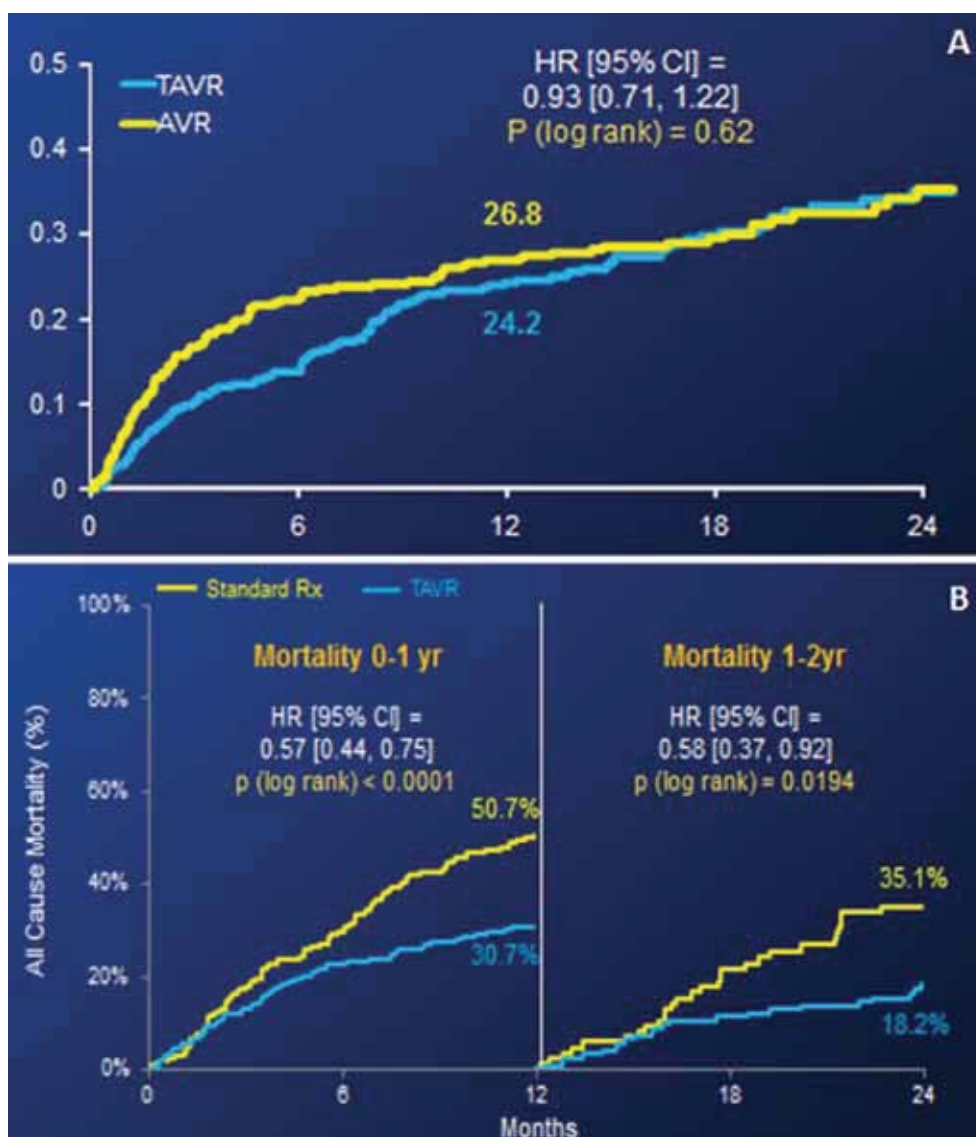


FIGURE 5. PARTNER trial arms: A) cohort A, TAVI non-inferiority for mortality compared with surgical AVR in 2-years follow-up, B) cohort B, significant reduction of mortality with TAVI compared with standard therapy at 2-years of follow-up. AVR = aortic valve replacement; TAVR = transcatheter aortic valve replacement.

REFERENCES

1. Iung B, Baron G, Butchart EG, et al. A prospective survey of patients with valvular heart disease in Europe: The Euro Heart Survey on Valvular Heart Disease. *Eur Heart J* 2003;24:1231-1243.
2. Vahanian A, Alfieri O, Al-Attar N, et al. Transcatheter valve implantation for patients with aortic stenosis: a position statement from the European association of cardio-thoracic surgery (EACTS) and the European Society of Cardiology (ESC), in collaboration with the European Association of Percutaneous Cardiovascular Interventions (EAPCI). *EuroIntervention* 2008;4:193-199.
3. Grube E, Schuler G, Buellfeld L, et al. Percutaneous aortic valve replacement for severe aortic stenosis in high-risk patients using the second- and current third-generation self-expanding CoreValve prosthesis: device success and 30-day clinical outcome. *J Am Coll Cardiol* 2007;50:69-76.
4. Cribier A, Eltchaninoff H, Bash A, et al. Percutaneous transcatheter implantation of an aortic valve prosthesis for calcific aortic stenosis: first human case description. *Circulation* 2002;106:3006-3008.
5. Leon MB, Smith CR, Mack M, et al. Transcatheter aortic-valve implantation for aortic stenosis in patients who cannot undergo surgery. *N Engl J Med* 2010;363:1597-1607.

6. Smith CR, Leon MB, Mack MJ, et al. Transcatheter versus surgical aortic-valve replacement in high-risk patients. *N Engl J Med* 2011;364:2187-2198.
7. Cribier A, Eltchaninoff H, Tron C, et al. Early experience with percutaneous transcatheter implantation of heart valve prosthesis for the treatment of end-stage inoperable patients with calcific aortic stenosis. *J Am Coll Cardiol* 2004;43:698-703.
8. Vavuranakis M, Vrachatis DA, Toutouzas K, Economopoulos G, Kalogeras KI, Stefanadis C. Successful percutaneous aortic valve implantation via a stenotic left subclavian artery access. *Heart Vessels* 2010;25:359-362.
9. Vavuranakis M, Vrachatis DA, Filis K, Stefanadis C. Transcatheter aortic-valve implantation by the subclavian approach complicated with vessel dissection and transient left-arm paralysis. *Eur J Cardiothorac Surg* 2011;39:127-129.
10. Latsios G, Gerckens U, Grube E. Transaortic transcatheter aortic valve implantation: a novel approach for the truly “no-access option” patients. *Catheter Cardiovasc Interv* 2010;75:1129-1136.
11. Spargias K, Manginas A, Pavlides G, et al. Transcatheter aortic valve implantation: first Greek experience. *Hellenic J Cardiol* 2008;49:397-407.
12. Vavuranakis M, Voudris V, Vrachatis DA, et al. Transcatheter aortic valve implantation, patient selection process and procedure: two centres’ experience of the intervention without general anaesthesia. *Hellenic J Cardiol* 2010;51:492-500.
13. de Jaegere P, van Dijk LC, Laborde JC, et al. True percutaneous implantation of the CoreValve aortic valve prosthesis by the combined use of ultrasound guided vascular access, Prostar(R) XL and the TandemHeart(R). *EuroIntervention* 2007;2:500-505.
14. Cribier A, Litzler PY, Eltchaninoff H, et al. Technique of transcatheter aortic valve implantation with the Edwards-Sapien heart valve using the transfemoral approach. *Herz* 2009;34:347-356.
15. Walther T, Dewey T, Borger MA, et al. Transapical aortic valve implantation: step by step. *Ann Thorac Surg* 2009;87:276-283.
16. Hildick-Smith D, Redwood S, Mullen M, et al. Complications of transcatheter aortic valve implantation: avoidance and management. *EuroIntervention* 2011;7:621-628.
17. Vavuranakis M, Kalogeras KI, Vrachatis DA, Kariori MG, Moldovan C, Stefanadis C. CoreValve deployment during cardiopulmonary resuscitation without angiographic injections guidance. An additional capability of Accutrak system? *Int J Cardiol* 2011 Nov 9. [Epub ahead of print].
18. Vavouranakis M, Vrachatis DA, Toutouzas KP, Chrysohoou C, Stefanadis C. “Bail out” procedures for malpositioning of aortic valve prosthesis (CoreValve). *Int J Cardiol* 2010;145:154-155.
19. Hayashida K, Lefevre T, Chevalier B, et al. Transfemoral aortic valve implantation new criteria to predict vascular complications. *JACC Cardiovasc Interv* 2011;4:851-858.
20. Leon MB, Piazza N, Nikolsky E, et al. Standardized endpoint definitions for transcatheter aortic valve implantation clinical trials: a consensus report from the Valve Academic Research Consortium. *Eur Heart J* 2011;32:205-217.
21. Piazza N, Onuma Y, Jesserun E, et al. Early and persistent intraventricular conduction abnormalities and requirements for pacemaking after percutaneous replacement of the aortic valve. *JACC Cardiovasc Interv* 2008;1:310-316.
22. Ferreira ND, Caeiro D, Adao L, et al. Incidence and predictors of permanent pacemaker requirement after transcatheter aortic valve implantation with a self-expanding bioprosthesis. *Pacing Clin Electrophysiol* 2010;33:1364-1372.
23. Latsios G, Gerckens U, Buellesfeld L, et al. “Device landing zone” calcification, assessed by MSCT, as a predictive factor for pacemaker implantation after TAVI. *Catheter Cardiovasc Interv* 2010;76:431-439.
24. Jilaihawi H, Chin D, Vasa-Nicotera M, et al. Predictors for permanent pacemaker requirement after transcatheter aortic valve implantation with the CoreValve bioprosthesis. *Am Heart J* 2009;157:860-866.
25. Janosi RA, Kahlert P, Plicht B, et al. Measurement of the aortic annulus size by real-time three-dimensional transesophageal echocardiography. *Minim Invasive Ther Allied Technol* 2011;20:85-94.
26. Bagur R, Rodes-Cabau J, Doyle D, et al. Usefulness of TEE as the primary imaging technique to guide transcatheter transapical aortic valve implantation. *JACC Cardiovasc Imaging* 2011;4:115-124.
27. Janosi RA, Kahlert P, Plicht B, et al. Guidance of percutaneous transcatheter aortic valve implantation by real-time three-dimensional transesophageal echocardiography--A single-center experience. *Minim Invasive Ther Allied Technol* 2009;18:142-148.
28. Ng AC, Delgado V, van der Kleij F, et al. Comparison of aortic root dimensions and geometries before and after transcatheter aortic valve implantation by 2- and 3-dimensional transesophageal echocardiography and multislice computed tomography. *Circ Cardiovasc Imaging* 2010;3:94-102.
29. Crimi G, Passerone G, Rubartelli P. Trans-apical aortic valve implantation complicated by left main occlusion. *Catheter Cardiovasc Interv* 2011;78:656-659.
30. Stabile E, Sorropago G, Cioppa A, et al. Acute left main obstructions following TAVI. *EuroIntervention* 2010;6:100-105.