

CASE REPORT

Pseudomyxoma Peritonei Presenting as Acute Appendicitis: Clinical and Imaging Findings

Georgios P. Kachrimanis,¹ MD, Demosthenes D. Cokkinos,¹ MD, PhD, Irene E. Kyratzi,¹ MD, MSc, Efstathios Tsekouras,² MD, Ploutarchos N. Piperopoulos*, MD, PhD

ABSTRACT

A 30-year old man presented with symptoms and signs of acute appendicitis. Abdominal imaging via ultrasound and computed tomography detected a mass in the right iliac fossa. Exploratory laparotomy revealed an appendiceal mass and gelatinous peritoneal fluid, while histopathology confirmed the diagnosis of pseudomyxoma peritonei arising from a mucocele of the appendix and attributed to an appendiceal cystadenocarcinoma. The clinical and imaging findings of this rare case are herein presented.

¹Department of Radiology &
²Department of CT-MRI,
“Evangelismos” General Hospital,
Athens, Greece

KEY WORDS: *pseudomyxoma peritonei; appendix; mucocele; ascites; mucinous neoplasm*

INTRODUCTION

Pseudomyxoma peritonei is an uncommon clinical condition, characterized by accumulation of thick, gelatinous material in the peritoneal cavity.¹ Its estimated incidence is 1-2 per million per year, predominantly affecting women (2-3:1 compared to men).² Although it constitutes a clinical rather than a histopathological diagnosis,^{1,3} in the majority of cases it is thought to originate from an appendiceal mucinous neoplasm,⁴ forming a mucocele of the appendix, which later perforates or ruptures, disseminating its mucinous contents into the peritoneal cavity.² We herein report a case of pseudomyxoma peritonei describing the clinical and imaging findings.

CASE REPORT

A 30-year old man presented with one-month history of mild epigastric and right iliac fossa pain. Over the preceding two weeks, the pain also radiated to his right shoulder. On physical examination, there was tenderness in the right lower quadrant, but no rebound tenderness. There was mild abdominal distention but no definite mass could be palpated and no apparent shifting dullness could be elicited. Laboratory findings included an elevated C-reactive protein (7.3 mg/dL; normal values <0.3 mg/dL), leukocytosis (white blood cell count of 11,230/μL; normal values 4,000-10,500/μL) and elevated lactic dehydrogenase (371 IU/L; normal values <255 IU/L). Chest

ABBREVIATIONS

CT = computed tomography
MRI = magnetic resonance imaging

*Correspondence to:

Irene Kyratzi, MD,
21-23 Menippou Str,
Cholargos 155 62, Athens, Greece,
Tel.: +30-6973405452,
+30-2121021560
e-mail: ekyratzi@yahoo.com

Manuscript received December 9, 2012; Revised manuscript received and accepted January 31, 2012

Conflict of Interest: none declared

PSEUDOMYXOMA PERITONEI

X-ray revealed a small right pleural effusion. The patient was subsequently scheduled for an abdominal ultrasound and contrast-enhanced computed tomography (CT) examination.

Abdominal ultrasound demonstrated a mass of mixed echogenicity in the right iliac fossa, ascites with solid echogenic components which did not move after changing patient's position (Fig. 1 & 2), as well as free pleural fluid on the right side. Contrast-enhanced CT of the abdomen confirmed a 10 cm right iliac fossa mass containing a few calcifications and mildly enhancing post contrast injection, scalloping of the liver margins, ascites with solid components and right-sided pleural effusion with accompanying atelectasia of the adjacent lung parenchyma (Fig. 3, 4 & 5).

The patient was initially treated surgically with appendectomy and debulking of the peritoneal gelatinous material.

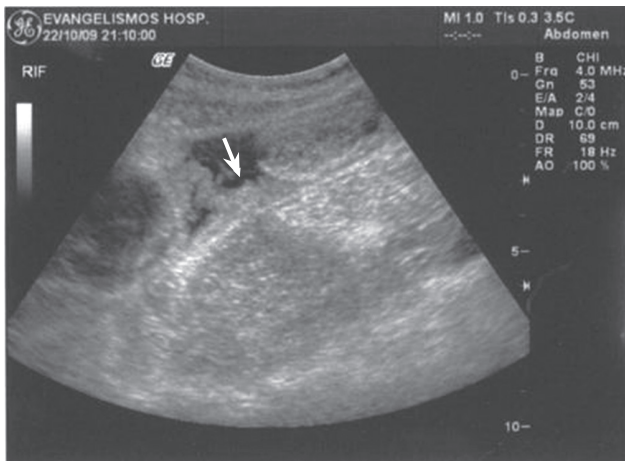


FIGURE 1. Abdominal ultrasound imaging revealed ascites with solid echogenic components (arrow).

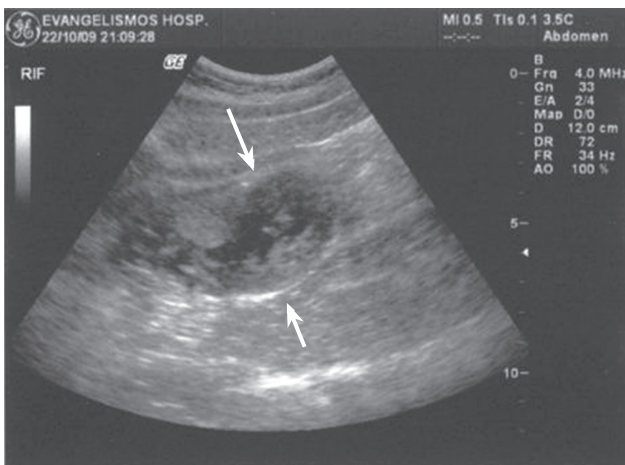


FIGURE 2. Abdominal ultrasound showed a mass of mixed echogenicity in the right iliac fossa (arrows).

Post-surgery histopathology reported pseudomyxoma peritonei, arising from a mucocele of the appendix and attributed to an appendiceal cystadenocarcinoma. After pathological confirmation of the disease, the patient was referred to a spe-

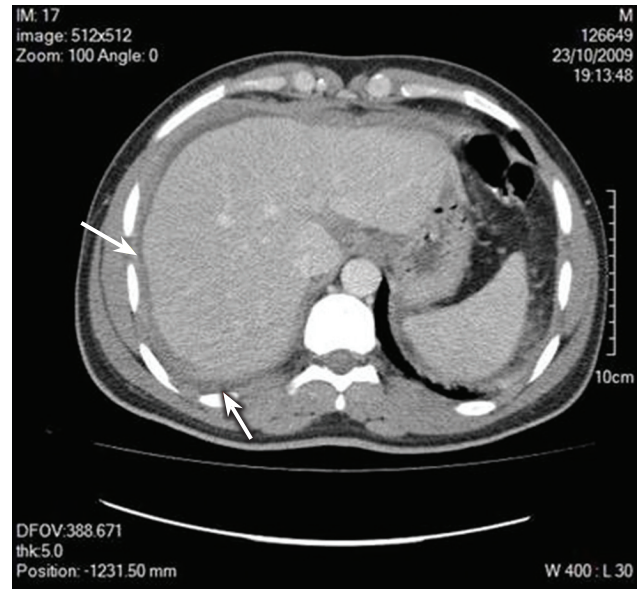


FIGURE 3. Contrast-enhanced abdominal CT showed scalloping of the liver contour (upper arrow), ascites and right-sided pleural effusion with accompanying atelectasia of the adjacent lung parenchyma (lower arrow).

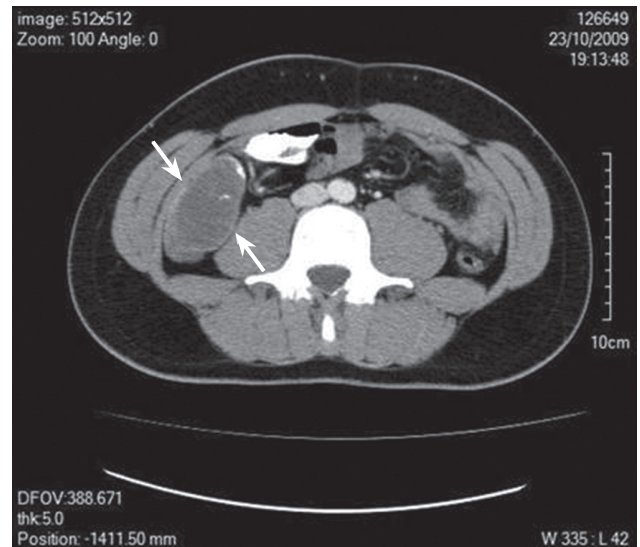

FIGURE 4. Contrast-enhanced abdominal CT revealing a 10-cm right iliac fossa mass (between the two arrows) with a few calcifications, mildly enhancing post contrast injection, displacing adjacent bowel loops.

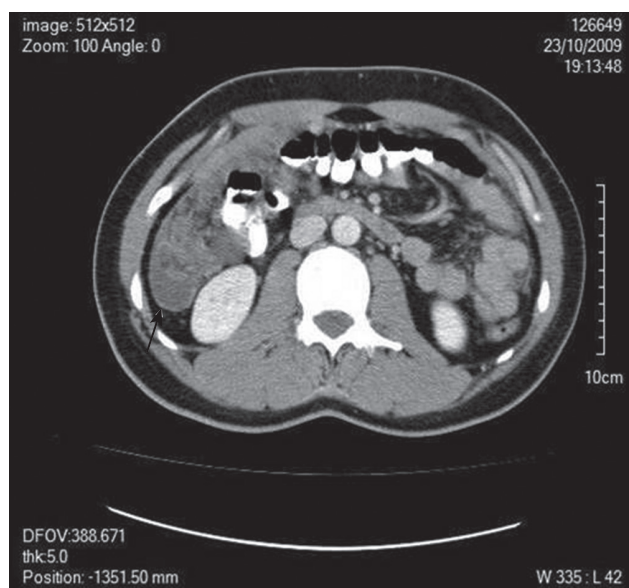


FIGURE 5. Abdominal CT showing ascites with solid components (arrow).

cialized center for further management to include cytoreductive surgery and hyperthermic intraperitoneal chemotherapy.

DISCUSSION

As was the case with this patient's clinical presentation, pseudomyxoma peritonei in early stages presents with vague abdominal pain or localized symptoms manifesting as appendicitis. In more advanced stages it presents with the typical distended "jelly belly", due to ascites and, in some cases, intestinal obstruction, secondary to compression of the bowel from the tumor and ascites.²

Imaging findings reflect the presence of massive ascites with increased opacity throughout the abdomen and poor definition of the borders of intraabdominal organs and the psoas muscles. Occasionally, there is medial displacement of the liver tip (Hellmer sign) or the ascending and descending colon, as well as faint, curvilinear or amorphous calcifications.⁵ Ultrasound features of pseudomyxoma peritonei include ascites with echogenic, immobile elements, reflecting its gelatinous nature. Ascites may contain septa representing mucinous nodules and focal or sheetlike echogenic masses due to involvement of the omentum and parietal peritoneum. Bowel loops are displaced by the surrounding material centrally and posteriorly, often presenting with a characteristic "starburst" appearance.⁶ Characteristic ultrasound and CT findings also include scalloping of the hepatic and splenic margins, caused by adjacent intraperitoneal masses. Mucin within the peritoneal cavity shows low attenuation on CT. However, soft-tissue

attenuation areas may also be seen, representing solid tumor masses, fibrosis or compression of the mesentery. Calcifications, if present, are also evident on CT.⁵

Magnetic resonance imaging (MRI) findings include peritoneal implants of low signal intensity in T1-weighted images, high signal intensity in T2-weighted images (especially in the center), peripheral enhancement after injection of paramagnetic contrast medium, as well as restricted diffusion.⁷ It has been proposed that MRI has an advantage over CT in detecting microcystic lesions, as well as in depicting small bowel obstruction by means of magnetic resonance enteroclysis imaging.^{8,9}

Even though not all the imaging findings of pseudomyxoma peritonei reported in the literature were illustrated in the ultrasound and CT examination of our patient, the presence of ascites with immobile solid components, liver scalloping, peritoneal implantations and peripheral calcifications were all indicative of the disease (Fig. 1-5).

Disseminated adenomucinosis, peritoneal carcinomatosis and peritoneal mesothelioma are the main types of peritoneal surface malignancies, which may present with features of pseudomyxoma peritonei. Adenocarcinoma of the gastrointestinal tract and ovarian neoplasms are other common conditions, which may mimic the clinical presentation, radiological features and operative findings of pseudomyxoma peritonei.⁹

Current treatment of choice includes aggressive cytoreductive surgery, parietal peritonectomy and excision of the involved viscera combined with intraperitoneal chemotherapy with hyperthermia, as well as systemic chemotherapy. This combination is deemed to yield better results in comparison to past treatment of serial surgical debulking.^{2,3,10,11}

Prognosis of pseudomyxoma peritonei depends on the extent of peritoneal seeding¹¹ and the histological grade of the neoplasm.^{2,3,11} Successful treatment in low-grade neoplasms after complete cytoreduction can be as high as 73-80%.^{2,3,11}

In conclusion, pseudomyxoma peritonei is an uncommon entity presenting with atypical clinical symptoms, sometimes mimicking acute appendicitis, as in the present case. Imaging findings can aid in establishing the diagnosis and guiding surgical treatment.

REFERENCES

1. Pai RK, Longacre TA. Appendiceal mucinous tumors and pseudomyxoma peritonei. histologic features, diagnostic problems, and proposed classification. *Adv Anat Pathol* 2005;12:291-311.
2. Smeenk RM, Bruin SC, van Velthuysen ML, Verwaal VJ. Pseudomyxoma peritonei. *Curr Probl Surg* 2008;45:527-575.
3. Smeenk RM, Verwaal VJ, Zoetmulder FAN. Pseudomyxoma peritonei. *Cancer Treat Rev* 2007;33:138-145.
4. Mukherjee A, Parvaiz A, Cecil TD, Moran BJ. Pseudomyxoma peritonei usually originates from the appendix: a review of the evidence. *Eur J Gynaecol Oncol* 2004;25:411-414.
5. Levy AD, Shaw JC, Sobin LH. Secondary tumors and tumorlike

PSEUDOMYXOMA PERITONEI

- lesions of the peritoneal cavity: imaging features with pathologic correlation. *RadioGraphics* 2009; 29:347-373.
6. Hanbidge AE, Lynch D, Wilson SR. US of the peritoneum. *RadioGraphics* 2003; 23:663-685.
 7. Menassa-Moussa L, Tohmt C, Smayra T, Sader-Ghorra C, Aoun N, Ghossain M. Pseudomyxome peritoneal d'origine appendiculaire: diagnostic IRM. *J Radiol* 2008;89:1105-1108.
 8. Low R, Sebrechts C, Barone R, Muller W. Diffusion-weighted MRI of peritoneal tumors: comparison with conventional MRI and surgical and histopathologic findings - a feasibility study. *AJR Am J Roentgenol* 2009; 193:461-470.
 9. Mukherjee A, Moran BJ. Pseudomyxoma peritonei-symptoms, signs and clinical differential diagnosis. *CME J Gynecol Oncol* 2003;8:199-203.
 10. Sugarbaker PH. New standard of care for appendiceal epithelial neoplasms and pseudomyxoma peritonei syndrome? *Lancet Oncol* 2006;7:69-76.
 11. Elias D, Gilly F, Quenet F, Bereder JM, et al; Association Française de Chirurgie. Pseudomyxoma peritonei: a French multicentric study of 301 patients treated with cytoreductive surgery and intraperitoneal chemotherapy. *Eur J Surg Oncol* 2010;36:456-462.