

ORIGINAL ARTICLE

Drainage of Post-Operative Abdominal and Pelvic Abscesses Under the Guidance of Computed Tomography

Demetrios N. Exarhos, MD, Fotini G. Lazarioti, MD,
Eleni Testembasi, MD, Demetrios Chondros, MD

*Department of Computed Tomography
and Magnetic Resonance Imaging,
Evangelismos Hospital, Athens, Greece*

KEY WORDS: *postoperative abscess;
percutaneous drainage; computed
tomography; laparotomy*

ABBREVIATIONS

CT = computed tomography
INR = international normalized ratio
PAD = percutaneous abscess drainage

Correspondence to:

Demetrios Exarhos, MD,
12 Scholiou Str, Ag. Paraskevi, Athens
15342, Greece; Tel.: +30-210-6015227
/ 210-7201366 / 210-7201255;
e-mail: jimexarhos@yahoo.com

*Manuscript received December 12, 2012;
Revised manuscript received January 9,
2012; Accepted January 30, 2012*

ABSTRACT

BACKGROUND: Cross sectional imaging and specifically computed tomography (CT) has become the main radiological modality of detecting post-surgical abdominal collections and abscesses. Percutaneous abscess drainage (PAD) has revolutionized the treatment of abscesses, especially of post-surgical abdominal abscesses over the last 25 years; repeat laparotomy is a rare event due to the fact that the success rate of PAD is very high (90-95%) and complications are few (0-10%).

OBJECTIVE: The aim of the study is to present our experience in the department of computed tomography of the percutaneous drainage of post-operative abdominal and pelvic abscesses.

PATIENTS AND METHODS: During the last two and a half years, 93 post-operative patients were referred to the CT department for drainage of a post-surgical abscess in the abdomen or pelvis at 9-21 days post-operatively due to persistent fever. A total of 95 abscesses were drained; 84 were located in the abdomen and 11 in the pelvis. Abscess diameters ranged between 2 and 12 cm. A percutaneous drainage technique under CT-guidance was employed in all patients; 98 catheters were placed with use of the Seldinger technique. A transgluteal paracoccygeal approach was adopted in 11 patients. Aspiration of an intra-loop abscess was performed in 1 patient. The tilted gantry technique was utilized in 2 cases.

RESULTS: Eighty-nine (95.7%) patients were successfully treated. In 4 (4.3%) patients the abscesses were partially drained, patients were stabilized and subsequently treated via laparotomy. Complications included inflammation of the skin at the entry site in 4 patients, pneumothorax in 1 patient, catheter displacement in 12 patients and misplacement in one patient involving catheter migration into the duodenum. Major complications did not occur.

CONCLUSION: Percutaneous drainage of post-operative abdominal and pelvic abscesses was a safe and effective method of abscess management in our series with a 95.7% success rate and absent major complications. It is currently a widely used procedure, eliminating the need for repeat laparotomy in the majority of patients. Proper catheter management is essential for the successful outcome.

INTRODUCTION

The ability of computed tomography (CT) to provide guidance for catheter placement into the cavity of an abscess makes it an ideal radiological modality. In recent years CT has emerged as the imaging modality of choice for the evaluation of abscesses and guidance of their percutaneous drainage.¹ Computed tomography does not have important limitations. Studies show it to be the most accurate technique for abscess drainage especially in situations where the access route is not straightforward.¹

Advances in imaging and drainage techniques has broadened the use of percutaneous abscess drainage (PAD) to include the management of multi-loculated abscesses, multiple abscesses and abscesses located in difficult anatomic locations such as in the pelvis. Percutaneous abscess drainage in post-operative patients has drastically improved their prognosis and changed their management. The decrease in mortality that PAD confers in comparison to surgical intervention is impressive.² The interventional radiologist is an important contributor to the effective treatment of such conditions and collaboration with the surgical team is mandatory especially for the management of catheters after their placement.³ The aim of the present study is to report our experience in the department of computed tomography with the percutaneous drainage of post-operative abdominal and pelvic abscesses over the past 2 ½ years.

PATIENTS AND METHODS

Over the last 2 ½ years (May 2009-October 2011), we employed a percutaneous abscess drainage technique under the guidance of CT in 93 post-operative patients referred to our department, who, during the preceding 24-48 hours, had been diagnosed clinically and with use of an ultrasound and/or CT scan having an intra-abdominal or pelvic abscess. These were 45 men and 48 women, with a mean age of 59 years (range, 18-76 years). A total of 95 abscesses were detected in this cohort; 84 were located in the abdomen and 11 in the pelvis (Table 1); 8 were considered deep pelvic abscesses; abscess size ranged between 2 and 12 cm.

All patients were receiving antibiotics. A coagulation profile was checked before the procedure, which was performed only when the international normalized ratio (INR) was ≤ 1.4 . Mapping of the abdomen by CT was performed and patient position was selected. After local anesthesia, the Seldinger technique was employed in 92 cases. A 16-17F needle was initially advanced into the abscess. Aspiration of at least 20 ml of fluid was performed and sent for microbiological examination. A 0.035 inch guide-wire was inserted through the needle and a catheter was advanced over the wire and into the abscess

TABLE 1. Type of Surgical Procedure Leading to Postoperative Abscess and Number of Abscesses that Needed Percutaneous Drainage

Surgical Procedure	Number of Abscesses
Splenectomy	14
Gastric surgery	16
Pancreatic surgery	11
Left Hemi-colectomy	9
Right hemi-colectomy	8
Rectal surgery	16
Inflammatory bowel disease	9
Cholecystectomy	12

after serial tract dilations. Selection of the catheter depended on the viscosity of the aspirated fluid. The tilted gantry technique (angling the gantry of the scanner) was employed in two cases of deep pelvic abscesses. This technique can provide an approach route free of the overlying structures. After the catheters were in place they were secured with sutures and aspiration of the abscess was performed for its decompression. Lavage was performed when viscous material was aspirated. In order to check for proper catheter placement and the results of the aspiration, repeat CT scanning of the patient was performed before exiting the CT-suite. Major complications of the procedure were defined as septic shock, hemorrhage and large bowel transgression requiring surgical intervention.

RESULTS

A total of 111 catheters were placed in 92 patients. Percutaneous drainage of 95 abscesses in 93 patients was attempted; abscesses were successfully drained in 89 (95.7%) patients (Fig. 1-13). Four (4.3%) patients were partially drained and subsequently were treated by surgery. In one patient with a small intra-loop abscess, aspiration of the fluid was adequate for its complete drainage and a catheter was not placed (Fig. 10). One hundred and one 12-16F sump type ultrathane slip-coat hydrophilic catheters (COOK, Bloomington, Indiana, USA) and 10 8F Huisman nephrostomy catheters (COOK, Bloomington, Indiana, USA) were used. In two patients a 16F and an 8F catheters were placed in a single abscess (Fig. 1). The cause of failure to completely drain the abscess in four patients was multi-loculation in one patient and thick viscous material in the other three.

No major complications occurred in this series. Minor complications included inflammation at the point of catheter entry

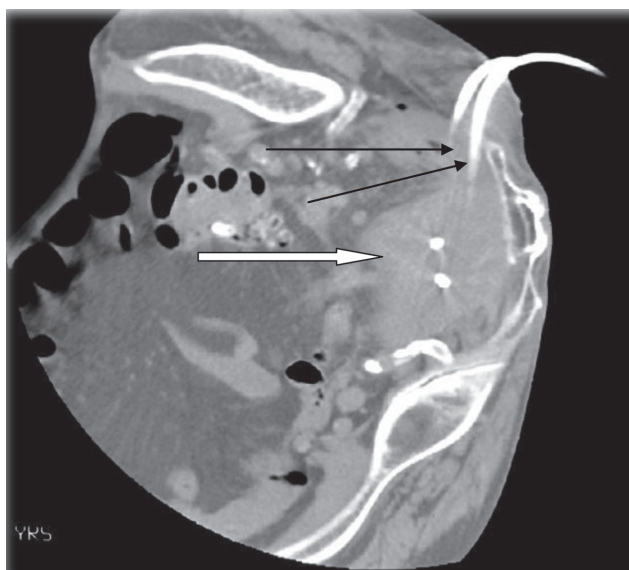


FIGURE 1. Placement of an 8F and 12F catheter (black arrows) through the greater sciatic foramen into a deep pelvic abscess (white arrow).

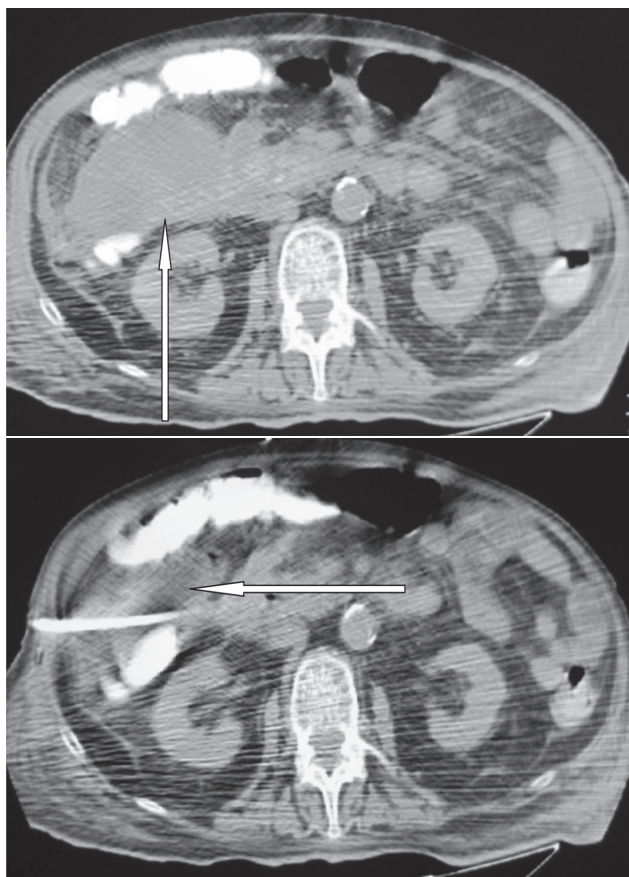


FIGURE 2. (a, upper panel) Abscess post right hemicolectomy (arrow); (b, lower panel) successful catheter placement and drainage (arrow).

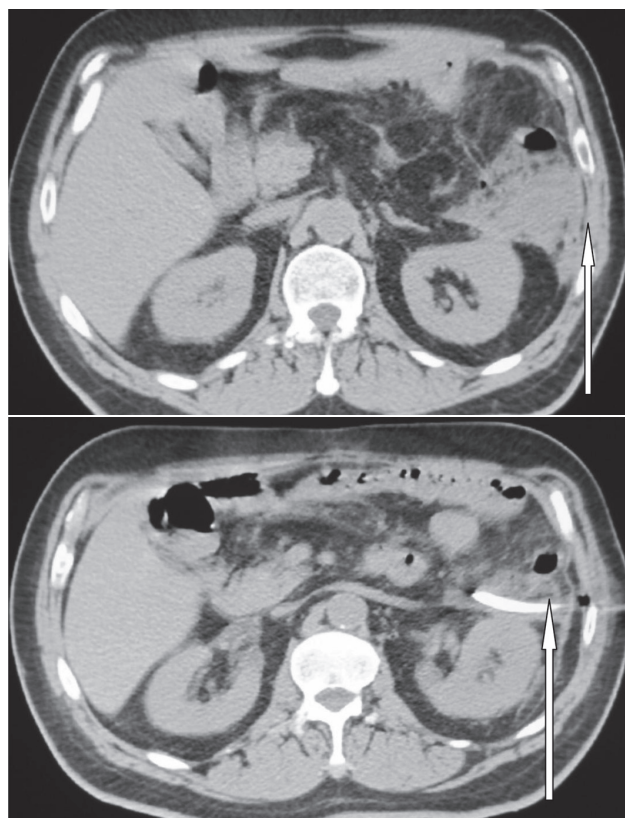


FIGURE 3. (a, upper panel) Abscess post left hemicolectomy (arrow); (b, lower panel) successful catheter placement and drainage (arrow).

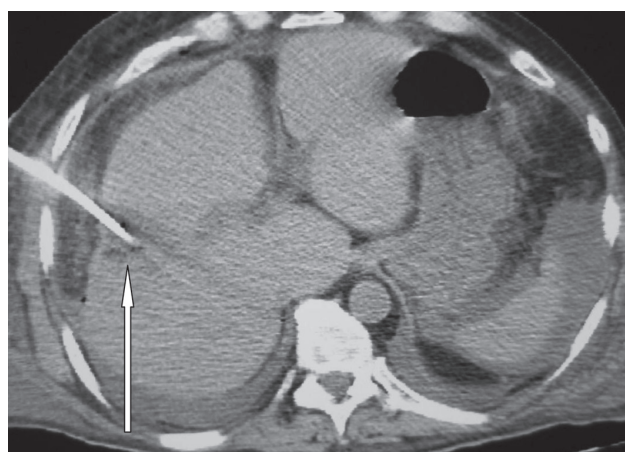


FIGURE 4. Successful placement of catheter in sub-hepatic abscess post right hemicolectomy (arrow).

in 4 patients. One pneumothorax was treated by advancing a small chest tube (8F) connected to a Hemlich valve. Catheter misplacement into the duodenum through a peripancreatic abscess occurred in one patient intra-procedurally. In this

CT GUIDED DRAINAGE OF ABSCESES

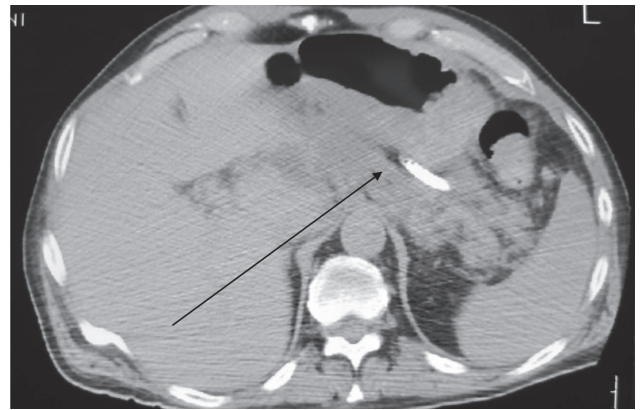
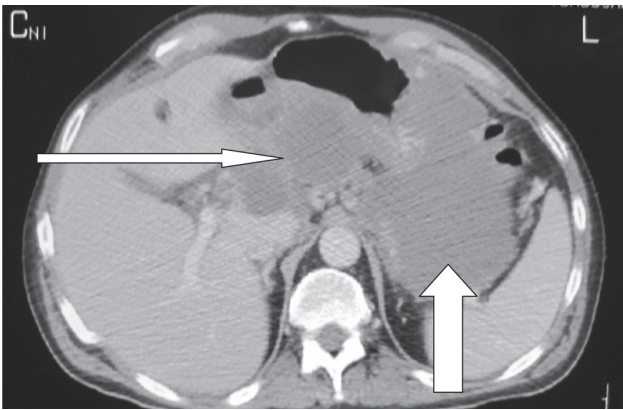


FIGURE 5. (a, left panel) Large abdominal abscess post- pancreatic surgery (white arrows); (b, right panel) successful drainage (black arrow).

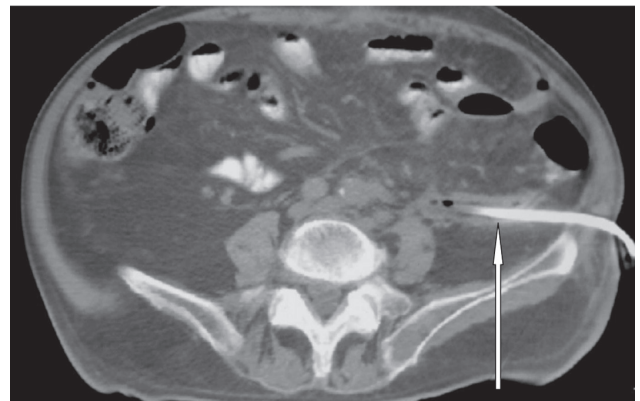
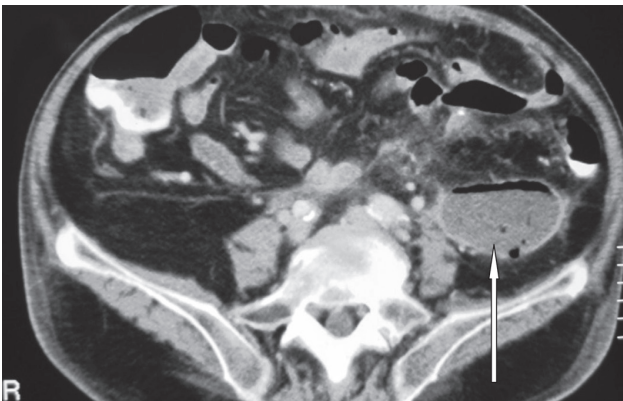


FIGURE 6. (a, left panel) Abscess post left hemicolectomy (white arrow); (b, right panel) successful catheter placement and drainage (black arrow).

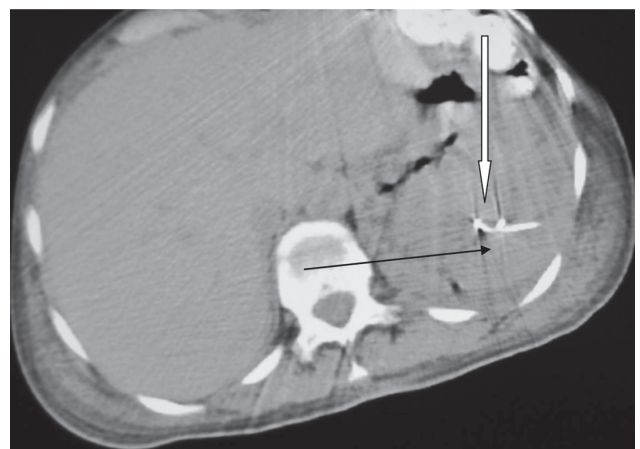
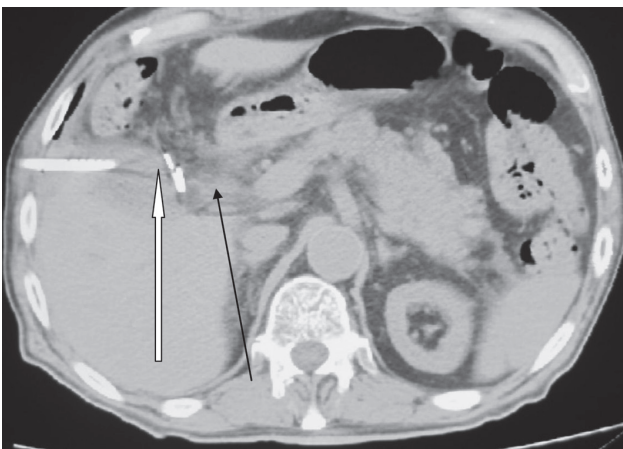


FIGURE 7. (a) Abscess in gallbladder fossa post-cholecystectomy (black arrow); (b) successful placement of catheter (white arrow).

FIGURE 8. Post-splenectomy abscess; catheter is placed into the abscess (arrow).

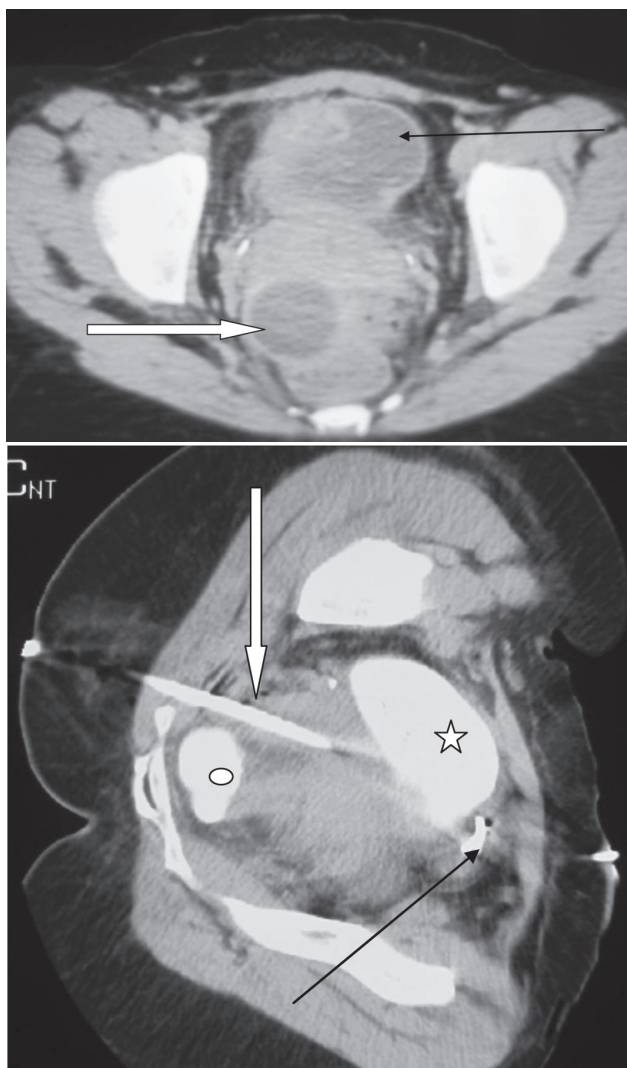


FIGURE 9. (a, upper panel) Deep pelvic abscess next to the rectum (white arrow) and another abscess over the bladder, post-appendectomy; **(b, lower panel)** successful placement of 2 catheters, the larger bore (16F) catheter was placed into the deep pelvic abscess by a transgluteal approach (white arrow), the smaller catheter was an 8F Huisman catheter (black arrow); contrast material was introduced into the rectum (round cursor) and intravenous contrast can be seen excreted into the bladder (star).

case after the removal of the 8F catheter, a 12F catheter was advanced next to the duodenum through the tract of the first catheter for prevention of a collection formation and for observation. The 12F catheter was successfully removed three days later (Fig. 13). Post-procedural displacement of the catheter occurred in 12 patients after a few days (example in Fig. 12).

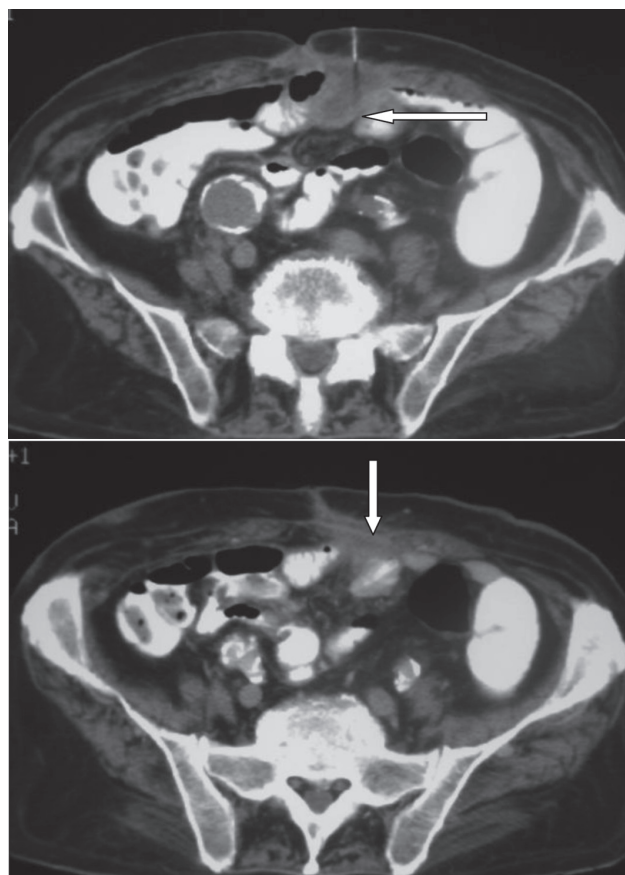


FIGURE 10. (a, upper panel) Paracentesis of an intra-loop abscess (arrow); **(b, lower panel)** Successful drainage (arrow).

DISCUSSION

Percutaneous abscess drainage (PAD) has been referred to as one of the “major advances in the 80’s”. It is a welcome development in the treatment of a disease that previously carried a 60% mortality rate.⁴ The Society of Cardiovascular and Interventional Radiology Standards of Practice Committee has published quality improvement guidelines for PAD.⁵ Curative drainage is defined as complete resolution of infection requiring no further operative intervention. It occurs in 80% of patients. Partial drainage is defined as either adequate drainage of the abscess with surgery subsequently performed to repair an underlying problem or temporarizing drainage performed to stabilize the patient prior to surgery. This occurs in 5-10% of cases. Failure occurs in 5-10% of cases and recurrence in 5-10%.

The techniques used are the Trocar and Seldinger techniques. Advantages of the Seldinger technique include the ability to direct the wire to the precise site of the abscess. It is considered a safer technique but more time-consuming.⁶ Once

CT GUIDED DRAINAGE OF ABSCESES

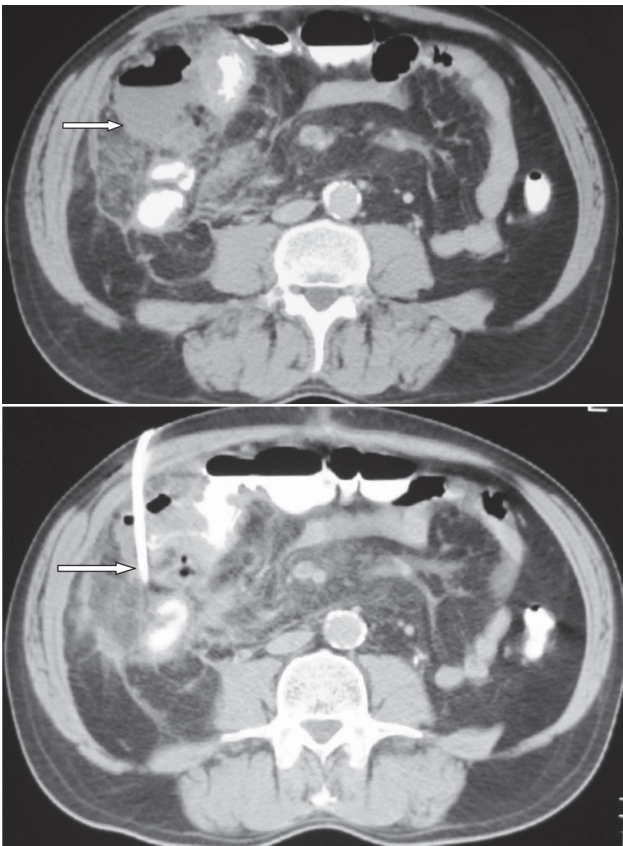


FIGURE 11. (a, upper panel) Abscess post-right hemicolectomy (arrow); (b, lower panel) catheter placed into the abscess (arrow).

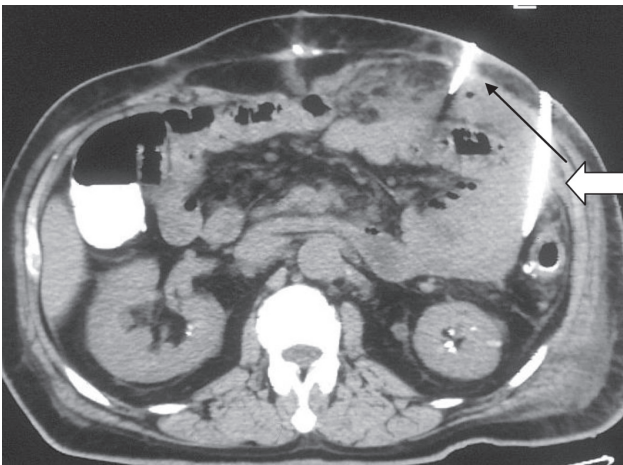


FIGURE 12. Placement of 2 sump catheters in an abdominal abscess (surgery of inflammatory bowel disease) (arrows); displacement of one catheter (black arrow).

the guide-wire is advanced it can be used to go through septa when an abscess is loculated. We have employed this method

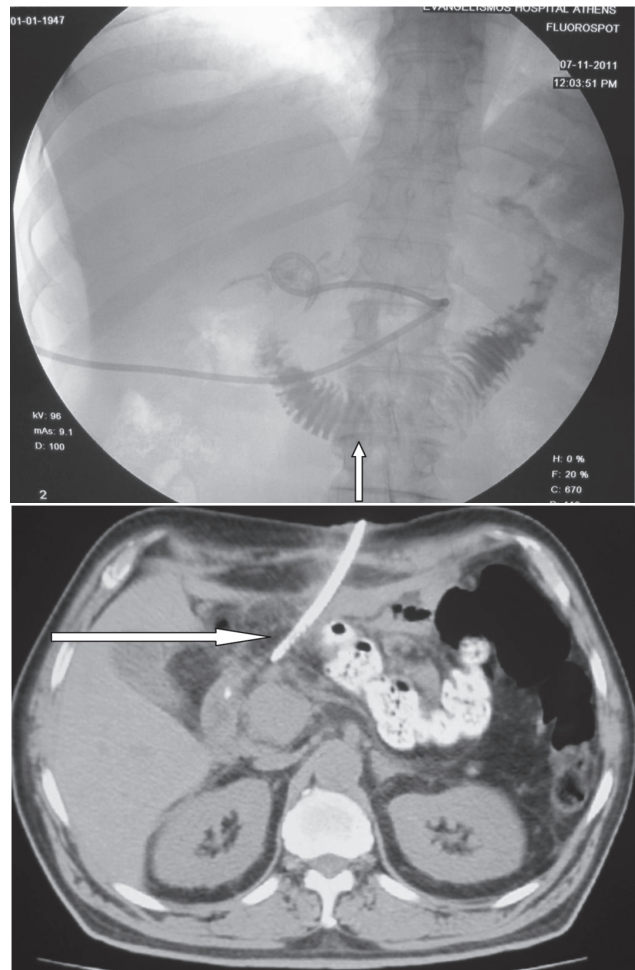


FIGURE 13. (a, upper panel) Roentgenogram depicting a pig-tail catheter misplaced into the duodenum (arrow) after the infusion of contrast material through the catheter; (b, lower panel) catheter placement next to the duodenum through the tract of the first one for prevention of fluid collection (arrow).

in many of our cases. Specifically, when the septa seem to be hard, we use the hard point of the wire to break them and then introduce the floppy end (J point) to advance the catheter. The disadvantage of the Seldinger technique is that the guidewire is not visualized in its entirety to the CT axial acquisition.⁵ The Trocar technique is a single step placement of the catheter. The stiffness of the catheter allows more control and the process is faster. Its major disadvantage is that it is difficult to reposition in case of catheter misplacement.⁵

There are no major contraindications for percutaneous drainage. Uncorrected coagulopathy and un-cooperative patients are considered contraindications for PAD. When the INR is ≤ 1.4 the procedure can be safely performed. When the INR is >1.4 , coagulopathy should be corrected prior to the procedure. Patients on warfarin may require 48-72 hours

for correction of the INR. Patients with severe coagulopathy requiring such a procedure may require coagulation support after the procedure.⁶

In the case of unsafe access, the procedure is not performed. Access through blood vessels, the large intestine and spleen are considered unsafe. Transection of the small intestine with a small gauge needle (19-22G) is generally considered safe.⁶ In our series of patients we did not transect the small intestine in any instance.

Major complications include septic shock, hemorrhage and large bowel or abdominal organ transgression requiring surgical intervention. Inadvertent catheterization or traversal of the intestine, liver or spleen can place the patient at immediate risk of major parenchymal or peritoneal bleeding and life-threatening peritonitis through the spread of abscess contents to adjacent spaces or organs.⁶ The major complication rates reported are between 3-10%.⁷ Complications can be prevented by careful access route planning and correct patient positioning when possible. Choosing an access route that avoids bowel, correction of any bleeding diathesis and avoiding blood vessels decrease the risk of major complications. Alternative approaches such as the transgluteal approach can be used to establish drainage of deep pelvic abscesses that are difficult to reach. When we performed the transgluteal approach to drain deep pelvic abscesses, the patient was positioned in a lateral position or decubitus after contrast material was infused through a Foley catheter into the rectum. Modification of CT hardware, such as the tilted gantry technique, allows drainage of less accessible abscesses avoiding the sciatic nerve and the gluteal vessels.⁸ In our 11 cases of the transgluteal drainage, our access route was through the greater sciatic foramen with a medial approach to avoid impingement of the sciatic nerve (Fig 1).

Lower success rates of percutaneous drainage are encountered when an abscess has a fistulous communication and in multi-loculated collections.⁹ Transcatheter thrombolytic agents such as 125,000 U of streptokinase can be administered twice a day in complex multiloculated abscesses to lyse intervening septa and facilitate drainage.⁹

Persistent fever, pain or leucocytosis after successful catheter deployment suggest the need for further imaging in order to evaluate the position of the catheter. In case of displacement, the catheter should be repositioned. We encountered this problem in 9 patients. After re-scanning the patients, new catheters were placed successfully. The Huisman catheters we use have the advantage of being smaller in diameter (8F). The internal retention mechanism, "pigtail", makes them less prone to displacement. The larger (12-16F) sump hydrophilic catheters have the advantage of draining viscous material and blood sediments but are more prone to inadvertent catheter movement or even withdrawal.¹⁰

When the appearance of the drained fluid changes or when it increases after a few days, a fistula should be suspected and

a sonogram may be used for localization. Prolonged drainage usually heals fistulas but sometimes surgery may be needed.¹¹ We did not encounter such a condition in the patients treated for post-operative abscesses in our series. We have come across fistulas in peri-pancreatic abscesses or abscesses caused by diverticulitis in non-operated patients.

Catheter management is very crucial for the success of drainage. Catheter flushing should be performed every 6-8 hours. Our team is not involved in catheter management. The surgical team manages the catheters and decides for their removal even though reports state that when the radiology team is involved fewer complications arise such as clogging and displacement.³

CONCLUSION

Our results confirm the effectiveness and safety of percutaneous drainage of post-surgical abscesses under CT guidance. Adequate patient preparation, planning of the access route and direct involvement in patient care improves the outcome of the procedure.¹² The interventional radiologist has a major role in the treatment of such conditions. Percutaneous abscess drainage reduces morbidity and mortality compared with open surgical drainage by offering minimally invasive therapeutic techniques and avoidance of general anesthesia.^{13,14}

REFERENCES

1. Roche J. Effectiveness of computed tomography in the diagnosis of intraabdominal abscess. *Med J Aus* 1981;25:85-93.
2. Van Sonnenberg E, Wing VW, Cassola G, et al. Temporizing effect of percutaneous drainage of complicated abscesses in critically ill patients. *AJR* 1984; 142:821-826.
3. Goldberg MA, Mueller PR, Saini S, et al. Importance of daily rounds by the radiologist after interventional procedures of the abdomen and chest. *Radiology* 1991; 180:767-770.
4. Van Sonnenberg E, Mueller P, Ferrucci J. Percutaneous drainage of 250 abdominal abscesses and fluid collections. *Radiology* 1984; 151:337-341.
5. Society of Cardiovascular and Interventional Radiology Standards of Practice Committee. Quality improvement guidelines for adult percutaneous abscess and fluid drainage. *SCVIR* 1995;6:68-70.
6. Boland GW, Lee Mj, Dawson SL, et al. Percutaneous abscess drainage: complications. *Semin Intervent Radiol* 1994; 11:267-275.
7. Lambiase RE. Percutaneous abscess and fluid drainage. A critical review. *Cardiovasc Intervent Radiol* 1991; 14:143-157.
8. Maher M, Gervais D, Kalra M, et al. The inaccessible or undrainable abscess: How to drain it. *Radiographics* 2004; 24:717-735.
9. Lagana P, Carrafiello G, Mangini M, et al. Image guided percutaneous treatment of abdominal-pelvic abscesses: a 5-year

CT GUIDED DRAINAGE OF ABSCESSSES

- experience. *Radiol Med* 2008; 113:999-1007.
10. Duszak RL, Levy JM, Akins EW, et al. Percutaneous catheter drainage of infected intra-abdominal fluid collections. American College of Radiology. ACR Appropriateness Criteria (abstr). *Radiology* 2000; 215(P):1067-1075.
 11. Lambiase RE, Cronan JJ, Dorfman SL, et al. Postoperative abscesses with enteric communication: percutaneous treatment. *Radiology* 1989; 171:497-500.
 12. Lorenz J, Thomas JL. Complications of percutaneous fluid drainage. *Semin Intervent Radiol* 2006; 23:194-204.
 13. Brodin RE, Noshier JR, Leiman S. Percutaneous catheter versus open surgical drainage in the treatment of abdominal abscesses. *Am Surg* 1984; 50:102-108.
 14. Hemming A, Davis NL, Rohina RE. Surgical versus percutaneous drainage of intra-abdominal abscesses. *Am J Surg* 1991; 161:593-595.