

**CASE REPORT**

## Atrial Flutter With 1:1 Atrioventricular Conduction and Profound Nonischemic ST Segment Depression

Sokratis Pastromas, MD, Dimitris Sakellariou, MD,  
Spyridon Koulouris, MD, Konstantinos Kappos, MD,  
Antonis S. Manolis, MD

---

**ABSTRACT**

---

A 60-year-old lady presented to the emergency room with breathlessness, palpitations, dizziness and hypotension. The ECG showed narrow QRS complex tachycardia at a rate of 300 beats/min and downsloping ST-segment depression. Following intravenous administration of adenosine, atrial flutter was confirmed and due to hemodynamic instability a direct current shock was delivered which restored sinus rhythm. The causes of such rapid ventricular rates in atrial flutter are discussed a propos with this case report.

*First Department of Cardiology,  
Evangelismos Hospital, Athens, Greece*

**KEY WORDS:** atrial flutter; enhanced atrioventricular node conduction; nonischemic ST depression

---

**INTRODUCTION**

---

Atrial flutter with 1:1 atrioventricular (AV) conduction is commonly encountered in patients receiving class I antiarrhythmic drugs, like propafenone, disopyramide or quinidine, without concomitant intake of AV node blocking agents.<sup>1</sup> On the other hand, this phenomenon is only rarely observed in patients not receiving this type of antiarrhythmic medications.<sup>2</sup> Moreover, ST-segment depression is frequently observed during paroxysmal supraventricular tachycardias and there are clinical studies showing no association with coronary heart disease.<sup>3</sup> We describe a case of a middle-aged woman who developed atrial flutter with 1:1 AV conduction and marked ST-segment depression on the surface electrocardiogram (ECG).

**LIST OF ABBREVIATIONS**  
AV = atrioventricular  
ECG = electrocardiogram

*Correspondence to:*  
Professor Antonis S. Manolis  
Director of Cardiology  
First Department of Cardiology  
Evangelismos General Hospital  
Athens, Greece  
Tel.: +30-210 720 1493  
E-mail: asm@otenet.gr

*Manuscript received March 31, 2011;  
Revised manuscript received June 1,  
2011; Accepted June 2, 2011*

---

**CASE REPORT**

---

A 60-year-old lady presented to the emergency room with breathlessness, palpitations, dizziness and hypotension with a systolic blood pressure of 80 mm Hg. Symptoms started around three to four hours earlier and over the last one hour prior to admission the patient also developed chest discomfort. She had no history or clinical evidence of coronary artery disease, pericardial, myocardial or valvular disease and she was not receiving any antiarrhythmic or antihypertensive drugs. The ECG showed narrow QRS

---

Conflict of interest: none declared

complex tachycardia at a rate of 300 beats per minute (bpm) with 2 mm downsloping ST-segment depression in leads I, II, III, aVF, V<sub>2</sub> – V<sub>6</sub> and 1 mm ST elevation in leads aVL and aVR (Fig. 1A). Following intravenous administration of 12 mg of adenosine, atrial flutter with rate of 300 bpm was noted (Fig. 1B). As the patient was hemodynamically unstable, a direct current shock at 70 Joules was delivered with successful conversion of the arrhythmia into sinus rhythm. The post-conversion ECG revealed a short PR interval (Fig. 1C); no previous ECG recording was available for comparison. After cardioversion the patient's blood pressure was stabilized and the symptoms abated.

One hour later, the ST segment deviation returned to normal (Fig. 1D), while the PR interval was persistently short. Furthermore, myocardial enzymes were normal. Cardiac ultrasound revealed no underlying cardiac abnormalities and the thyroid function tests were normal excluding hyperthyroidism. In order to rule out coronary heart disease, myocardial

scintigraphy was performed 24 hours later. No evidence of myocardial ischemia was detected. The patient refused an electrophysiological study and she was discharged on medical therapy with beta – blocker plus diltiazem.

## DISCUSSION

Atrial flutter is a relative common arrhythmia in the general population characterized by an organized atrial rhythm with a rate typically between 250 and 350 bpm. Electrophysiological studies have shown that this simple ECG definition includes tachycardias using a variety of macro-reentry circuits. The usual ventricular response in atrial flutter is about 150 bpm (due to 2:1 AV conduction).<sup>4</sup> However, under special circumstances, a 1:1 AV conduction has been noted, leading to rapid heart rates (up to 300 bpm) with hemodynamic consequences like syncope, hemodynamic collapse, angina pectoris, acute

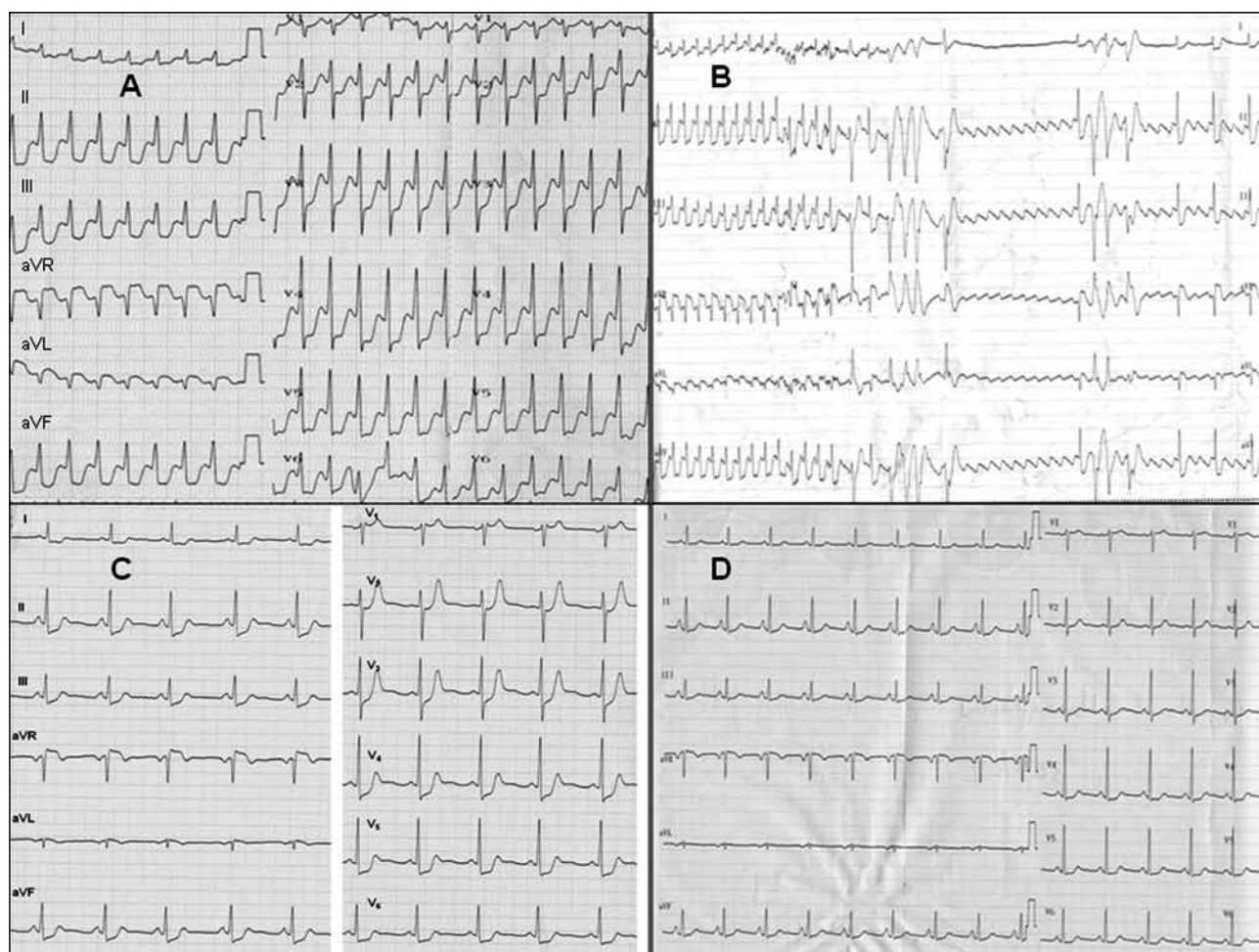


FIGURE 1. A. The presenting ECG of the patient. B. Continuous recording of limb leads during adenosine administration reveals atrial flutter waves. C. Normal sinus rhythm after the DC shock. D. ECG one hour after the restoration of normal sinus rhythm.

pulmonary edema and even sudden death, depending on the cardiac status of the individual patient.<sup>1</sup>

This phenomenon has been noted since the 1950s in patients treated with a class I antiarrhythmic drug, in patients with Wolff-Parkinson-White syndrome with an accessory AV pathway bypassing the AV node and capable of rapid AV conduction, in hyperthyroidism, and in children.<sup>5,6</sup> It seems that a preexisting rapid AV nodal conduction could be a predisposing factor for the occurrence of a 1:1 AV conduction during atrial flutter in some patients. The presence of a short PR interval indicating enhanced AV nodal conduction on the surface ECG is a simple means to identify this characteristic.<sup>7</sup> The increased P wave duration has also been associated with atrial arrhythmias.<sup>8</sup> Rarely, has this degree of rapid ventricular response been reported in the absence of antiarrhythmic drug therapy or in patients with enhanced AV nodal conduction properties, previously termed the Lown-Ganong-Levine syndrome.<sup>2</sup> In a retrospective study published by Kawabata et al, all patients who were suffering from atrial flutter with 1:1 AV conduction were receiving a class Ia, Ic or III antiarrhythmic drug and they had a significantly longer atrial flutter cycle length and more rapid AV nodal conduction time compared with those with atrial flutter without 1:1 AV conduction.<sup>9</sup>

In our patient, atrial flutter with 1:1 AV conduction was not associated with any apparent cause. Moreover, during the tachycardia remarkable ST-segment depression was noted without underlying true ischemia as evidenced by the absence of cardiac enzyme elevation and negative myocardial scintigraphy, essentially ruling out any significant underlying coronary heart disease. ST-segment depression is frequently observed during episodes of paroxysmal supraventricular tachycardias. From previous clinical studies it has been suggested that coronary artery disease is one but not the only mechanism causing these ECG repolarization abnormalities. Petsas et al performed an exercise treadmill stress test in 16 patients with noticeable ST segment depression during supraventricular tachycardia and they found that 94% of patients had no evidence of coronary artery disease.<sup>10</sup> Moreover, Lin et al examined 51 patients with narrow QRS supraventricular arrhythmias and found that 51% of them developed repolarization changes during the tachycardia without evidence of coronary heart disease.<sup>3</sup> In a prospective study, Androulakis et al did not find any strong association between transient ischemic type ST-segment depression during paroxysms of atrial fibrillation and underlying occult coronary artery disease.<sup>11</sup>

In conclusion, atrial flutter with 1:1 AV conduction must

be suspected in case of a narrow QRS complex tachycardia with extremely rapid ventricular rate even in the absence of any antiarrhythmic drug intake. As atrial flutter is a macroreentrant tachycardia, radiofrequency catheter ablation may be considered to be an appropriate therapeutic modality,<sup>4</sup> especially in patients with 1:1 AV conduction who cannot tolerate this rapid rhythm and present with syncope or presyncope and associated hemodynamic collapse.

## REFERENCES

1. El-Harari MB, Adams PC. Atrial flutter with 1:1 atrioventricular conduction caused by propafenone. *Pacing Clin Electrophysiol* 1998;21:1999-2001.
2. Turitto G, Akhrass P, Leonardi M, Saponieri C, Sette A, El-Sherif N. Atrial flutter with spontaneous 1:1 atrioventricular conduction in adults: an uncommon but frequently missed cause for syncope/presyncope. *Pacing Clin Electrophysiol* 2009;32:82-90.
3. Lin YJ, Tai CT, Chiang CE, et al. Mechanism of repolarization change during initiation of supraventricular tachycardia. *J Cardiovasc Electrophysiol* 2004;15:1233-1237.
4. Lee KW, Yang Y, Scheinman MM. Atrial flutter: a review of its history, mechanisms, clinical features, and current therapy. *Curr Probl Cardiol* 2005;30:121-167.
5. Finkelstein D, Gold H, Bellet S. Atrial flutter with 1:1 AV conduction. *Am J Med* 1956;20:65-76.
6. Granada J, Uribe W, Chyou PH, et al. Incidence and predictors of atrial flutter in the general population. *J Am Coll Cardiol* 2000;36:2242-2246.
7. Brembilla-Perrot B, Houriez P, Beurrier D, Claudon O, Terrier de la Chaise A, Louis P. Predictors of atrial flutter with 1:1 conduction in patients treated with class I antiarrhythmic drugs for atrial tachyarrhythmias. *Int J Cardiol* 2001;80:7-15.
8. Hamdan MH, Zagrodzky JD, Page RL, et al. Effect of P-wave timing during supraventricular tachycardia on the hemodynamic and sympathetic neural response. *Circulation* 2001;103:96-101.
9. Kawabata M, Hirao K, Higuchi K, et al. Clinical and electrophysiological characteristics of patients having atrial flutter with 1:1 atrioventricular conduction. *Europace* 2008;10:284-288.
10. Petsas AA, Anastassiades LC, Antonopoulos AG. Exercise testing for assessment of the significance of ST segment depression observed during episodes of paroxysmal supraventricular tachycardia. *Eur Heart J* 1990 ;11:974-979.
11. Androulakis A, Aznaouridis KA, Aggeli CJ, et al. Transient ST-segment depression during paroxysms of atrial fibrillation in otherwise normal individuals: relation with underlying coronary artery disease. *J Am Coll Cardiol* 2007;50:1909-1911.