

CASE REPORT

ECG Changes Associated With Right-Sided Pneumothorax

Dimitrios Tsilakis, Athanasios Kranidis, Spyridon Koulouris,
Antonis S. Manolis

*1st Department of Cardiology,
Evangelismos General Hospital,
Athens, Greece*

ABSTRACT

Various ECG changes have been described with pneumothorax, most often left-sided. We present a case of spontaneous right-sided pneumothorax, presenting with an ECG suggestive of an old myocardial infarction. A chest X-ray confirmed the diagnosis of pneumothorax, while an echocardiogram and serial cardiac enzyme testing excluded myocardial infarction (old or recent). ECG changes returned to normal after chest tube insertion and airdrainage. Physicians must be familiar with the ECG changes that can be caused by pneumothorax in order to avoid diagnostic and therapeutic pitfalls.

KEY WORDS: *electrocardiogram,
myocardial infarction, chest pain*

INTRODUCTION

A variety of ECG changes have been reported with spontaneous pneumothorax. They range from ST segment elevation suggestive of acute myocardial infarction, to diminution of R wave amplitude in the precordial leads and inversion of precordial T waves. The major characteristic of these ECG changes is the fact that they return to normal with the resolution of pneumothorax. In most cases it is a left sided pneumothorax affecting the ECG (1,2). We present a case of spontaneous right-sided pneumothorax with ECG changes suggestive of an old myocardial infarction.

CASE PRESENTATION

A 71-year-old woman presented to the Emergency Department with sharp, retrosternal and right-sided chest pain and shortness of breath, of spontaneous onset 12 hours before admission. Pain was exacerbated by respiration. The patient had a 20-year history of hypertension treated with an ACE-inhibitor and a 35-pack-years history of smoking. She denied any chest trauma. On admission the patient was distressed and the vital signs were: BP 150/100mmHg, pulse 110bpm, and respiratory rate was 25/minute. She was afebrile. Physical examination revealed: reduced breath sounds on the right hemithorax while the trachea was in the middle position and the heart sounds were normal. Her admission ECG showed poor R wave progression in leads V1-V3 and q waves in leads V4-V6 and leads II, III and aVF (fig. 1a, b). Her chest X-ray revealed a right pneumothorax (fig. 2). An echocardiogram was requested due to her ECG findings and it showed a normal LV systolic function with no evidence of

Address for correspondence:
Dr. Dimitrios Tsilakis, Resident in
Cardiology, 20-22 Pontou Str,
Athens 11528, Greece,
Tel. +302107716278,
Business tel. +302107201457,
Fax +302107218025,
e-mail: jimtsilakis@hotmail.com

Submitted: 15-11-07

Revised: 10-01-08,

Accepted: 20-02-08

ECG CHANGES ASSOCIATED WITH RIGHT-SIDED PNEUMOTHORAX

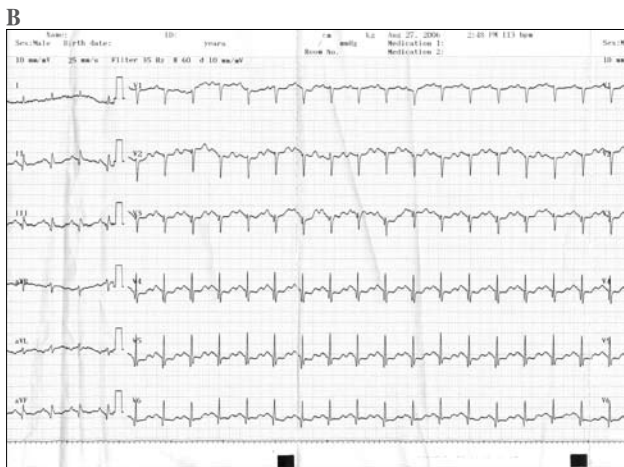
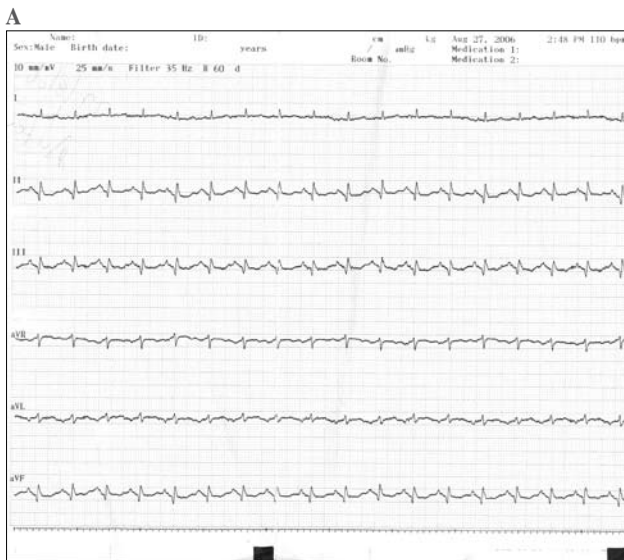

FIGURE 1. ECG before chest tube insertion.

regional wall motion abnormalities in either the anterior or the inferior LV segments. The patient was promptly treated with a chest tube insertion which led to right lung expansion (fig. 3). Cardiac enzymes serially tested over the next hours were all within normal limits. Her ECG two days later showed normalization of R wave progression in the chest leads, and diminution of the q waves in leads V4-V6 (fig. 4a, b). The patient made an uncomplicated recovery and she was discharged home four days later.

DISCUSSION

The first case of ECG changes associated with spontaneous pneumothorax was described in 1928 (3). Walston and Brewer described the following ECG changes with pneumothorax:

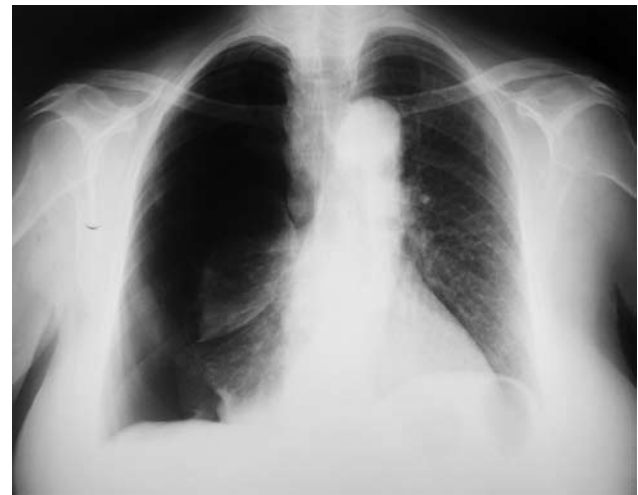

FIGURE 2. Chest X-Ray showing right pneumothorax.

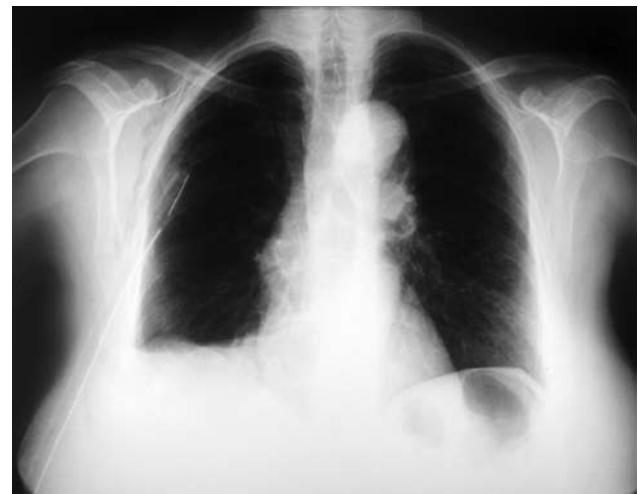

FIGURE 3. Chest X-Ray showing right lung expansion after evacuation of the air.

diminution of amplitude of precordial R waves, inversion of precordial T waves, diminution of QRS amplitude and rightward shift in the frontal QRS axis (4). Numerous cases of mostly left-sided pneumothorax causing transient, ischemic-type ECG changes that could lead to diagnostic and therapeutic difficulties have been reported since then. Similar ECG changes have been rarely reported with right-sided pneumothorax (5,6). Recently, Monterubio et al, described a case of iatrogenic, bilateral pneumothorax with a decrease in QRS amplitude and loss of R wave voltage in the precordial leads which returned to baseline after right pleural cavity evacuation (7).

In our case, the right-sided pneumothorax caused poor R wave progression in the precordial leads but also a q wave in

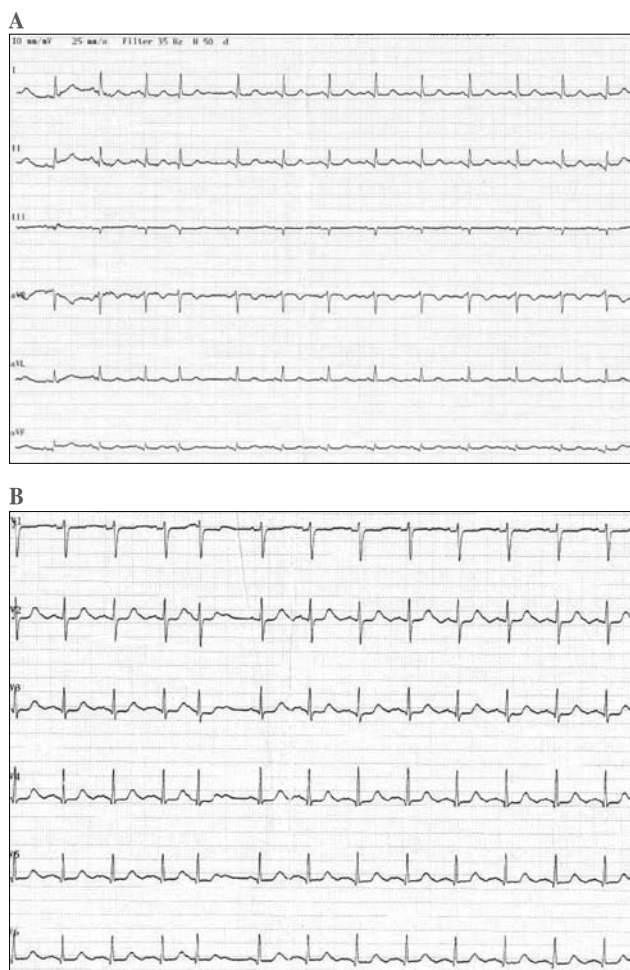

FIGURE 4. ECG after chest tube insertion.

the inferior leads compatible with an old myocardial infarction. This was excluded particularly with the echocardiogram, which showed no regional wall motion abnormalities. The ECG changes returned to baseline after removing the air

from the right pleural cavity. The ECG changes associated with pneumothorax may be due to the air insulating the heart from the chest wall rather than to cardiac rotation, dilatation or displacement (8). However, tension pneumothorax has been described to cause true ischemic changes, accompanied by wall motion abnormalities demonstrated with echocardiography, possibly due to impaired systolic and diastolic coronary artery blood flow (9).

In conclusion, physicians must be acquainted with the ECG changes associated with both left and right-sided pneumothorax in order to avoid diagnostic misinterpretations and to promptly provide the appropriate treatment.

REFERENCES

1. Habibzadeh MA. ECG changes associated with spontaneous left-sided pneumothorax. *Postgrad Med* 1980; 68(4): 221-3, 226
2. Werne CS, Sands MJ. Left tension pneumothorax masquerading as anterior myocardial infarction. *Ann Emerg Med* 1985; 14(2):164-6
3. Master AM. The electrocardiographic changes of pneumothorax in which the heart has been rotated; similarity of some of these changes to those indicating myocardial involvement. *Am Heart J* 1928; 3:472-483.
4. Walston A, Brewer DL. The electrocardiographic manifestations of spontaneous left pneumothorax: *Ann Intern Med* 1974; 80:375-379.
5. Alikhan M, Biddison JH. Electrocardiographic changes with right-sided pneumothorax: *South Med J* 1998; 91:677-680
6. Maheshwari M, Mittal SR. Right-sided pneumothorax simulating anterior wall myocardial infarction. *Indian Heart J* 2004; 56:73
7. Monterrubio VJ, Bergés DF, Fraga RA, Veiga MD et al. ST elevation and tension pneumothorax. *Rev Esp Cardiol* 2000; 53:467-470.
8. Feldman T, January CT. ECG changes in pneumothorax. A unique finding and proposed mechanism. *Chest* 1984; 86:143-145.
9. Janssens U, Koch KC, Graf J, Hanrath P. Severe transmural ischemia in a patient with tension pneumothorax. *Crit Care Med* 2000; 28:1638-1641.