

CASE REPORT

Narrow QRS-Complex Tachycardia with Long RP-Interval: What is the Mechanism?

Charalampos Kriatselis, MD, Sotirios Nedios, MD, Mattias Roser, MD, Jin-Hong Gerds-Li, MD, Eckart Fleck, MD

*Internal Medicine-Cardiology,
Deutsches Herzzentrum Berlin, Berlin,
Germany*

KEY WORDS: *supraventricular tachycardia; long RP tachycardia; atrioventricular nodal re-entry; concealed accessory pathway*

ABBREVIATIONS

AV = atrioventricular
AVNRT = atrioventricular nodal re-entrant tachycardia
AVRT = atrioventricular reciprocating tachycardia
CS = coronary sinus
EAT = ectopic atrial tachycardia
RF = radiofrequency
RV = right ventricular
SVT = supraventricular tachycardia
VA = ventriculo-atrial

Correspondence to:

Charalampos Kriatselis, MD
Internal Medicine-Cardiology
Deutsches Herzzentrum Berlin
Berlin, Germany
E-mail: kriatselis@gmx.de/
kriatselis@dhzb.de

*Manuscript received January 3, 2011;
Accepted with revision March 26, 2011*

Conflict of interest: None declared

ABSTRACT

A rare case of long-RP supraventricular tachycardia is presented and the electrophysiological mechanism is analyzed, refuting recently proposed criteria of differential diagnosis.

INTRODUCTION

The differential diagnosis of a long-RP supraventricular tachycardia is not an easy task, even during an electrophysiological study.¹⁻³ Several criteria have been proposed, but exceptions may be encountered. Following our preliminary report of such an exception to a recently described approach,⁴ we herein expand our initial presentation⁵ with illustrative examples.

CASE REPORT

A 60-year-old man with a regular, narrow-QRS supraventricular tachycardia (SVT) with a long RP interval was referred for electrophysiological study and catheter ablation. The clinical tachycardia was present spontaneously at the beginning of the examination. It was an SVT with a long ventriculo-atrial (VA) interval with a cycle length of 470 to 490 ms (rate of ~122-128 beats per minute-bpm) and a pattern of atrial activation from the proximal to the distal coronary sinus. The introduction of a premature ventricular beat at a time when the His bundle was refractory led to a slight prolongation of the following VA interval (Figure 1). Right ventricular (RV) pacing at a cycle length of 430 ms (~140 bpm) resulted in tachycardia reset after the fourth fully preexcited beat (Figure 2). Based on these observations what is the mechanism of the tachycardia?

DISCUSSION

The most common type of SVT is a narrow-QRS tachycardia with a short RP interval, usually due to a re-entry mechanism in the atrioventricular (AV) node,

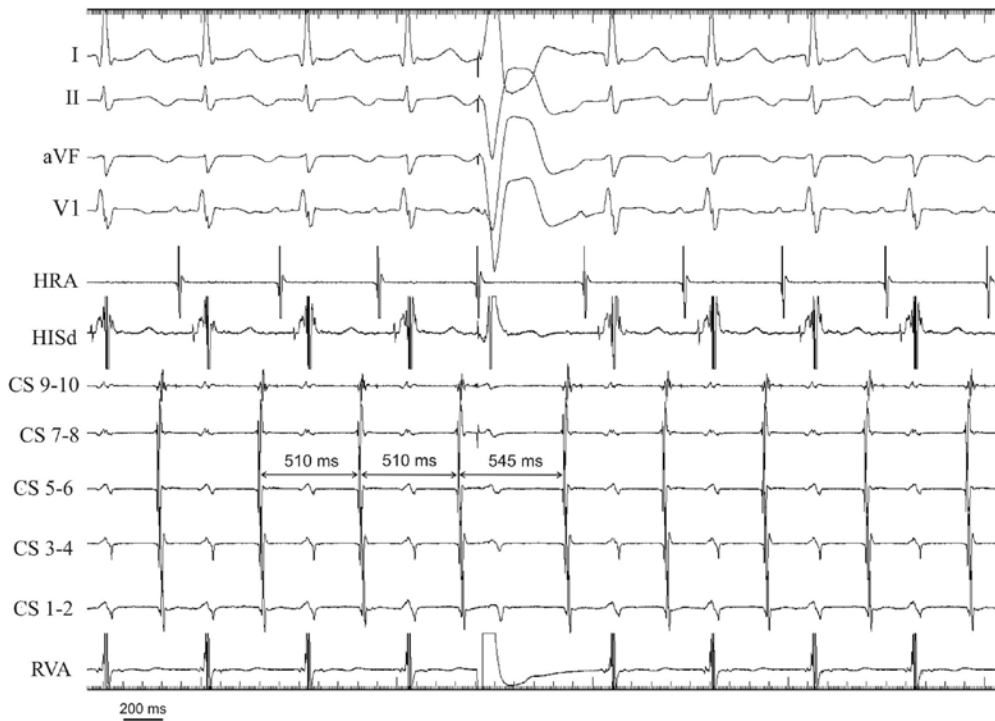

FIGURE 1. During tachycardia the coronary sinus is activated from proximal to distal (earliest activation at CS-7-8, CS 9-10 protrudes into the right atrium). Introduction of a premature ventricular beat at a time when the His bundle is refractory leads to a slight prolongation of the following VA interval, implying the presence of a decremental accessory pathway as the retrograde limb of the reentry. Abbreviations from above to below: ECG leads I, II, aVF, and V1; HRA = high right atrium; HISd = distal His bundle recording, CS 9-10 till CS 1-2: proximal to distal coronary sinus; RVA = right ventricular apex.

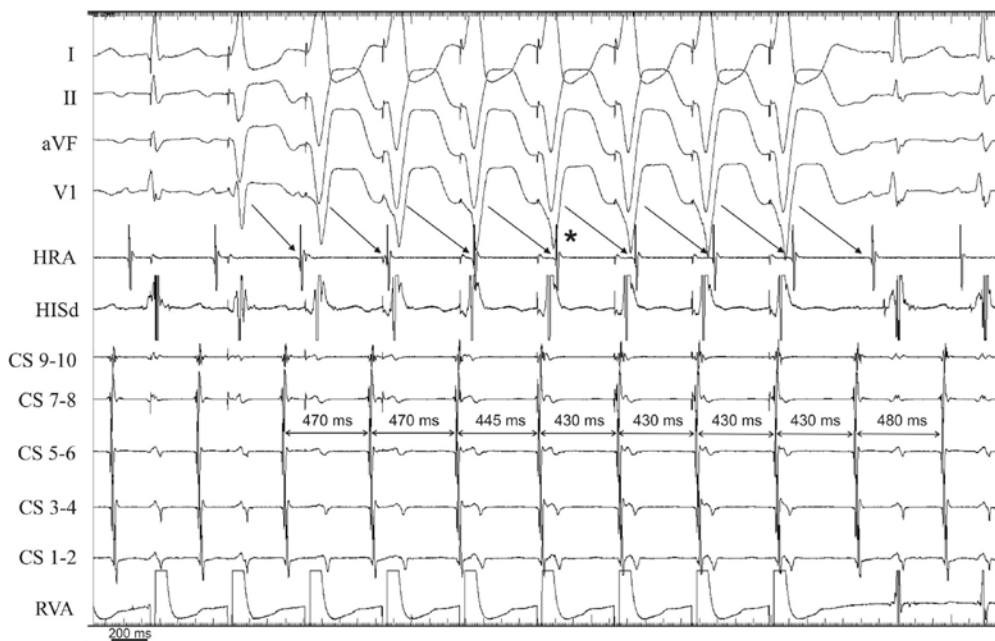


FIGURE 2. Right ventricular pacing at a cycle length of 430 ms resulted in full reset of the tachycardia after the fourth fully preexcited beat (asterisk). Abbreviations same as in Figure 1.

LONG RP TACHYCARDIA

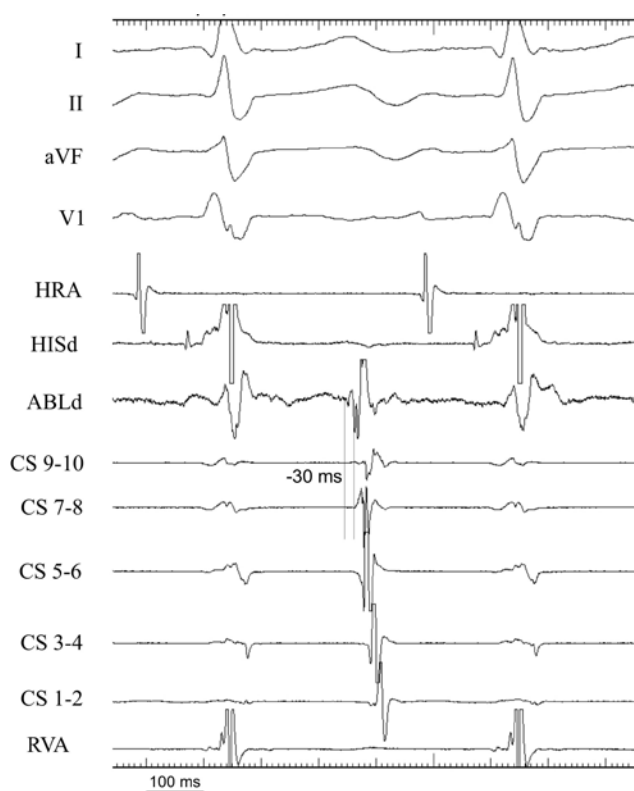


FIGURE 3. The earliest atrial activation was recorded at the inferior-medial segment of the tricuspidal annulus. Local atrial activation at this site occurred 30 ms earlier than activation at proximal coronary sinus. Abbreviations same as in Figure 1.

called typical AV nodal re-entrant tachycardia (AVNRT), whereby the AN node has dual pathways (slow or α -pathway and fast or β -pathway) and the electrical impulse, reaching the ventricles faster via the fast pathway during normal sinus rhythm, now gets blocked in the fast pathway (e.g. when an atrial extrasystole appears) and travels down the slow pathway, returning to the atria via the fast pathway, and re-circulating, thus setting in motion this slow-fast pathway sequence (typical or slow-fast AVNRT).⁶ A second most common type of SVT, also with a short RP-interval, is the orthodromic AV reciprocation tachycardia (AVRT) occurring in the presence of a retrogradely conducting accessory pathway, with the electrical impulse conducting normally via the AV node, activating the ventricles and returning to the atria via the fast-conducting accessory pathway.

A supraventricular tachycardia with a long RP interval

is much less common and the differential diagnosis of such an SVT includes an ectopic atrial tachycardia (EAT), an orthodromic AVRT due to an uncommon concealed accessory pathway with decremental properties, and an atypical (with a reversed circuit) AVNRT (fast-slow AVNRT).¹⁻⁶ In the present case, prolongation of the subsequent VA interval during the tachycardia after introduction of a premature ventricular beat at a time when the His bundle was refractory excludes EAT and provides a strong evidence against an atypical AVNRT. However, RV pacing at a cycle length of 430 ms resulted in tachycardia reset after the fourth fully preexcited beat. This has recently been shown by Dandamudi et al. to be a 100% predictive criterion for AVNRT and against orthodromic AVRT.⁴

After anatomical variations of the coronary sinus (such as diverticles) had been excluded by angiography, activation mapping during tachycardia was performed. The septal area close to slow pathway was activated 40 ms later than proximal coronary sinus (not shown). The earliest atrial activation was recorded at the inferior-medial segment of the tricuspidal valve (30 ms earlier than proximal coronary sinus), thus confirming the presence of a right infero-septal accessory pathway (Figure 3). Radiofrequency (RF) energy application at this site resulted in termination of tachycardia by VA block in 3.4 sec (Figure 4). During a waiting time of 45 minutes, no tachycardia was inducible in the patient.

This case report illustrates that diagnostic criteria have very rarely, if ever, a positive or negative predictive value of 100%. In their work Dandamudi et al⁴ showed that by pacing the right ventricular (RV) apex during the tachycardia at a cycle length that was 10-40 ms shorter than the tachycardia cycle length, the first fully preexcited RV paced beat reset the atrium in all cases of orthodromic AVRT. In the case of AVNRT the average number of fully preexcited RV beats was 3.7 ± 1.1 and in no case of AVNRT was the atrium reset in less than 2 fully preexcited beats. The authors concluded that "a cut-off of at least two beats would yield a positive predictive value of 100% for AVNRT". However, our case shows that orthodromic AVRT over a decrementally conducting accessory pathway may be an exception to this clinically useful criterion, as decremental conduction through the accessory pathway may prevent immediate reset (in two or less beats) of the atria during ventricular stimulation. We believe that it is very important to illustrate this exception, as in our case a misdiagnosis of atypical AVNRT would have led to repeated RF application in the slow-pathway area, thus increasing the risk of inadvertent AV block.

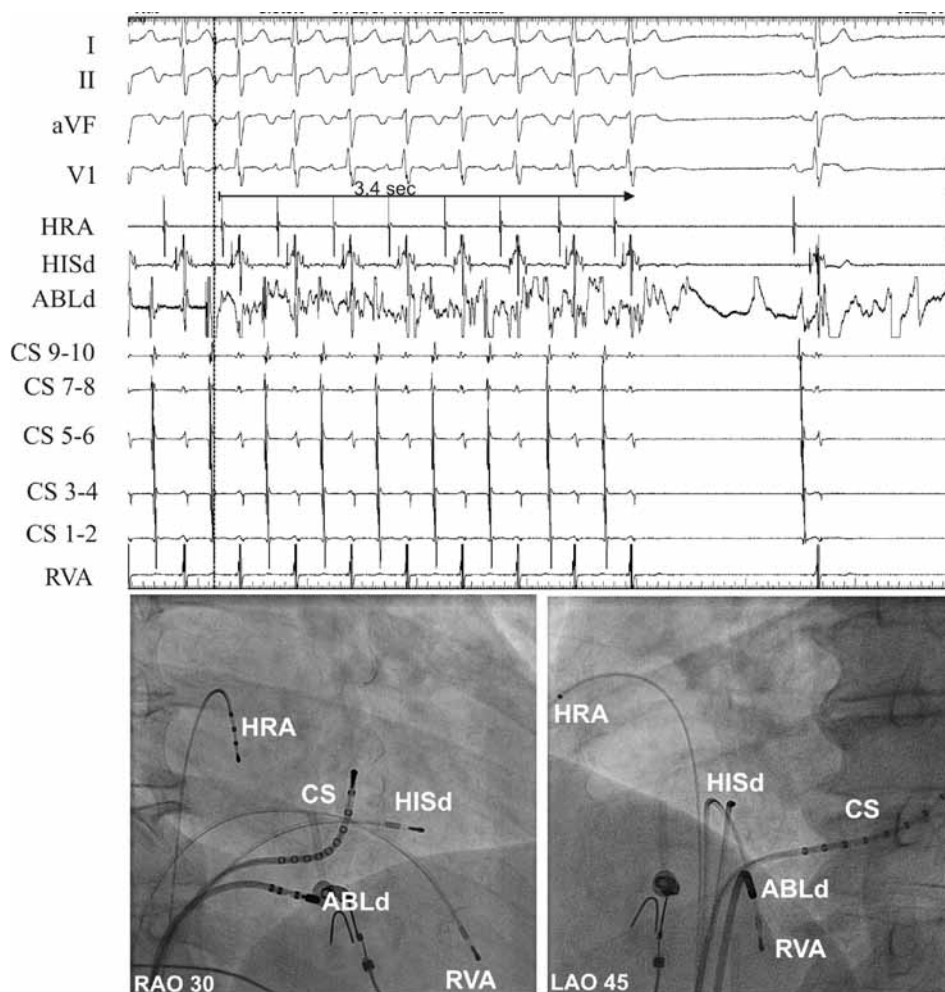


FIGURE 4. Radiofrequency (RF) energy application at this site (see fluoroscopic images at lower panel) resulted in termination of tachycardia by VA block in 3.4 sec. During a waiting time of 45 min, no tachycardia was inducible in the patient. Abbreviations same as in Figure 1, additionally ABLd = distal pole of the ablation catheter; RAO = right anterior oblique; LAO = left anterior oblique.

REFERENCES

1. Michaud GF, Tada H, Chough S, et al. Differentiation of atypical atrioventricular node re-entrant from orthodromic reciprocating tachycardia using a septal accessory pathway by the response to ventricular pacing. *J Am Coll Cardiol* 2001;38:1163-1167.
2. Katritsis DG, Camm AJ. Atrioventricular nodal reentrant tachycardia. *Circulation* 2010;122:831-840.
3. Divakara Menon SM, Healy JS, Nair GM, et al. A case of long RP tachycardia: What is the mechanism? *J Cardiovasc Electro-physiol* 2009;20:702-704.
4. Dandamudi G, Mokabberi R, Assal C, et al. A novel approach to differentiating orthodromic reciprocating tachycardia from atrioventricular nodal reentrant tachycardia. *Heart Rhythm* 2010, 7:1326-1329.
5. Kriatselis C, Nedios S, Mattias Roser M, Gerds-Li J-H. Differentiation of orthodromic reciprocating tachycardia from atrioventricular nodal reentrant tachycardia (Letter). *Heart Rhythm* 2011; 8: (in press).
6. Manolis AS, Estes NA 3rd. Supraventricular tachycardia. Mechanisms and therapy. *Arch Intern Med* 1987;147:1706-1716.