

REVIEW

Cryptogenic Stroke and Migraine Headache: The Clinical Cardiologist's View

Harold L. Kennedy, MD, MPH, FACC, FESC

*Division of Cardiovascular Disease,
Department of Medicine, University of
Michigan, Ann Arbor, Michigan, USA*

KEY WORDS: *stroke; paradoxical embolism; patent foramen ovale; atrial septal defect; atrial septal aneurysm; closure devices; migraine; headache; magnetic resonance imaging*

LIST OF ABBREVIATIONS:

ASA = atrial septal aneurysm
ASD = atrial septal defect
MRI = magnetic resonance imaging
PFO = patent foramen ovale
TEE = transesophageal echocardiography

Correspondence to:

Harold L Kennedy, MD
Professor of Medicine
5 Apple Tree Lane
Saint Louis, MO , 63124, USA
Tel.: 314 993-4408
Fax: 314 993-3468
E-mail: hkennedy_usa@yahoo.com

ABSTRACT

Cryptogenic stroke and migraine headache are disorders which most commonly affect persons younger than 55 years of age. In recent years these disorders have been found to have a strong association with inter-atrial cardiac defects, such as patent foramen ovale and atrial septal defect, and support the pathophysiological mechanism of paradoxical embolism with a right-to-left shunt. With the evolution of technology, magnetic resonance imaging has more clearly defined cryptogenic stroke, and percutaneous cardiac interventional devices have offered a simplified approach to closure of inter-atrial cardiac defects. Nevertheless, the evidence-based data of which sub-populations of patients with cryptogenic stroke or migraine headache will benefit from closure of inter-atrial cardiac defects is just being defined. This review offers a clinical cardiologist's viewpoint of these developments.

CRYPTOGENIC STROKE

THE CLINICAL PROBLEM

Stroke is a leading cause of death and long-term disability worldwide. Eighty-five percent of strokes are ischemic, and most ischemic strokes occur in persons older than 65 years of age in tandem with the development of atherosclerosis. Although a minority of ischemic strokes in the community affect younger adults, as many as half the patients referred to tertiary care centers are younger than 65 years of age, and up to 12% are younger than 45 years.¹ Young patients with ischemic stroke often have few, if any, risk factors for atherosclerosis. Initial evaluation of the cerebral arteries is essential but frequently unrevealing, and thus in many cases the focus must shift to the detection of potential cardiac sources of embolism that are commonly associated with, and that may cause, unexplained stroke in young persons.²

In as many as 43% of affected young adults, strokes are cryptogenic (i.e., they do not have a definite cause despite extensive evaluation).¹ This brain infarction which is commonly revealed by a magnetic resonance imaging (MRI) abnormality without an etiology is the essence of a cryptogenic stroke. The most prevalent potential source of cardioembolism in young adults (<55 years) with cryptogenic stroke is a patent

foramen ovale (PFO), which is detected in more than half of such persons undergoing evaluation.³ On the other hand, cryptogenic strokes in the middle-aged and elderly (>55years) patients account for approximately one-third of ischemic strokes, and have most commonly been associated with aortic arch atheromatous plaques.^{4,5} Transesophageal echocardiographic (TEE) detection of plaques ≥ 4 mm proximal to the ostium of the left subclavian artery in the elderly have been found to be significant predictors of new brain infarcts and other vascular events.^{4,5}

This presentation focuses on the majority of brain infarctions which occur in the young and have been found to be associated with interatrial septal abnormalities [PFO, atrial septal defect (ASD) or atrial septal aneurysm (ASA)], cardiac valvulopathies, dissections of extracranial arteries or hypercoagulable states.⁶ Whereas the latter conditions render a definable etiology of stroke, there remains in approximately 50 to 60 % of patients younger than 55 years of age (despite a thorough evaluation) an unknown cause. In these cryptogenic stroke patients, the presence of a PFO or ASD has been found by TEE in approximately 40 to 50 % of patients, and strongly suggests that the pathologic mechanism of disease is paradoxical embolism.^{6,7}

PATENT FORAMEN OVALE AND CRYPTOGENIC STROKE

A PFO has been defined by autopsy series to occur in ~25 to 27 % of the population, and is large (0.6 to 2.0 cm) in 6%.^{7,8} PFO frequency and size have been found to vary by age and size, and may be an important factor in acting as a conduit in paradoxical embolism.^{7,8} Cryptogenic stroke patients appear to have larger PFOs than those of control patients.⁸

In the recent PFO in Cryptogenic Stroke Study (PICSS), it has also been shown that large PFOs were significantly more prevalent among cryptogenic stroke patients compared with those with known cause of stroke.⁹ Additionally, stroke patients with larger PFOs have brain imaging findings suggestive of an embolic mechanism¹⁰ and PFO size may be an independent risk factor for recurrent cerebrovascular events.⁸

OTHER FACTORS RELATED TO PFO AND CRYPTOGENIC STROKE

The prevalence of *atrial septal aneurysm* (ASA) is greater among patients with embolic events. It is also well known that ASA is associated with PFO, with ~60% of patients with ASA having a PFO.¹¹ Additionally, the PFOs seen in the presence of ASA tend to be large compared with those seen without associated ASA.¹² Thus, the association of ASA with embolic events is likely based on the high prevalence of large PFOs. Because an ASA is usually highly mobile, protruding from right to left atrium, it is unlikely that a thrombus forms in situ in the ASA itself.

The *eustachian valve* is a membrane-like structure in the

right atrium. Among adults, a eustachian valve can cause a significant right-to-left shunt in the presence of a PFO or ASD by directing the blood flow pattern to the interatrial defect.¹³ These prominent eustachian valves have been found more commonly in patients with presumed paradoxical embolism than in control patients.¹³ The presence of *Chiari's network* and filamentous strands which occur in the right atrium in some patients, have also been defined to have an association with PFO.¹⁴

The hemodynamics which favor right-to-left shunting through an interatrial communication, also play a role in determining the probability of paradoxical embolization in patients with cryptogenic stroke. Whereas aging with its changes in right atrial pressure is an infrequent confounding factor not found to be significantly associated with cryptogenic strokes, the patient who presents with pulmonary embolus, right ventricular infarction or severe tricuspid regurgitation will have an elevated right-to-left shunt through a PFO.⁷

More recently, pelvic vein thrombi have been reported to be found in young cryptogenic stroke patients compared to those with known causes of stroke.¹⁵ Since these veins are rarely studied in such patients, their consideration as a contributing factor must also be borne in mind. Patients with a *hypercoagulable state* have also been defined within the cohorts of cryptogenic stroke.¹⁶ The higher frequency of prothrombotic states associated with G20210A and factor V Leiden mutations in patients with cryptogenic stroke and PFO suggests a contributory mechanism to the suspected paradoxical embolization.¹⁶

RECURRENT STROKE PREVENTION AND TREATMENT

The focus of medical treatment for cryptogenic stroke is to prevent recurrent events. Such therapy has employed anti-thrombotic (warfarin and antiplatelet) regimens, and surgical and device closures of PFO or ASD. Whereas a summary of medical therapy studies following cryptogenic stroke patients (N=943) for a mean duration of 33 months found the annual rate of recurrent stroke to be 1.98% and stroke or death at 3.12 %, these studies are confounded by different age groups.⁷ In a retrospective analysis from the PFO in Cryptogenic Stroke Study (PICSS), the presence of a PFO in younger cryptogenic stroke patients did not seem to increase the risk of adverse events, but significantly increased events in older patients.¹⁷ Thus, age is an important confounding factor. Only one study has randomized patients to warfarin or aspirin therapy, and found no difference in event rates.⁹ There exists no randomized controlled prospective trials examining the effects of aspirin and/or clopidogrel versus warfarin in cryptogenic stroke patients, and although such therapy is commonly employed, definitive data do not exist. Because of the known major bleeding risk of warfarin at 1 to 2 % annually, and minor bleeding risk of 10 to 20 %, empiric therapy today has commonly employed

aspirin and clopidogrel strategies.⁷

Surgical closure studies of PFO and ASD in the literature have examined less than 200 patients and have defined the annual rate of recurrent stroke as <0.34% and stroke or death <1.0%.⁷ Nevertheless, the development of percutaneous closure devices have seemingly obviated the need for surgery with its attendant morbidity and cost, even considering minimally invasive techniques.¹⁸ Thus, attention has focused on the use of transcatheter closure devices (e.g. Amplatzer, CardioSeal and StarFlex devices) to occlude the interatrial communication of PFO and ASDs. These devices in over 1400 patients followed showed an annual rate of recurrent stroke of 0.19% and stroke or death of 1.15%.⁷ Complications from such devices include major events such as death, hemorrhage, cardiac tamponade and fatal pulmonary emboli, and are estimated to occur in ~1.5% of patients.⁷ It is intuitive that this latter figure is highly dependent on the emergence of varied new and sub-optimal devices, as well as lack of experience in some operators. Minor complications of atrial arrhythmias, device embolization, device thrombosis, ECG changes, and arteriovenous fistula formation are reported in 7.9%.¹⁹

There are 3 ongoing randomized studies in the United States comparing the efficacy of percutaneous closure with medical therapy in cryptogenic stroke patients. The Randomized Evaluation of Recurrent Stroke Comparing PFO Closure to Established Current Standard of Care Treatment (RESPECT) trial randomizes cryptogenic stroke patients with PFO to percutaneous closure with an Amplatzer device or medical therapy (antiplatelet or warfarin at the enrolling physician's discretion). The CLOSURE I trial randomizes patients with stroke or transient ischemic attack (TIA) thought to be due to paradoxical embolization to percutaneous closure with the STARFlex septal occluder or medical therapy (aspirin and/or warfarin at the enrolling physician's discretion). The Cardia PFO trial randomizes patients to PFO closure using its PFO closure device or warfarin. The Amplatzer device is also used in Europe and Australia in the Patent Foramen Ovale and Cryptogenic Embolism PC-trial. This study randomizes cryptogenic stroke patients with PFO to device closure or medical therapy (antiplatelet or warfarin at the enrolling physician's discretion). Finally, the CLOSEUP (Closure Using Premere) trial will be using a new PFO closure device (Premere) and similarly randomize patients to percutaneous device closure or medical therapy. Of note, in all trials, patients randomized to the device arm also receive medical therapy for a variable period of time, in some cases for the study duration. These studies seek to demonstrate the superiority of device plus medical therapy over medical therapy alone.

THE CLINICIAN'S VIEW

Cryptogenic stroke (i.e. without apparent cause or source) is predominantly a disorder of middle-aged and younger persons (<55 years). When it occurs in older individuals (>55

years) a search for aortic arch atheroma and arteriosclerotic disease is indicated. But the vast majority of such strokes occur in younger individuals, where the most prevalent suspected etiology is the mechanism of paradoxical embolism through an interatrial abnormality (PFO or ASD). Investigation by transcranial Doppler or TEE with saline venous infusion (bubble study) are the diagnostic methods of choice to lead the investigation. Definition of the atrial anatomy and other factors contribute to the probability of the suspected paradoxical embolism. Treatment with modern anti-thrombotic therapy (i.e. aspirin and clopidogrel) currently seems warranted as a first-line of defense to prevent recurrent stroke, particularly in view of the long-term cost and morbidity of warfarin therapy in this predominantly young patient group. Subsequently, second-line referral of patients with large PFOs, and identified atrial abnormalities (i.e. large defects, prominent Eustachian valve or Chiari network or filamentous strands or ASA) for transcatheter closure to an experienced center seems indicated according to the results of non-randomized studies and by expert consensus. Lastly, referral for participation in prospective randomized clinical trials employing both medical therapy and closure devices should be supported for those individuals whose clinical features do not predominantly argue for the mechanism of paradoxical embolization to help define the best treatment to prevent recurrent stroke.

MIGRAINE HEADACHE

THE CLINICAL PROBLEM

Migraine is a common disorder, with a one-year prevalence rate in Americans of approximately 13% (18% of women and 6 to 7% of men).²⁰ Migraine is thus about three times more common in women than men. It tends to run in families, and typically it is a disorder of young, primarily healthy women. Migraine without aura is the most common type, accounting for approximately 80% of all migraine sufferers. Nonpharmacologic modalities, such as regular exercise, relaxation, stress management, biofeedback, ice massage, physical therapy techniques, and others may play an important role in both the prophylactic and abortive treatment of migraine, although the data are somewhat limited.²¹ Migraine is thought to have a polygenetic and multifactorial etiology.²² No consistent genetic basis has been established for migraine, with the exception of familial hemiplegic migraine.

THE PATHOPHYSIOLOGY

No single theory or hypothesis can explain all of the phenomena that occur with migraine. The once popular vascular theory of migraine, which suggested that vascular headaches such as migraine and cluster headaches were caused by the dilatation of blood vessels, while the aura of migraine resulted from vasoconstriction, is no longer considered viable in its

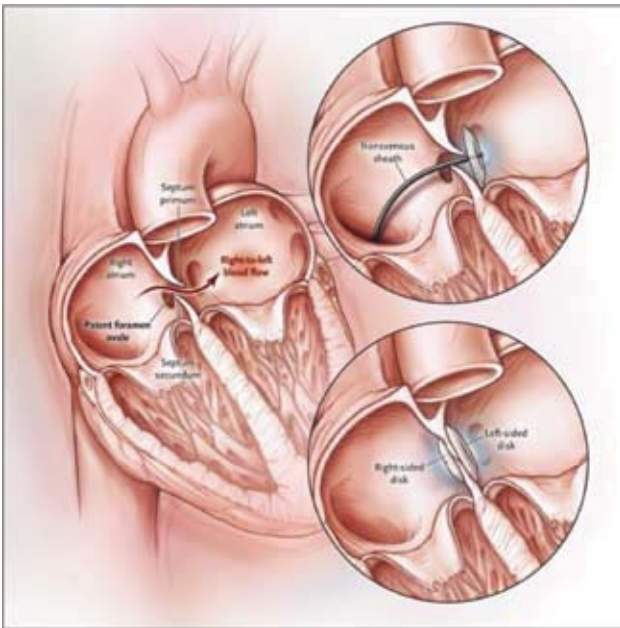


FIGURE 1. Percutaneous Closure of a Patent Foramen Ovale.

With use of a femoral approach, a transvenous sheath is advanced across the foramen into the left atrium, where a folded disk is expanded and pulled back, apposing the primum and secundum septa closed. This step is followed by deployment of a right-sided disk, at which time the two-disk device is released. Clopidogrel and aspirin are recommended for a period of three months to prevent thrombus formation on the device, with aspirin therapy continued for an additional three months, when endothelialization is complete. Antibiotic prophylaxis for six months is recommended. Complete late closure of the foramen has been reported in 80 to 95% of patients. [Reproduced with permission from *N Engl J Med* 2005; 353:2368 (ref. 6)].

original form. Nevertheless, it may well be that vasodilatation plays an important role in the severe throbbing head pain that is characteristic of migraine; vasodilatation itself is probably an epiphenomenon, resulting from instability in the central neurovascular control mechanism.²³

The current state of knowledge in this field suggests that a primary neuronal dysfunction leads to a sequence of changes intracranially and extracranially that account for migraine, including the three phases of prodrome, aura, and headache.²⁴ Individuals prone to migraine have a genetic migrainous threshold that renders them susceptible to an acute migraine attack depending upon the balance between excitation and inhibition at various levels of the nervous system. Both genetic and environmental factors are important.²⁵

Serotonin (released from brainstem serotonergic nuclei) also plays an important role in the pathogenesis of migraine; this is probably mediated via its direct action upon the cranial vasculature, through its role in central pain control pathways

and through cerebral cortical projections of brainstem serotonergic nuclei.²⁶ The exact mechanism of serotonin action remains obscure. A decline in serotonergic function has been noted during acute migraine attacks, resulting in vasodilation of cranial vessels and sensitization of meningeal afferents of the trigeminal nerve.²⁷ Between attacks, patients who have migraine without aura appear to have increased brain serotonin synthesis.²⁸

More recently, migraine with aura has been linked to right-to-left cardiac shunts, usually in the setting of a patent foramen ovale (PFO) or, much less often, an atrial septal defect (ASD).^{29,30} In a study of 581 cryptogenic stroke patients, migraine was more common in the 46% of patients with PFO than those without PFO (27% versus 14%).³⁰ In other reports, patients with migraine associated with aura were more likely to have a PFO than patients with migraine without aura or controls.^{31,32}

The mechanism of the association between right-to-left cardiac shunt and migraine is not known. One theory is that the venous circulation contains vasoactive substances (e.g. serotonin) capable of triggering migraine; these are normally inactivated in the lungs but gain access to the cranial circulation in the presence of a right-to-left shunt.²⁴ However, a recently favored hypothesis is that the existence of a right-to-left shunt provides a pathway for paradoxical embolism of microemboli (1 to 3 mm) and subsequent cerebral ischemia, which in turn triggers migraine. This hypothesis is aided by a recent study which demonstrated a 13.7-fold higher incidence of MRI lesions in migraine patients with aura than in controls.³⁴

Moreover, recent clinical studies of cryptogenic stroke patients with migraine, strongly attest to the benefit of PFO or ASD closure in the resolution or improvement of symptoms in migraine patients.^{30,32,33} Migraine headache has been defined in 35 to 42 % of cryptogenic stroke patients, with as many as two-thirds of those patients experiencing migraine with aura.^{30,33} Complete resolution of migraine symptoms following closure of the PFO or ASD in patients with migraine and aura has been found to occur in 56 to 75 % of such patients.^{30,33} The association of migraine and PFO is even stronger in patients with PFO and atrial septal aneurysm.²⁹

In the recently reported Migraine Intervention with Starflex Technology (MIST) trial,³⁵ patients, aged 18 to 60 years, with a one-year documented history of migraine with aura occurring at least 5 times per month were studied. Additional selection criteria of failed medication from two classes of prophylactic medications and at least 7 days free of headache per month were required. Screening of 432 patients resulted in identifying 147 patients, 84% women, mean age 44 years, who were randomized to PFO closure with the STARFlex Septal Repair Implant (n=74) or a sham procedure (control group; n=73). Patients but not physicians were blinded to randomized treatment. Patients were followed for 6 months regarding migraine frequency and severity, during which patients were

treated with aspirin and clopidogrel for the first 3 months. Exclusions from the trial included migraine medication overuse, prior stroke/TIA and cardiac anomaly contraindications.

The principal findings showed among the 432 patients screened in the trial, 60.2% had an atrial right-to-left shunt, much higher than typically found in the general population (i.e. ~27%). A large atrial shunt was present in 37.7% of patients, with a small shunt in 16.7% and no shunt in 39.8%.³⁵ The mean diameter of PFO in the trial was 9.21 mm. There was no difference between groups in the primary endpoint of complete cessation of migraines, with 3 patients in each group meeting this criterion. Reduction in headache-days by at least 50% occurred more frequently in the PFO closure group (42% vs 23%, $p=0.038$). The reduction in headache burden, defined as the frequency x duration of headache, was greater (37% vs 14%) in the PFO closure group (from 136.1 at baseline to 86.06 at follow-up, $p=0.033$ in PFO group; from 116.8 at baseline to 96.32 at follow-up, $p=NS$ in control group). Thus among migraine sufferers screened for enrollment in the trial, PFO closure was not associated with a difference in total migraine resolution compared with a sham procedure. While the primary endpoint did not differ by treatment group, reduction of headache frequency by 50% occurred more frequently in the PFO group. This endpoint is not as rigid as the total elimination endpoint but would be clinically important to patients experiencing migraines. The on-going MIST II trial will evaluate PFO closure for migraine improvement but will incorporate a longer patient follow-up, with the hypothesis that much of the benefit may emerge later following PFO closure.

THE CLINICIAN'S VIEW

Whereas medical therapy of migraine is beyond the scope of this presentation, in the patient with migraine, the possibility of a PFO or ASD with paradoxical embolism must be strongly considered as a pathologic mechanism. This is particularly true when the migraine is accompanied by an aura. Diagnostic studies should include a transcranial Doppler study with venous saline injection (bubble study), or a transesophageal echocardiogram with venous saline injection (preferably from the femoral vein whose flow is directed into the area of potential PFO). Definition of other risk factors associated with paradoxical embolism (e.g. a gradient favoring right to left shunt, presence of Eustachian valve or Chiari strands) should heighten one's suspicion that closure of an interatrial communication could render substantial benefit in alleviating the occurrence of migraine, and lead to a resolution or marked decrease in symptoms.

Currently, definitive evidence from prospective randomized clinical trials establishing the benefit of PFO or ASD closure for migraine headache is still lacking. The results of the first such randomized trial (MIST) were initially presented at the ACC Meeting (March 2006)³⁵ and just recently published.³⁶ The MIST trial studied 147 patients with migraine and a PFO

who were randomly assigned to sham treatment ($n=73$) or PFO closure ($n=74$). At 6 months 50% reduction in headache-days frequency was achieved by 42% of patients who had the PFO closed versus 23% in the sham arm. However, the primary end-point, complete elimination of headache, was achieved by only 3 patients in each group. More randomized trials, such as the MIST-2, ESCAPE (Effect of Septal Closure of Atrial PFO on Events of Migraine with Premere), FORMAT (Patent Foramen Ovale Closure to Reduce Migraine Attacks), and the PREMIUM trial (Prospective Randomized Investigation to Evaluate Incidence of Headache Reduction In Subjects with Migraine & PFO Using the Amplatzer PFO Occluder Compared to Medical Management) are currently in progress, which are anticipated to render further knowledge about the benefit of percutaneous PFO closure on the occurrence and severity of migraine headaches.

REFERENCES

1. Leys D, Bandu L, Henon H, et al. Clinical outcome in 287 consecutive young adults (15 to 45 years) with ischemic stroke. *Neurology* 2002;59:26-33.
2. DeRook FA, Comess KA, Albers GW, Popp RL. Transesophageal echocardiography in the evaluation of stroke. *Ann Intern Med* 1992;117:922-932.
3. Lechat P, Mas JL, Lascault G, et al. Prevalence of patent foramen ovale in patients with stroke. *N Engl J Med* 1988;318:1148-1152.
4. The French Study of Aortic Plaques in Stroke Group. Atherosclerotic disease of the aortic arch as a risk factor for recurrent ischemic stroke. *N Engl J Med* 1996;334:1216-1221.
5. Amarenco P. Cryptogenic stroke, aortic arch atheroma, patent foramen ovale, and the risk of stroke. *Cerebrovasc Dis* 2005; 20(suppl 2):68-74.
6. Kizer JR, Devereux RB. Patent foramen ovale in young adults with unexplained stroke. *N Engl J Med* 2005; 353:2361-2372.
7. Homma S, Sacco RL. Patent foramen ovale and stroke. *Circulation* 2005;112:1063-1072.
8. Kerut EK, Norfleet WT, Plotnick GD, Giles TD. Patent foramen ovale: A review of associated conditions and the impact of physiological size. *J Am Coll Cardiol* 2001;38:613-623.
9. Homma S, Sacco RL, Di Tullio MR, et al. Effect of medical treatment in stroke patients with patent foramen ovale: patent foramen ovale in cryptogenic stroke study. *Circulation* 2002; 105:2625-2631.
10. Steiner MM, Di Tullio MR, Rundek T, et al. Patent foramen ovale size and embolic brain imaging findings among patients with ischemic stroke. *Stroke* 1998;29:944-948.
11. Mattioli AV, Bonetti L, Aquilina M, Oldani A, Longhini C, Mattioli G. Association between atrial septal aneurysm and patent foramen ovale in young patients with recent stroke and normal carotid arteries. *Cerebrovasc Dis* 2003;15:4-10.
12. Fox ER, Picard MH, Chow CM, Levine RA, Schwamm L, Kerr AJ. Interatrial septal mobility predicts larger shunts across pa-

- tient foramen ovale: an analysis with transmitral Doppler scanning. *Am Heart J* 2003;145:730-736.
13. Schuchlenz HW, Saurer G, Weihs W, Rehak P. Persisting Eustachian valve in adults: relation to patent foramen ovale and cerebrovascular events. *J Am Soc Echocardiogr* 2004;17:231-233.
 14. Schneider B, Hofmann T, Justen MH, Meinertz T. Chiari's network: normal anatomic variant or risk factor for arterial embolic events? *J Am Coll Cardiol* 1995;26:203-210.
 15. Cramer SC, Rordorf G, Maki JH, et al. Increased pelvic vein thrombi in cryptogenic stroke. Results of the Paradoxical Emboli From Large Veins in Ischemic Stroke (PELVIS) Study. *Stroke* 2004;35:56-50.
 16. Pezzini A, Del Zotto E, Magoni M, et al. Inherited thrombophilic disorders in young adults with ischemic stroke and patent foramen ovale. *Stroke* 2003;34:28-33.
 17. Homma S, Di Tullio MR, Sacco RL, et al. Age as a determinant of adverse events in medically treated cryptogenic stroke patients with patent foramen ovale. *Stroke* 2004;35:2145-2149.
 18. Deeik RK, Thomas RM, Sakiyalak P, Botkin S, Blakeman B, Bakhos M. Minimal access closure of patent foramen ovale: is it also recommended for patients with paradoxical embolism? *Ann Thorac Surg* 2002;74:S1326-S1329.
 19. Khairy P, O'Donnell CP, Landzberg MJ. Transcatheter closure versus medical therapy of patent foramen ovale and presumed paradoxical thromboemboli: a systematic review. *Ann Intern Med* 2003;139:753-760.
 20. Lipton, RB, Stewart, WF, Diamond, S, et al. Prevalence and burden of migraine in the United States: data from the American Migraine Study II. *Headache* 2001; 41:646.
 21. Pryse-Phillips, WE, Dodick, DW, Edmeads, JG, et al. Guidelines for the nonpharmacologic management of migraine in clinical practice. *CMAJ* 1998; 159:47.
 22. Ducros, A, Tournier-Lasserre, E, Bousser, MG. The genetics of migraine. *Lancet Neurol* 2002; 1:285.
 23. Welch, KM. Drug therapy of migraine. *N Engl J Med* 1993; 329:1476.
 24. Langemark, M, Olesen, J. Drug abuse in migraine patients. *Pain* 1984; 19:81.
 25. Gervil, M, Ulrich, V, Kaprio, J, et al. The relative role of genetic and environmental factors in migraine without aura. *Neurology* 1999; 53:995.
 26. Martignoni, E, Solomon, S. The complex chronic headache, mixed headache and drug overuse. In: Olesen, J, Tfelt-Hansen, P, Welch, KM (Eds). *The Headaches*. Raven, New York, 1993, p. 849.
 27. Winner, P, Ricalde, O, Le Force, B, et al. A double blind study of sub-cutaneous dihydroergotamine vs subcutaneous sumatriptan in the treatment of acute migraine. *Arch Neurol* 1996; 53:180.
 28. Chugani, DC, Niimura, K, Chaturvedi, S, et al. Increased brain serotonin synthesis in migraine. *Neurology* 1999; 53:1473.
 29. Lamy, C, Giannesini, C, Zuber, M, et al. Clinical and imaging findings in cryptogenic stroke patients with and without patent foramen ovale: the PFO-ASA Study. *Atrial Septal Aneurysm. Stroke* 2002; 33:706.
 30. Arzabal B, Tobis J, Suh W, et al. Association of interatrial shunts and migraine headaches. Impact of transcatheter closure. *J Am Coll Cardiol* 2005;45:489-492.
 31. Anzola, GP, Magoni, M, Guindani, M, et al. Potential source of cerebral embolism in migraine with aura: a transcranial Doppler study. *Neurology* 1999; 52:1622.
 32. Reisman M, Christofferson RD, Jesurum J, et al. *J Am Coll Cardiol* 2005;45:493-495.
 33. Meier, B, Lock, JE. Contemporary management of patent foramen ovale. *Circulation* 2003; 107:5.
 34. Kruit MC, van Buchem MA, Hofman PA, et al. Migraine as a risk factor for subclinical brain lesions. *JAMA* 2004; 291:427-434.
 35. Wilmshurst P, Dowson A. Presented at the 2006 i2 Summit Annual Scientific Sessions of the American College of Cardiology, Atlanta, GA, March 13, 2006.
 36. Dowson A, Mullen MJ, Peatfield R, et al. Migraine Intervention With STARFlex Technology (MIST) Trial: a prospective, multicenter, double-blind, sham-controlled trial to evaluate the effectiveness of patent foramen ovale closure with STARFlex septal repair implant to resolve refractory migraine headache. *Circulation* 2008;117:1397-1404.