

CASE REPORT

Right External Iliac Vein Thrombosis After Percutaneous Transluminal Coronary Angioplasty

Andreas Mazarakis, MD & Nikolaos Karouzos, MD

*Cardiology Division, Patras University
Hospital, Rio, Patras, Greece*

KEY WORDS: *coronary angiography;
coronary angioplasty; iliac vein
thrombosis*

LIST OF ABBREVIATIONS:

CT = computed tomography
PTCA = percutaneous transluminal
coronary angioplasty

Correspondence to:
Andreas Mazarakis, MD
Patras University Hospital
Rio, Patras, Greece
E-mail: andreasazarakis@hotmail.com

ABSTRACT

We herein present a rare case of iliac vein thrombosis occurring late at 4 days after discharge following a percutaneous coronary intervention in a patient with no evidence of a thrombophilic state.

INTRODUCTION

Coronary arteriography and angioplasty are common and routine procedures and various vascular complications, usually at the access site, may occur. However, they commonly involve the arterial branches which are the vessels being punctured. We herein report a rare complication of an iliac vein thrombosis occurring late after a percutaneous coronary intervention.

CASE REPORT

We present a 43-year-old patient with an acute anterior myocardial infarction, who sought medical advice 24 hours after the initial episode of chest pain. Chest pain lasted for about 4 hours and then subsided. The patient was admitted to the coronary care unit of our hospital 24 hours after the initial insult. He was clinically stable without chest pain, dyspnea, or palpitations. He was a rather thin young gentleman (body mass index of 21), current heavy smoker, and was receiving non-steroidal anti-inflammatory medications for recent back pain. He was started on tirofiban, aspirin, clopidogrel (300 mg loading dose), β -blocker and an angiotensin converting enzyme inhibitor. At 52 hours later since the initial episode he was subjected to coronary angiography.

We followed the standard procedure, obtaining access from the right femoral artery and employing the Judkins technique. Coronary angiography revealed a 95% proximal stenosis of the left anterior descending artery, the rest of the coronary anatomy being normal. During the same session the patient was subjected to coronary angioplasty (PTCA) and coronary stenting with a 3.5/11 mm dexamethasone-covered stent, with an excellent result (0% residual stenosis, TIMI-III flow). The femoral access site was

sealed with a mechanical clip with use of a vascular closure system (Starclose, Abott Laboratories, Illinois, USA) and local pressure dressing was applied for 12 hours. The patient was hospitalized for 3 consecutive days and was discharged home on standard medications, without any complications.

Four days after discharge from the hospital, the patient returned complaining of numbness and heaviness at the right groin. On examination there was no edema, or hematoma, nor any murmur at the right femoral access site. However, when he was subjected to a Doppler ultrasound examination of the right lower extremity, a significant stenosis of the right external iliac vein was disclosed, possibly due to thrombosis. Following that, a venogram was conducted, which revealed a significant (90%) longitudinal stenosis of the right external iliac vein towards the common femoral vein (Figure 1). Blood samples were drawn for thrombophilia screening and the patient was started on low molecular weight heparin. After 4 days he was subjected to an abdominal multislice CT angiography, which disclosed patency of the iliac veins. The standard thrombophilia screening was negative. One month later the patient remained asymptomatic, while repeat Doppler examination of the right external iliac vein was normal.

DISCUSSION

We consider this case interesting as it is a quite uncommon complication of invasive angiography. Actually after a thorough Medline search, we were not able to find any similar cases of spontaneous iliac vein thrombosis after coronary or other arterial angiography using the right femoral artery access technique. There are a few reports in the literature of femoral vein thrombosis due to compression from a femoral artery pseudoaneurysm; however, our case represent spontaneous vein thrombosis.¹ We do not have an adequate explanation for this complication, although we suspect that it may be related to external compression of the femoral access site with

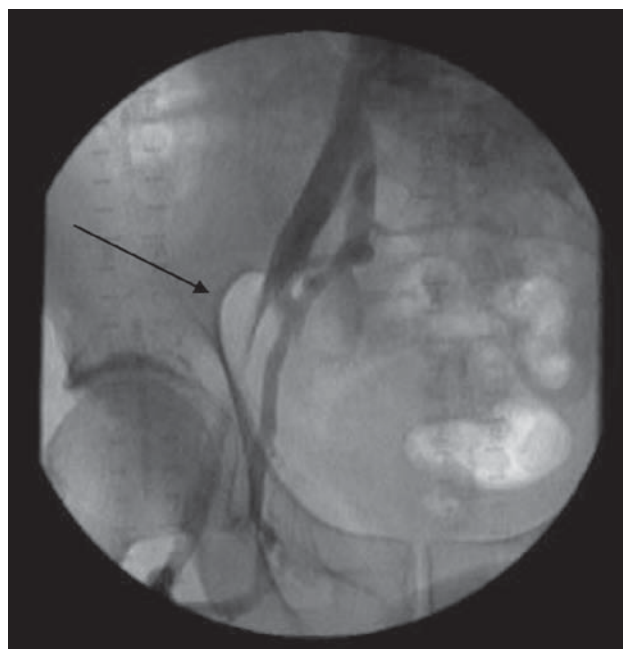


FIGURE 1. Significant longitudinal stenosis (90%) of the right external iliac vein (arrow), from the level of the internal iliac up to the common femoral vein.

a bandage for 12 hours. The latter is standard procedure in our department and it would be interesting to follow up patients with Doppler ultrasonography to study the possible subclinical incidence-if there is any- of this condition.

REFERENCE

1. Slyska R, Mondek P, Lofaj P, Sefranek V. Post-catheterization pseudoaneurysm of the femoral artery--an unusual cause of femoral vein thrombosis--case report and review of the literature. *Rozhl Chir* 2004; 83(3):113-117.