

ORIGINAL ARTICLE

Pre-Procedural Transesophageal Echocardiography Underestimates Atrial Septal Defect Size Compared to the Balloon Sizing Technique

Spyridon Koulouris, MD, Pantelis Gounopoulos, MD,
Socrates Pastromas, MD, John Pyrros, MD,
Konstantinos Kappos, MD, Antonis S. Manolis, MD

First Department of Cardiology,
Evangelismos General Hospital
of Athens, Athens, Greece

KEY WORDS: atrial septal defect;
Amplatzer septal occluder; quantitative
cineangiography; intracardiac
echocardiography

LIST OF ABBREVIATIONS

ASD: Atrial septal defect
2D-TEE: Two dimensional – transesophageal
echocardiography
3D-TEE: Three dimensional –
transesophageal echocardiography
ICE: Intracardiac echocardiography
QCA: Quantitative cineangiography

Correspondence to:
Spyridon Koulouris, MD
64 Kekropos street
151 25 Marousi, Athens, Greece
Tel. +30-210-6148740
+30-6944-194545
E-mail:
spyridon.koulouris@gmail.com

*Manuscript received September 7, 2010;
Accepted after revision October 22, 2010*

ABSTRACT

BACKGROUND: Secundum-type atrial septal defects (ASD) are increasingly being treated with percutaneous placement of occluding devices. Accurate sizing of the ASD is mandatory for subsequent optimal selection of the device. We sought to compare the two most commonly used methods, 2-dimensional transesophageal echocardiography (2D-TEE) and stretched- balloon sizing.

METHODS: Sixteen patients (8 men and 8 women) aged 53.8 ± 9.8 years with ASD were scheduled for implantation of an Amplatzer septal occluder device. The procedure was performed with the use of local only anesthesia via the right femoral vein with fluoroscopic guidance alone and without the intra-procedural use of 2D-TEE. The size of the defect was measured with 2D-TEE prior to the procedure. In the catheterization laboratory the ASD size was measured again with the insertion of a sizing balloon inflated with diluted contrast agent until a waist appeared. Waist dimensions were measured using cineangiographic quantitation (QCA) software.

RESULTS: All ASDs were successfully closed with Amplatzer occluders. A significant correlation was found between echocardiographic and fluoroscopic measurements of the ASD size ($r=0.863$, $p=0.000$). However, most of the echocardiographic measurements underestimated ASD diameters compared with conventional QCA balloon sizing by a mean of 3 mm (16.46 ± 5.93 mm vs 19.83 ± 6.3 mm, $t= 4.18$, $p= 0.001$). The Bland-Altman analysis evidenced a lack of agreement between echocardiographic and balloon sizing with 95% limits of agreement between 2.9 and -9.7 mm.

CONCLUSIONS: Atrial septal defects can be treated safely and effectively with the percutaneous placement of an Amplatzer septal occluder device via a simple percutaneous technique with use of local anesthesia and fluoroscopy alone without a need for intra-procedural 2D-TEE. Although the use of pre-procedural 2D-TEE has been a common practice for establishing the diagnosis and offering an initial assessment of the size of the defect, it largely underestimates the latter. The single-plane fluoroscopic balloon sizing performed during the procedure seems indispensable for choosing an occluding device of appropriate size.

INTRODUCTION

Surgical closure of atrial septal defects (ASD) has been performed for decades and has been associated with very low morbidity and mortality rates. On the other hand, the placement of closure devices percutaneously via the femoral vein has also been used as an easy alternative approach for several years. Indeed, nowadays, ASDs are increasingly being treated by percutaneous techniques^{1,2} and the placement of a closure device is now considered as the treatment of choice with excellent sealing rates of the defect³. Accurate sizing of the ASD is mandatory for subsequent optimal selection of the device and can be done either by echocardiographic measurements (transthoracic, transesophageal or intracardiac) or with the use of sizing balloons in the catheterization laboratory. The stretched balloon measurement of the ASD diameter through fluoroscopy is considered the gold standard among them. Nevertheless, even though balloon sizing is the method preferred by most, an initial assessment of the ASD with echocardiography is usually performed in every candidate for percutaneous closure of the defect prior to the procedure. There have been numerous discussions about the potential of

relying on echocardiography alone since this would reduce both the time and the cost of the procedure, but there has been no general consensus on this issue. We sought to evaluate two dimensional transesophageal echocardiography (2D-TEE) multi-plane measurement in comparison to single-plane fluoroscopic balloon sizing of the ASD in patients undergoing this procedure in our center.

PATIENTS AND METHODS

STUDY POPULATION

Between July 2006 and June 2010, 16 patients with solitary secundum-type ASD had a cardiac catheterization for closure of their defect with an Amplatzer Septal Occluder (AGA Medical Corp., Plymouth, MN) in our department. The patients' characteristics are shown in Table 1. Most of them underwent the procedure due to a left-to-right shunt with a Qp/Qs ratio of ≥ 1.5 (n= 13). In all subjects, measurements of ASD diameters by TEE before closure were compared with fluoroscopic balloon sizing. For the procedure an informed written consent was obtained from each patient. The study

TABLE 1. Clinical, echocardiographic and procedural characteristics of the study population

n	Age (years)	Gender	Symptoms	Indication for the procedure	Echo Size (mm)	Balloon Size (mm)	Closure Device	Months of follow-up
1	63	M	SOB	ASD, Qp/Qs: 2.5:1	16.00	20.000	Amplatzer 24	62.00
2	31	F	SOB	ASD, Qp/Qs: 1.5:1	12.50	13.800	Amplatzer 16	53.00
3	44	F	fatigue	ASD, Qp/Qs: 3.3:1	19.00	26.00	Amplatzer 32	51.00
4	49	M	DOE	ASD, Qp/Qs:1.8:1	21.00	26.00	Amplatzer 28	45.00
5	65	F	palpitations/PAF	ASD, Qp/Qs: 2:1	12.00	20.00	Amplatzer 22	45.00
6	66	F	fatigue/migraine	ASD, Qp/Qs: 3:1	24.00	22.80	Amplatzer 24	45.00
7	55	F	SOB	ASD, Qp/Qs 2.1:1	18.00	19.00	Amplatzer 22	37.00
8	37	M	SOB/weakness	ASD	18.00	15.50	Amplatzer 18	36.00
9	53	F	presyncope/weak	ASD, Qp/Qs 1.7:1	15.00	18.00	Amplatzer 22	27.00
10	59	M	SOB	ASD,Qp/s1.6:1	5.00	7.80	Amplatzer 10	23.00
11	63	M	CVA, DOE	ASD, CVA, Qp/s1.5:1	16.00	15.50	Amplatzer 20	21.00
12	51	F	fatigue/DOE	ASD, RVE/PHTN,	7.00	12.00	Amplatzer 16	20.00
13	54	M	CVA, DOE	ASD, RVE/PHTN	11.50	20.00	Amplatzer 24	8.00
14	61	M	dizzy spells	ASD, Qp/s: 2:1	27.00	31.00	Amplatzer 36	5.00
15	54	M	fatigue	ASD, Qp/s: 1.6:1	17.00	20.00	Amplatzer 24	4.00
16	57	F	SOB	ASD, RVE/PHTN, Qp/s: 2.5:1	24.00	30.00	Amplatzer 32	0.00

F: female, M: male, DOE: dyspnea on exertion, PAF: paroxysmal atrial fibrillation, SOB: shortness of breath, CVA: cerebrovascular accident, ASD: atrial septal defect, RVE; right ventricular enlargement, PHTN: pulmonary hypertension.

was approved by the Ethics Committee of our institution.

TRANSESOPHAGEAL ECHOCARDIOGRAPHY

Standard 2D-TEE was performed with a Philips iE 33 ultrasound unit (Philips Medical Systems, Bothel, Washington, USA) to diagnose secundum type ASDs, exclude additional congenital malformations and ascertain that the rims were sufficient for a closure device placement. Standard ASD measurements were carried out in the bicaval view at 60-70 degrees and in basal short axis view. The maximum diameter was taken into account.

FLUOROSCOPIC BALLOON SIZING AND PERCUTANEOUS DEVICE CLOSURE TECHNIQUE

In our laboratory, the procedure of percutaneous ASD closure is routinely performed with use of local only anesthesia via the right femoral vein with fluoroscopy guidance alone and without the intra-procedural use of TEE. All patients received aspirin and clopidogrel for at least 3 days prior to the procedure, and prophylactic antibiotic is administered intravenously one hour prior to the scheduled procedure.

Via a right femoral venous approach, the patients were catheterized and the ASD size was measured with standard sizing balloons with diameters between 20 and 34 mm in the left anterior oblique view with slight cranial angulation (30 degrees left anterior oblique/20 degrees cranial). Sizing balloons were centered in the ASD, aiming to position the distal half of the balloon in the left atrium and the proximal half in the right atrium. The balloon was inflated with diluted contrast agent until a waist appeared. Waist dimensions were measured using cineangiographic quantitation (QCA) software. The procedure was repeated up to two times depending on how well the waist was visualized. After device selection based on balloon measurement of ASD size, a suitable Amplatzer septal occluder (AGA Medical Corp., Plymouth, MN) was selected oversized by 2-4 mm and deployed via the special delivery system. The day following the procedure 2D-TEE was repeated to check for device position and any residual shunt or other peri-procedural complications. All patients were discharged home at 48 hours with aspirin and clopidogrel for 6 months. This regimen was adopted taking into consideration its safety and efficacy from the wide experience from coronary artery disease. At 6 months all patients underwent a repeat 2D-TEE

STATISTICAL ANALYSES

Data are expressed as mean \pm standard deviation. Agreement between methods was evaluated using paired *t* test and Pearson correlation. Calculations were based on a type I error level of 5%. Data were analyzed with SPSS 18 for Windows (SPSS Inc., Chicago, IL). Moreover, since a high correlation does not automatically imply that there is good agreement between two methods we performed also a Bland-Altman

analysis to calculate the limits of agreement with the use of the statistical package MedCalc Software (Mariakerke, Belgium).

RESULTS

All ASDs were successfully closed with use of Amplatzer occluders. One patient developed a transient paroxysm of atrial fibrillation with no other periprocedural complications noted. At 2 weeks post-procedurally the same patient developed a brief episode of paroxysmal nocturnal dyspnea managed with diuretic without further recurrences. At 6 months after the implantation one patient had a large residual shunt and at attempting to place a new closure device, the device migrated into the pulmonary artery and was successfully recaptured with a percutaneous technique. The patient was subsequently scheduled and underwent surgery 3 months later with successful closure of the ASD. Small residual shunting was noted in another patient at the 6-month follow-up TEE, who was managed conservatively. All other patients reported no symptoms at a mean follow-up of 30.12 ± 4.86 months.

With regards to the measurements of the ASD size obtained with the TEE and the stretched balloon technique, a significant correlation was found between echocardiographic and fluoroscopic measurements ($r=0.863$, $p=0.000$) (Figure 1). However, most of the echocardiographic measurements underestimated ASD diameters compared with conventional QCA balloon sizing (16.46 ± 5.93 mm vs 19.83 ± 6.3 mm, $t=4.18$, $p=0.001$) (Figure 2).

Moreover, the limits of agreement between the two methods calculated with the Bland-Altman analysis, were found be-

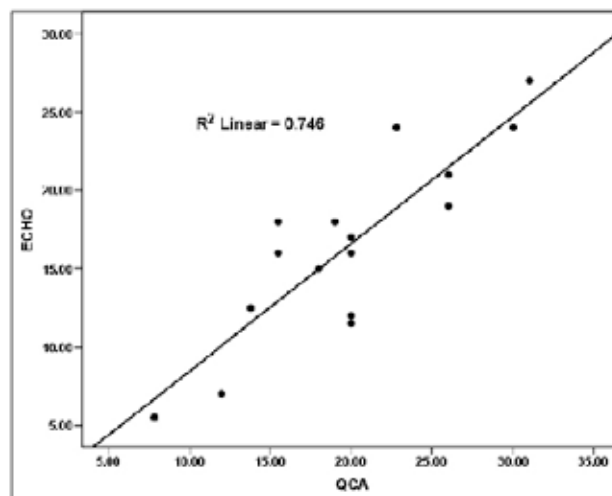


FIGURE 1. Correlation between fluoroscopic (QCA) and echocardiographic (ECHO) measurements.

TEE VS BALLOON SIZING FOR ASD MEASUREMENT

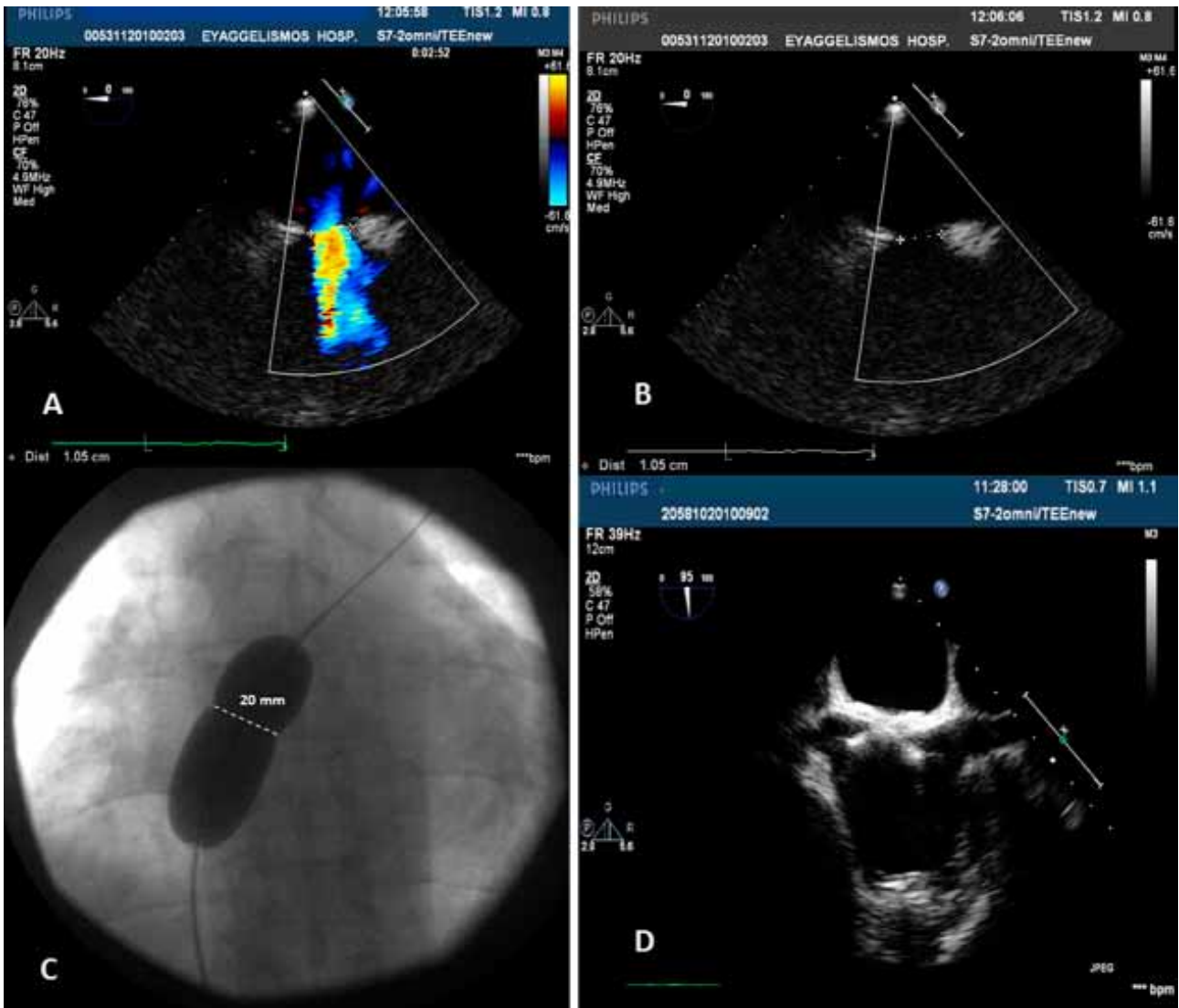

FIGURE 2. Atrial septal defect measured as 10.5 mm in diameter by 2-D TEE with (panel A) and without color Doppler (panel B) in patient No 13. In the same patient, the size of the defect was calculated at 20 mm with the stretching balloon technique in the catheterization laboratory. A 24 mm Amplatzer septal occluder was successfully implanted in the patient. TEE at 6 months showed no residual shunt. At 8 months of follow-up, the patient remains asymptomatic.

tween 2.9 and -9.7 mm. That means that 2D-TEE measurement may be 2.9 mm above or 9.7mm below the number obtained from Balloon sizing. This is a fairly wide difference suggesting a lack of agreement between the 2 methods (Figure 3).

DISCUSSION

The present study showed that 2D- TEE systematically underestimates stretched ASD size by at least 3 mm. This is reasonable since balloon-sizing technique usually stretches the true anatomical septal shunt measured by TEE. Two-

dimensional TEE provides information about the structure of ASD but only one cross-sectional image at a time so it can underestimate the ASD size^{4,5} if the probe is not aligned with the longest diameter of the defect. In addition, ASD changes in shape and size throughout the cardiac cycle and also membranous tissue usually rounds the defect and can easily be stretched if a balloon stretches leading to a significant increase in the true diameter as assessed by the balloon method. Taking this assumption into consideration a study Carcagni et al⁶ introduced a new echocardiographic diameter. Apart from the classic anatomic diameter measured by 2D-TEE, they also measured the procedural ASD diameter, using

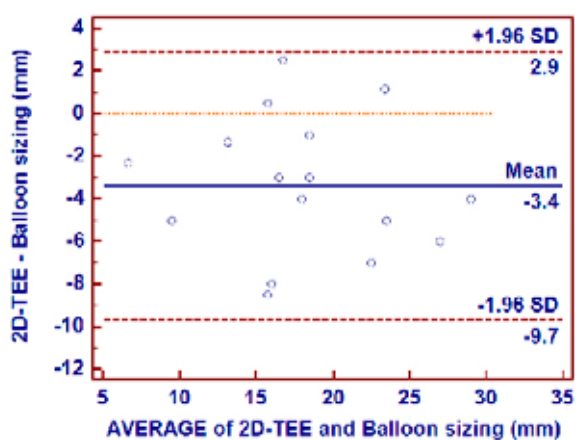


FIGURE 3. Bland-Altman plot indicating the limits of agreement between 2-D TEE and Balloon sizing.

as borders of the true defect the points where the thickness of the rims was 2.5 mm. This value was chosen from an in vitro observation of the thickness of the rim at the time the sizing balloon is inflated and the stretched balloon diameter is measured. In this study which included 40 patients a good correlation between procedural ASD diameter and stretched balloon diameter was found ($r=0.99$). The authors suggested that procedural diameter is easily measured, applicable to all echocardiographic techniques without additional cost.

We used the static balloon technique⁷ in which a sizing balloon catheter is advanced over the wire across the defect, and inflated with dilute contrast medium until the balloon has a definite waist that is visible on fluoroscopy. The balloon indentation can be measured by QCA as the stretched-balloon-diameter by fluoroscopy.⁸ The same stretched-diameter can be measured by 2D-TEE only if the examination is performed simultaneously with cardiac catheterization. The usual practice is to select a device 2–4 mm larger than the stretched ASD diameter. Devices smaller than the stretched ASD size cannot be deployed safely. However, issues about accuracy of balloon sizing emerge when the balloon is oblique through the defect or distends the rims.

Others have suggested that three-dimensional transesophageal echocardiography (3-D TEE) can offer a better visualization of the anatomy of the ASD, can give accurate assessment of the true anatomical size, can assess tissue surrounding the defect, and can follow its size during the cardiac cycle, providing a far better image of the defect. Even more it can further assist in the measurement during the stretching of the balloon. In the study of Maeno et al⁹ both 2-D and the 3-D TEE measurements are lower than the stretching balloon values, with the 3-D TEE measurements having the minimal mean difference between the two. In a previous study¹⁰ no differences were observed between 3-D and stretching bal-

loon measurements. Limitation of the 3-D TEE measurement technique can be considered the time consuming process and the possibility of not capturing the region of interest during data acquisition, especially during the measurement of the stretched ASD when inflation of the balloon occurs. In addition, the need for general anesthesia with or without intubation and the prolonged radiation exposure should always be taken into consideration.

Intracardiac echocardiography (ICE) has been used for guiding the sizing balloon and the closure devices during the procedures. A recent study¹¹ evaluated the single-plane balloon stretching sizing by ICE compared with the gold standard of fluoroscopy measurement. It was shown that ICE systematically underestimated the stretching balloon diameter by less than 1mm. Use of ICE may limit the radiation, the time of the procedure and the need for sedation and can always guide the sizing balloon in the center of the defect for offering more accurate values. The major limitations seem to be the single-plane view of the measurement allowing frequent underestimation of the size, the lack of color Doppler capability and the high cost of the catheters. Another study which compared 3-D TEE both with 2-D TEE and ICE suggested that the former is more likely to give larger long-axis dimension and smaller short-axis dimension when compared with both the 2-D TEE and the ICE.¹²

Finally, phase-contrast magnetic resonance imaging offers an alternative way of noninvasive method to ASD sizing, especially in children with inconclusive echocardiographic results.¹³

Complications of the balloon sizing technique are rare in general. Oversizing of the balloon, repeated inflation or employment of the pull-through technique instead of the static one may end to tear of the atrium septum and lead to device embolization or entrapment. It has been suggested¹⁴ that inflation of the sizing balloon until flow through the shunt is diminished results in potentially fewer complications.

LIMITATIONS OF THE STUDY

This study was not a randomized controlled trial. It was rather our experience in our ASD closure program based on a small series of patients. This represents a major limitation in addition to the fact that the operators performed real time calculations and not off-line analysis. Nevertheless, they were blinded to each other's measurements. Absolute concentricity was not always achievable by balloon inflation and this represents another limitation since a slight underestimation of the balloon sizing might have occurred in some cases. On the other hand, overstretching of the balloon and "over-sizing" of the defect might have not been avoided in some other patients. However, almost all patients received a device of appropriate diameter since only one distal migration and no aortic erosions occurred. The absence of intra-procedural TEE that might have helped us to reduce the complication

rate (2 residual shunts) should also be noted. Finally, we should emphasize that although a calculation taking into account the thickness of the rim of the ASD might have led to a better correlation with the balloon measurements, applying it to all ASDs was not always feasible probably due to individual anatomical variability.

CONCLUSIONS

Atrial septal defects have been treated in our cases safely and effectively with the percutaneous placement of an Amplatzer septal occluder device via a simple percutaneous technique with use of local anesthesia and fluoroscopy alone without a need for intra-procedural 2-D TEE. Although the use of pre-procedural 2D-TEE has been a common practice for establishing the diagnosis and offering an initial assessment of the size of the defect, it largely underestimates the latter. The single-plane fluoroscopic balloon sizing performed during the procedure seems indispensable for choosing an occluding device of appropriate size.

REFERENCES

1. Fischer G, Stieh J, Uebing A, Hoffmann U, Morf G, Kramer HH. Experience with transcatheter closure of secundum atrial septal defects using the Amplatzer septal occluder: A single center study in 236 consecutive patients. *Heart* 2003;89:99-104.
2. Wang JK, Tsai SK, Wu MH, Lin MT, Lue HC. Short- and intermediate-term results of transcatheter closure of atrial septal defect with the Amplatzer Septal Occluder. *Am Heart J* 2004;148:511-517.
3. Du ZD, Hijazi ZM, Kleinman CS, Silverman NH, Lantz K. Amplatzer Investigators Comparison between transcatheter and surgical closure of secundum atrial septal defect in children and adults *J Am Coll Cardiol* 2002;39:1836-1844.
4. Das GS, Voss G, Jarvis G, K Wyche, R Gunther, RF Wilson. Experimental atrial septal defect closure with a new, transcatheter, self-centering device. *Circulation* 1993; 88:1754-1764.
5. Lock JE, Rome JJ, Davis R, Van Praagh S, Perry SB, Van Praagh R, et al. Transcatheter closure of atrial septal defect: experimental studies. *Circulation* 1989; 79:1091-1099.
6. Carcagni A, Presbitero P. New echocardiographic diameter for Amplatzer sizing in adult patients with secundum atrial septal defect: preliminary results. *Catheter Cardiovasc Interv* 2004; 62:409-414.
7. Gu X, Han YM, Berry J, Urness M, Amplatz K. A new technique for sizing of atrial septal defects. *Catheter Cardiovasc Interv* 1999;46:51-57.
8. Manolis AS, Andrikopoulos G, Tzeis S, Amorgianos D, Pyrros I. Percutaneous closure of a large atrial septal defect: a simplified approach. *Hosp Chronicles* 2006;1:186-187.
9. Zhu W, Cao QL, Rhodes J, Hijazi ZM. Measurement of atrial septal defect size: A comparative study between three-dimensional transesophageal echocardiography and the standard balloon sizing methods. *Pediatr Cardiol* 2000; 21:465-469.
10. Maeno YV, Benson LN, Boutin C. Impact of dynamic 3-D transesophageal echocardiography in the assessment of atrial septal defects and occlusion by the double-umbrella device. *Cardiol Young* 1998; 8:368-378.
11. Bartel T, Konorza T, Barbieri V, Erbel R, Pachinger O, Muller S. Single-plane balloon sizing of atrial septal defects with intracardiac echocardiography: An advantageous alternative to fluoroscopy. *J Am Soc Echocardiogr* 2008; 21:737-740.
12. Lodato JA, Cao QL, Weinert L, Sugeng L, Lopez J, Lang RM. Feasibility of real-time three-dimensional transoesophageal echocardiography for guidance of percutaneous atrial septal defect closure. *Eur J Echocardiogr* 2009;10:543-548.
13. Beerbaum P, Körperich H, Esdorn H, Blanz U, Barth P, Hartmann J, et al. Atrial septal defects in pediatric patients: noninvasive sizing with cardiovascular MRI imaging. *Radiology* 2003;228: 361-369.
14. Carlson KM, Justino H, O'Brien RE, Dimas VV, Leonard GT Jr, Pignatelli RH, et al. Transcatheter atrial septal defect closure: modified balloon sizing technique to avoid overstretching the defect and oversizing the Amplatzer septal occluder. *Catheter Cardiovasc Interv* 2005;66:390-396.