

IMAGES IN MEDICINE

Mid-Ventricular Obstructive Hypertrophic Cardiomyopathy

Charalampos Charalampous, MD, Konstantinos P. Letsas, MD,
Efstathia Prappa, MD

*Second Department of Cardiology,
Evangelismos General Hospital of
Athens, Athens, Greece*

A 72-year-old woman was referred to our hospital because of an episode of syncope. She had been diagnosed as having hypertrophic cardiomyopathy for 12 years. Lately, she had experienced occasional episodes of dizziness, exertional dyspnea and palpitations. Physical examination revealed a midsystolic murmur. A 12-lead ECG showed ST-segment elevation in leads II, III, aVF, and V3 through V6 along with negative T waves (Figure 1). Markers of myocardial necrosis were within normal values. Coronary angiography revealed no stenosis. Twenty-four-hour Holter electrocardiographic monitoring revealed paroxysmal ventricular contractions (500/day). Transthoracic echocardiography showed asymmetric septal hypertrophy (the end-diastolic thickness of the septum was 24 mm, compared with 9 mm for the posterior wall), mid-ventricular obstruction during systole, an apical aneurysm and moderate mitral regurgitation (Fig. 2). Left ventricular ejection fraction was 40%. Continuous-wave Doppler echocardiography revealed a peak flow velocity of 2.0 m/sec in early systole, which corresponded to a pressure gradient of 16 mmHg between the apical and basal sites of the left ventricle. Tissue Doppler imaging echocardiography showed abnormal relaxation.

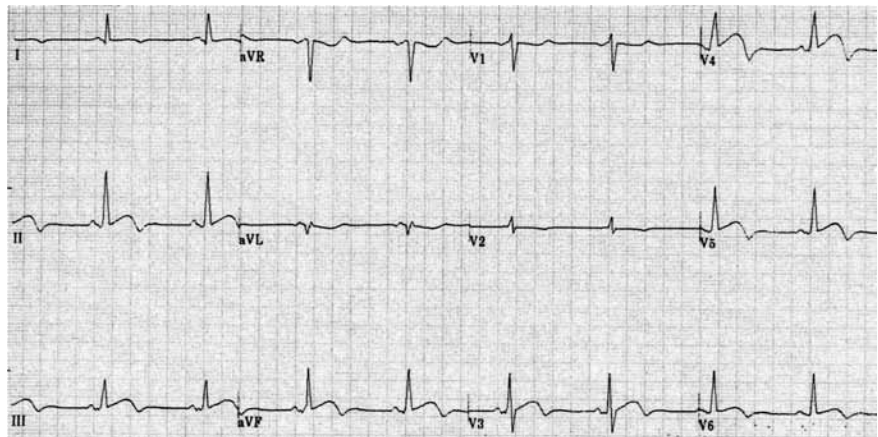


FIGURE 1. Twelve-lead ECG showing ST-segment elevation in leads II, III, aVF and V3 through V6 along with negative T waves.

Correspondence to:
Charalampos Charalampous, MD
Second Department of Cardiology
Evangelismos General Hospital of
Athens
Athens 106 76, Greece
Fax: +302107217687
e-mail: harrishgr@yahoo.gr

*Manuscript received September 6, 2010;
Accepted after revision October 17, 2010*

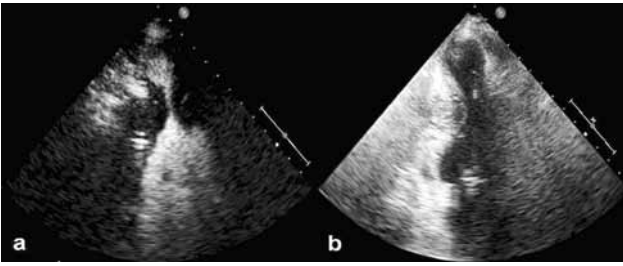


FIGURE 2. Transthoracic echocardiography with (a) and without (b) contrast showing mid-ventricular obstruction and an apical aneurysm.

•••

Mid-ventricular obstructive hypertrophic cardiomyopathy is a rare form of hypertrophic cardiomyopathy (1%). It is characterized by the presence of pressure gradient between apical and basal sites in the left ventricle, asymmetric left ventricular hypertrophy and it is frequently associated with an apical aneurysm.¹⁻⁴ The formation of a left ventricular apical aneurysm has been associated with a high incidence of sustained ventricular tachycardia in patients with hypertrophic cardiomyopathy because of local ischemic phenomena.⁵ The management of mid-ventricular obstructive hypertrophic cardiomyopathy is unclear, but failure to intervene can result in fatal ventricular arrhythmias and sudden death. Beta-

blockers are the first choice of treatment in these patients. Dual-chamber pacing and percutaneous myocardial alcohol ablation have been proposed as non-surgical treatments for mid-ventricular obstructive hypertrophic cardiomyopathy, but long-term benefits await further observations in large patient populations. Our patient was treated with a β -blocker and received an implantable cardioverter-defibrillator.

REFERENCES

1. Akutsu Y, Shinozuka A, Huang TY, et al. Hypertrophic cardiomyopathy with apical left ventricular aneurysm. *Jpn Circ J* 1988;62:127-131.
2. Harada K, Shimizu T, Sugishita Y, et al. Hypertrophic cardiomyopathy with midventricular obstruction and apical aneurysm: a case report. *Jpn Circ J* 2001;65:915-919.
3. Ito N, Suzuki M, Enjoji Y, et al. Hypertrophic cardiomyopathy with mid-ventricular obstruction complicated with apical left ventricular aneurysm and ventricular tachycardia: a case report. *J Cardiol* 2002;39:213-219.
4. Tse HF, Ho HH. Sudden cardiac death caused by hypertrophic cardiomyopathy associated with midventricular obstruction and apical aneurysm. *Heart* 2003;89:178.
5. Alfonso E, Frenneaux M, Mc Kenna W. Clinical sustained uniform ventricular tachycardia in hypertrophic cardiomyopathy: Association with left ventricular apical aneurysm. *Br Heart J* 1989;61:178-181.