

CASE REPORT

Bidirectional Ventricular Tachycardia

Georgios Th. Nikitas, MD, Athanasios G. Manolis, MD,
Evangelos Papamatthaiou, MD, Maria Petritou, MD, Kostas Kouvelas, MD
and Zenon S. Kyriakides, MD

ABSTRACT

Bidirectional ventricular tachycardia (VT) is a form of tachycardia with alteration of the QRS axis in the same electrocardiographic lead. We present a case of bidirectional VT recorded in a female patient under chronic digitalis treatment and respiratory acidosis.

2nd Cardiology Department, Hellenic Red Cross Hospital, Athens, Greece

KEY WORDS: *ventricular tachycardia*

INTRODUCTION

Bidirectional ventricular tachycardia (VT) is a rare form of tachycardia with 1:1 alteration of the QRS axis in the same electrocardiographic lead. It may represent a stage between a single morphology VT and a multiform fascicular rhythm. This type of VT generally develops as consequence of digitalis toxicity or in patients with catecholaminergic polymorphic VT.¹ The electrophysiological mechanism of bidirectional tachycardia remains controversial.² Yet, there is convincing evidence of ventricular origin of the tachycardia with either two or more separate foci, or a single focus with alternating aberrant conduction in the anterior and posterior fascicle of the left bundle branch, with the underlying mechanism suggested to be triggered activity or abnormal automaticity, while reentry is generally considered as the least probable mechanism.³⁻⁵

ABBREVIATIONS

VT = ventricular tachycardia

CASE PRESENTATION

A 78-year-old female patient was hospitalized suffering from ongoing dyspnea due to respiratory infection culminating into acute pulmonary edema. The patient had a past medical history of congestive heart failure with an estimated left ventricular ejection fraction of 30-35%, chronic atrial fibrillation, diabetes mellitus, arterial hypertension and Alzheimer's disease.

At the time of first evaluation, the patient had a high ventricular response of 140-150 bpm and a marginally low systolic arterial pressure despite previous treatment with digitalis, and she was treated with intravenous digoxin (0.25 mg daily), together with intravenous furosemide (40 mg daily). No evidence of myocardial ischemia was detected (serum troponin I, 0.03 ng/ml). Despite adequate medical treatment and oxygen therapy, the clinical condition of the patient deteriorated. On the fourth day of hospitalization she developed respiratory failure with acidosis (pH 7.21, PaO₂ 52 mmHg, PaCO₂ 58 mmHg) but without hemodynamic compromise requiring inotropic

Correspondence to:
Georgios T. Nikitas, MD
4 Fotomara street
11743 Athens, Greece
Tel.: +30-6944474796
Fax: +30-210-9218126
E-mail: lagandia@hotmail.com

*Manuscript received July 28, 2010;
Accepted after revisions September 26,
2010*

BIDIRECTIONAL VENTRICULAR TACHYCARDIA

support. Subsequently, she was intubated and transferred to the intensive care unit for mechanical respiratory support and monitoring.

An hour after intubation, an episode of bidirectional VT was recorded, at a rate of about 170 bpm, wide (120 ms) QRS complexes and 1:1 bidirectional appearance of the QRS axis in the limb leads (Figure 1). The duration of the tachycardia was less than 3 minutes and it was self-terminated. A standard regimen of intravenous esmolol was subsequently implemented to prevent possible recurrence of the tachycardia and digitalis was discontinued, while no additional treatment was considered necessary since the VT was self-terminated. The digitalis serum level was slightly below the upper normal limit (2.1 ng/ml) with therapeutic levels, according to the local laboratory, ranging between 0.8 and 2.2 ng/ml. Serum levels of serum magnesium (1.66 mEq/dl), potassium (4.2 mEq/l) and creatinine (1.1 g/dl) were all within normal range, with an estimated creatinine clearance at 73 ml/min, using the Cockcroft and Gault equation. The post-VT electrocardiogram showed atrial fibrillation at a mean rate of 55 beats per minute and the QT interval was measured at 440 ms. Two days later the patient was extubated and transferred to the medical ward from the intensive care unit. No recurrence of the VT was recorded in the ensuing days of hospitalization.

patient during hospitalization in the intensive care unit while receiving digitalis. The serum digitalis level was toxic according to the latest guidelines for acute and chronic heart failure¹¹ (although at the upper therapeutic levels according to the local laboratory) and the clinical presentation of intoxication was the emergence of bidirectional VT. The concomitant use of antibiotics for the treatment of respiratory infection might have contributed to the increase of the digitalis serum levels by eliminating gut flora that metabolize digitalis.¹² In this situation we should also take into consideration the respiratory acidosis that might have predisposed the calcium -overloaded ventricular myocytes to delayed afterdepolarisations and therefore arrhythmogenesis by triggered activity.^{6,7,13} By current means the definition of toxic digitalis levels remains elusive and serum digitalis concentration does not serve as a reliable indicator of toxicity.⁸ Digitalis-induced bidirectional VT carries bad prognosis and requires acute discontinuation of the drug and, if it is considered necessary and the tachycardia is not self terminated, the administration of Fab-fragment antibodies will be necessitated.^{8,9} An alternative therapeutic countermeasure would be to increase the serum potassium levels to the upper range. In our patient discontinuation of digitalis was effective enough, together with the beta-blocker administration and the reversal of respiratory failure and concomitant acidosis.

DISCUSSION

We present a case of bidirectional VT recorded in a female

REFERENCES

1. Richter S, Brugada P. Bidirectional ventricular tachycardia. *J*

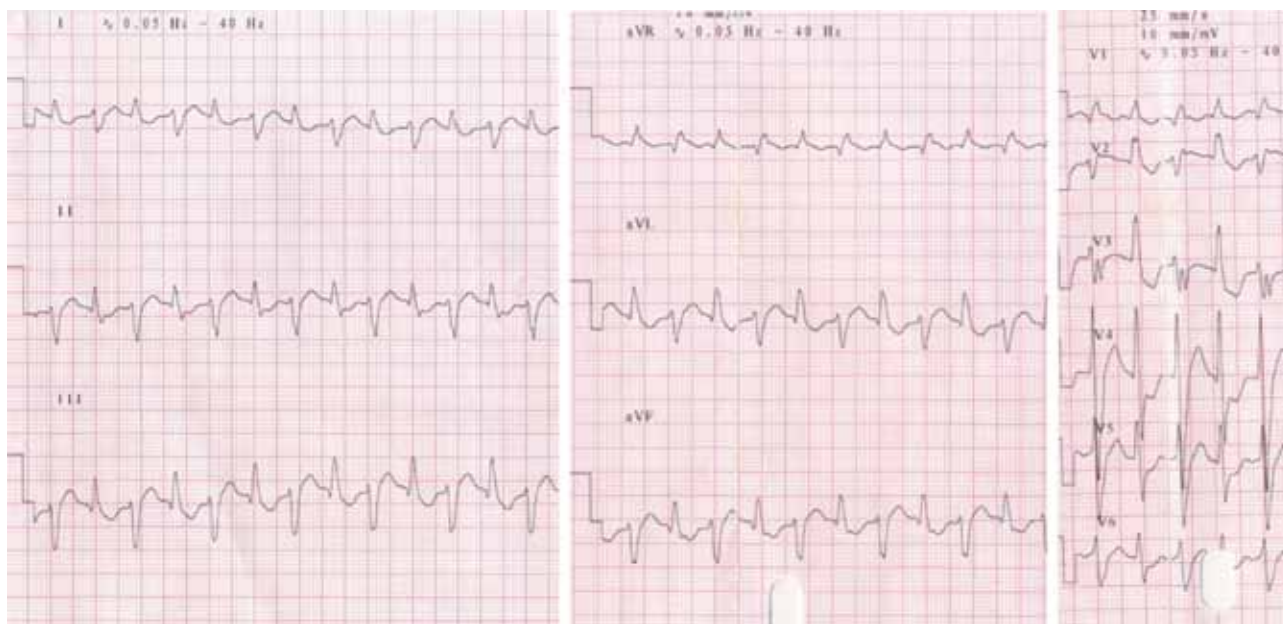


FIGURE 1. Bidirectional ventricular tachycardia at a rate of about 170 bpm, with frontal QRS axis alternation.

- Am Coll Cardiol* 2009;54:1189.
2. Rosenbaum MB, Elizari MV, Lazzari JO. The mechanism of bidirectional tachycardia. *Am Heart J* 1969; 78:4-12.
 3. Cohen SI, Deissenrotz A, Hecht HS. Infra-His bundle origin of bidirectional tachycardia. *Circulation* 1973; 47:1260-1266.
 4. Morris SN, Zipes DP. His bundle electrocardiography during bidirectional tachycardia. *Circulation* 1973;38:32-36.
 5. Cohen HC, Gozo EG Jr, Pick A. Ventricular tachycardia with narrow QRS complexes (left posterior fascicular tachycardia). *Circulation* 1972; 45:1035-1043.
 6. Ferrier GR. Digitalis arrhythmias: Role of oscillatory afterpotentials. *Prog Cardiovasc Dis* 1977; 19:459-474.
 7. Gi-Byoung Nam, Burasnicov A, Antzelevitch C. Cellular mechanisms underlying the development of catecholaminergic ventricular tachycardia. *Circulation* 2005; 111:2727-2733.
 8. Kelly RA, Smith TW. Recognition and management of digitalis toxicity. *Am J Cardiol* 1992; 69:108G-118G.
 9. Wieland JM, Marchlinski FE. Electrocardiographic response of digoxin-toxic fascicular tachycardia to Fab fragments: Implications for tachycardia mechanisms. *PACE* 1986; 9:727-738.
 10. Antman EM, Wenger TL, Butler VP Jr, et al. Treatment of 150 cases of life threatening digitalis intoxication with digoxin specific Fab antibody fragments: Final report of a multicenter study. *Circulation* 1990; 81:1744-1752.
 11. ESC Guidelines for the diagnosis and treatment of acute and chronic heart failure 2008. *Eur Heart J* 2008; 29:2388-442.
 12. ACC/AHA/ESC 2006 guidelines for management of patients with ventricular arrhythmias and the prevention of sudden cardiac death. *Europace* 2006; 8:746-837.
 13. Zimdahl WT, Townsend CE. Bidirectional ventricular tachycardia due to digitalis poisoning: Response to potassium therapy and evaluation of arrhythmia mechanism. *Am Heart J* 1954; 47:304-312.