

ATHENS CARDIOLOGY UPDATE 2010

Hypertrophic Obstructive Cardiomyopathy and Severe Mitral Regurgitation due to Chordae Tendineae Rupture. An Unusual Coexistence

Eleni M. Kalkandi, MD, Eirini A. Andrikou, MD,
Athanasios I. Kranidis, MD

Department of Cardiology, Western
Attica General Hospital, Athens,
Greece

CASE REPORT

A 60-year-old gentleman came to the cardiac emergency room of our hospital complaining of a 3-day long shortness of breath and orthopnea. The patient gave a history of prior diagnosis of hypertrophic obstructive cardiomyopathy (HOCM) a few years back, while he had been treated with a beta-blocker (metoprolol 50 mg bid). Until 3 days ago, he was in functional class NYHA II. In addition, he noted weakness and postprandial chest discomfort over the last week. The patient also had a history of hyperlipidemia treated with statins and he had undergone surgery for peptic ulcer 10 years earlier.

The clinical evaluation of the patient revealed a grade 4/6 pansystolic murmur at the apex with a radiation to the axilla and normal first and second heart sounds. The auscultation of the lungs showed only few basal rales, while the arterial blood pressure was 90/60 mmHg. The ECG showed sinus rhythm at 58 bpm, left ventricular hypertrophy and negative T waves in precordial leads V4-6. The chest X-ray showed normal cardiothoracic index and interstitial edema. The patient underwent transthoracic echocardiography revealing a left ventricle of normal size with asymmetric hypertrophy involving mainly the interventricular septum (IVS), the anterior and lateral wall (maximal IVS thickness ~21mm). There was an increased left ventricular filling pressures ($E/E' = 24$, where E was the early transmitral velocity and E' was the velocity (tissue Doppler imaging-TDI) of the atrioventricular movement of the left ventricle. The mitral valve presented myxomatous degeneration – thick and elongated leaflets – while the anterior leaflet showed systolic anterior motion (SAM) to the hypertrophic IVS causing dynamic left ventricular outflow tract obstruction (LVOT) [$V_{max} \sim 4$ m/s, max gradient= 64 mmHg and after an ectopic ventricular beat $V_{max} \sim 4.8$ m/s]. There were two jets of mitral regurgitation, one towards the posterior wall of the left atrium and the other towards the atrial septum and the total mitral regurgitation was considered to be at least moderately severe. Because of significant calcification of the posterior mitral annulus, full detection of the anatomy of mitral leaflets was difficult. The left atrium was dilated (55 mm) and the right chambers had a normal size. Since there was a little tricuspid valve regurgitation, it was possible to evaluate the systolic pressure of the right ventricle/pulmonary artery, which was found to be significantly increased (~70 mmHg).

KEY WORDS: *hypertrophic
obstructive cardiomyopathy;
mitral valve myxomatous degeneration*

Correspondence to:
Athanasios I. Kranidis, MD
E-mail: kranidis1@ath.forthnet.gr

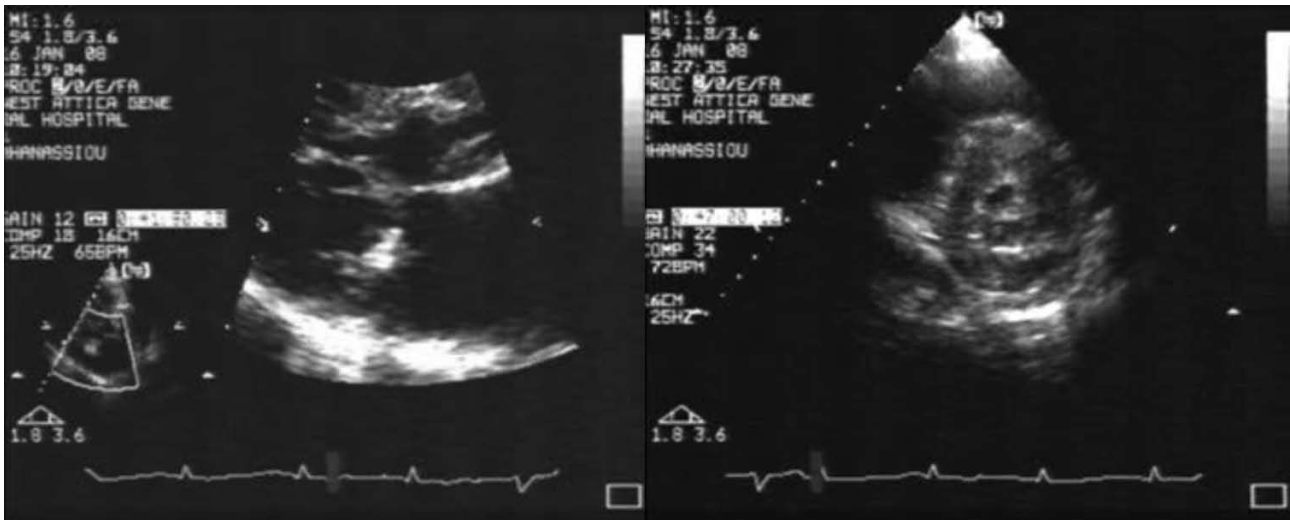


FIGURE 1. Parasternal echocardiographic view, left: long-axis view, systolic anterior motion (SAM) of the mitral valve, right: short-axis view, asymmetric left ventricular hypertrophy.

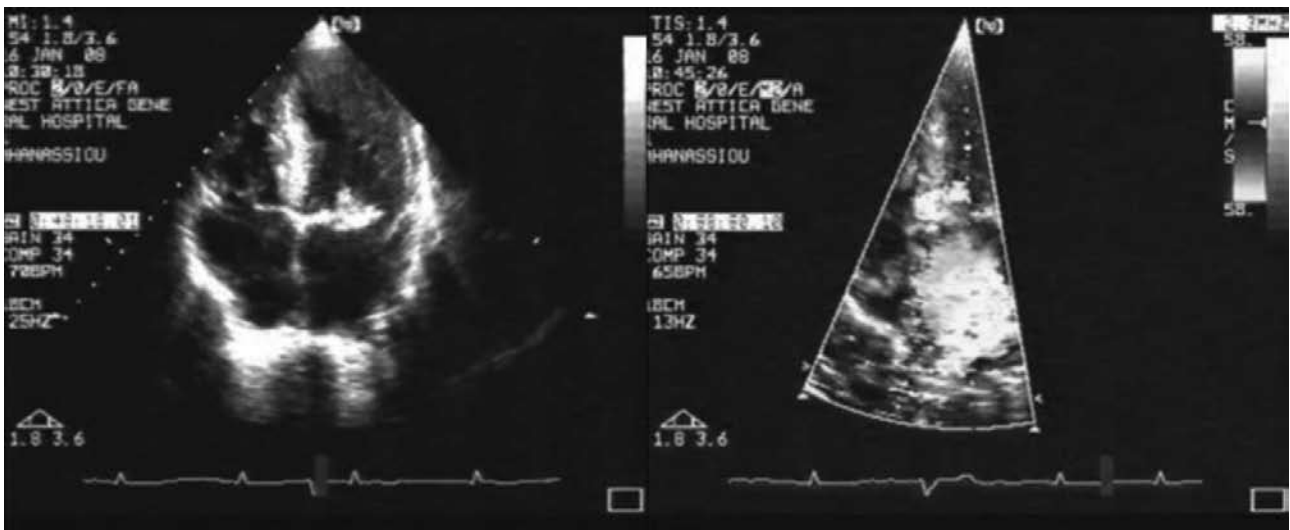


FIGURE 2. Apical four-chamber view, right: the mitral regurgitation towards the atrial septum

Due to the existence of two jets of mitral regurgitation and the lack of full clarification of the mitral valve anatomy, the patient underwent transesophageal echocardiography study. The latter was able to detect the origin of the jets, therefore, the jet towards the posterior wall of the left atrium was caused by the SAM of the mitral valve leaflet, while the one towards the atrial septum was created by the flail posterior leaflet – medial segment (P2) – because of the chordae tendineae rupture. The regurgitation was deemed severe, while the pulse wave Doppler recorded systolic reversal of flow of the right superior pulmonary vein. The asymmetrical hypertrophy of

the left ventricle was confirmed by its dynamic outflow tract obstruction.

The patient after a brief clinical stabilization period using medical treatment, underwent coronary angiography, which revealed no significant coronary artery disease. After that, he underwent surgical operation namely myectomy according to the Morrow procedure and mitral valve replacement using Carbomedics No 29. The patient had a good postoperative course and the postoperative transthoracic echocardiography demonstrated a well-functioning prosthetic mitral valve without left ventricular outflow tract obstruction.

DISCUSSION

Hypertrophic cardiomyopathy (HCM), in its main morphological features, is characterized by left ventricular hypertrophy (usually asymmetric and with a wide range of phenotypic expression), as well as by accompanying structural abnormalities of the mitral apparatus. Dynamic left ventricular outflow tract obstruction occurs in a percentage ~70%, either spontaneously or evoked. This is due to the systolic anterior motion of mitral valve mechanism (SAM) to the hypertrophic intraventricular septum (IVS), resulting in even greater narrowing of an already small anatomic left ventricular outflow tract (LVOT). The reasons for the SAM may be the Venturi effect in the LVOT or even the violent displacement of mitral apparatus in the LVOT as a result of the ejection. The nature of the obstruction is dynamic and should be provoked by manoeuvres (body position, Valsalva manoeuvre, inhalation of amyl nitrite). The SAM, with the attendant obstruction to the LVOT, is responsible for causing mitral regurgitation, whose nature is dynamic and its usual direction is towards the posterior and lateral wall of the left atrium (97%). The symptomatology of patients – and their resulting functional class – varies, since it is related not only to the degree of the obstruction, but also to the degree of the endogenously existing left ventricular diastolic dysfunction (due to the nature of the disease). The medical treatment of these patients with negative inotropic drugs (beta-blockers, non-dihydropyridines calcium channel blockers) reduces the degree of the obstruction, the consequential mitral regurgitation and improves their symptoms.

Regarding the abnormalities of the mitral apparatus – according to data from autopsy studies and from patients who underwent surgery – they appear to be common in hypertrophic cardiomyopathy (in approximately 2/3 of patients) and even more frequent in the obstructive type. They include abnormality in the size and shape of mitral leaflets or/and abnormal insertion of papillary muscle directly to the anterior leaflet of the valve, contributing to the provocation of mitral regurgitation. In a large series of patients with HCM, treated surgically, between the years 1986-2003 (Kaple et al., *Ann Thorac Surg* 5/2008), retrogressive changes of mitral valve were found in a percentage 31%, myxomatous degeneration of mitral valve 20%, abnormal papillary muscle 20%, short chorda tendinea 19%, short leaflet 70%, long leaflet 56%.

The rupture of chordae tendineae – of the posterior leaflet mainly – constitutes a rare but existing complication. Clinically, patients hardly tolerate the acute mitral regurgitation caused by the rupture, since these patients have left ventricular diastolic dysfunction, increased left ventricular filling pressures and increased pressure in the left atrium. Therefore, it is important, in these patients, to recognize the nature of mitral regurgitation in order to implement the right

treatment. In functional mitral regurgitation due to the SAM, treatment with negative inotropic drugs improves the clinical condition of the patient. On the other hand, regurgitation of anatomical cause requires surgical intervention with repair or replacement of mitral valve. In HCM, without major anatomical mitral regurgitation, surgical intervention is implemented only in the obstructive type – with myectomy – in patients who are intolerant of the commendable pharmaceutical treatment and remain in a high NYHA functional class, despite the best arrangement of their medication. However, this refers to a small percentage of patients. It is, therefore, essential to identify the nature of mitral regurgitation in the obstructive type of HCM. It requires high clinical suspicion in order to recognize the anatomical nature of the regurgitation caused by chordae tendineae rupture and usually the diagnosis is based on the sudden clinical deterioration of a previously clinically stable patient and on the echocardiographic features of mitral regurgitation (direction of the jet, anatomy of the valve). In such cases, it is imperative the patient undergo a surgery with myectomy and repair or replacement of the valve.

In conclusion, it seems that the recognition of the mechanism causing mitral regurgitation in patients with HOCM, especially in symptomatic ones, is of fundamental importance. The presence of mitral regurgitation, with jet directed towards the anterior atrium wall, as recognized echocardiographically, is unusually associated with functional regurgitation – due to the SAM – but it must raise the suspicion of flail mitral leaflet. Transesophageal echocardiography study contributes in particular to the identification and evaluation of this pathological situation, requiring immediate surgery.

REFERENCES

1. Yeo TC, Miller FA, Oh JK, et al. Hypertrophic Cardiomyopathy with obstruction: important diagnostic clue provided by the direction of the mitral regurgitation. *J Am Soc Echocardiogr* 1998; 11:61-65.
2. Zhu WX, Oh JK, Kopecky SL, et al. Mitral regurgitation due to ruptured chordae tendineae in patients with hypertrophic obstructive cardiomyopathy. *J Am Coll Cardiol* 1992; 20:242-247.
3. Hozumi T, Yoshikawa J, Yoshida K, Yamaura Y, et al. Direct visualization of ruptured chordae tendineae by transesophageal echocardiography. *J Am Coll Cardiol* 1990; 16:1315-1319.
4. Yonezawa Y, Nihoyannopoulos P, McKenna WJ, et al. Mitral regurgitation in hypertrophic obstructive cardiomyopathy: a color Doppler echocardiographic study. *Am J Noninvas Cardiol* 1988; 2:195-198.
5. Petrone RK, Klues HG, Panza JA, et al. Coexistence of mitral valve prolapse in a consecutive group of 528 patients with hypertrophic cardiomyopathy assessed with echocardiography. *J Am Coll Cardiol* 1992; 20:55-61.
6. Wigle ED. Hypertrophic cardiomyopathy: a 1987 viewpoint. *Circulation* 1987; 75:311-322.