

CASE REPORT

A Rare Case of a Pseudoaneurysm of the Ascending Aorta Presented as Superior Vena Cava Syndrome

Ioannis Nenekidis,¹ MD, Panagiotis Dedeilias, MD,¹
Ioannis Mamidakis, MD,¹ Marios Patronis, MD,¹
Stamatia Pispirigou, MD,¹ Panagiotis Politis, MD,²
Paraskevi Dolou, MD,³ Konstantinos Bolos, MD¹

ABSTRACT

Pseudoaneurysm of the ascending aorta constitutes a well known entity after thoracic aortic surgery. We present a rare case of a large pseudoaneurysm created five years after primary surgery that provokes a significant compression of the right mediastinal venous system causing superior vena cava syndrome. Perioperative findings showed two rush out points both coming from the distal aortic suture line which was performed five years earlier. The patient underwent reoperation under circulatory arrest facilitating safe exploration and repair of the distal anastomotic leaks.

CASE REPORT

A 79-year-old gentleman previously operated for severe aortic valve insufficiency and aneurysm of ascending aorta was examined in our emergency department due to exertional dyspnea accompanied by swelling of the upper limbs, head and neck. Five years earlier the patient had undergone an elective replacement of the aortic valve with a prosthetic one (23 mm Carbomedics). At the same time the concomitant ascending aortic aneurysm was replaced by a synthetic graft (28 mm Vascutec).

On admission the patient was dyspneic and complained of malaise. His blood pressure was normal (128/82 mmHg) and the oxygen saturation without extra oxygen supply was 92%. Pulses were irregular with an increased heart rate. ECG showed atrial fibrillation with fast ventricular response (135 to 145 beats/min). Inspection revealed cyanotic and swollen head and neck. Jugular veins were distended bilaterally to the angle of the mandible. There were no objective signs of pleural effusion. The rest of his physical examination was normal. Superior vena cava syndrome (SVCS) was clinically diagnosed.

Laboratory data included a prolonged INR of 7 and a hematocrit of 35.6%. Other elements of blood count and coagulation profile were within normal values. Cardiac enzymes were normal. Lactic dehydrogenase (LDH) was measured at 620 IU/L. The rest of his biochemical profile was normal. Arterial blood gases showed mild respiratory acidosis (PH at 7.33) due to elevated PCO₂ at 48 mmHg.

Chest X-ray was remarkable for widening of the mediastinum compatible with

¹First Department of Cardiac Surgery,

²Intensive Care Medicine,

³Department of Anesthesiology,
“Evangelismos” General Hospital,
Athens, Greece

KEY WORDS: ascending aortic
aneurysm; aortic pseudoaneurysm;
superior vena cava syndrome

ABBREVIATIONS

CPB = cardiopulmonary bypass

SVCS = superior vena cava syndrome

Correspondence to:

Panagiotis Dedeilias, MD,

E-mail: pdedeilias@yahoo.gr

Manuscript received March 11, 2010

Revised manuscript received &

Accepted April 20, 2010

dilatation of the ascending aorta (Fig. 1). Urgent computed tomography of the chest revealed a large pseudoaneurysm of the ascending aorta with a maximum diameter of 13 cm. Additionally, a significant amount of thrombotic material within the false sac and compression of the inferior vena cava (IVC) along with extensive collateral circulation were included as important findings of the scan imaging. These findings explained the superior vena cava syndrome (SVCS) (Fig. 2). Transfusions with 2 units of fresh frozen plasma were adequate to lower the INR to 1.8 and the patient was then transferred to the operating room.

Initially we established a femoro-femoral cannulation in order to start cardiopulmonary bypass (CPB) and decrease the patient's temperature down to 16°C to safely commence circulatory arrest. Ventricular fibrillation appeared at 28°C. After the completion of cooling with collection of the patient's blood within the reservoir of the extracorporeal device, repeat sternotomy was performed through safe surgical means. Retrograde cardioplegia was installed. The pseudoaneurysm was incised and the thrombotic material was carefully removed. Two sites of major leakage originating from the anterior and

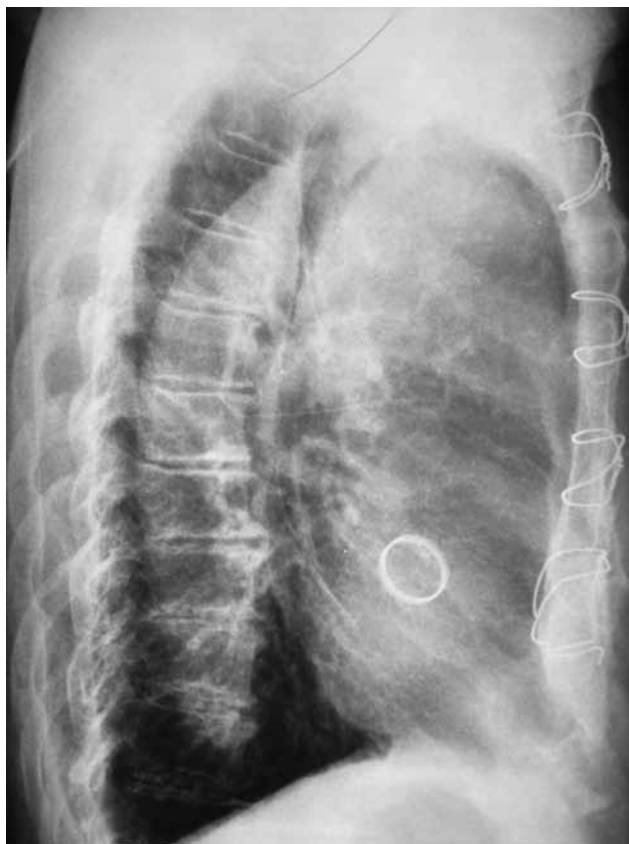


FIGURE 1. Plain lateral chest x-ray showing the large shadow of the thoracic pseudoaneurysm.

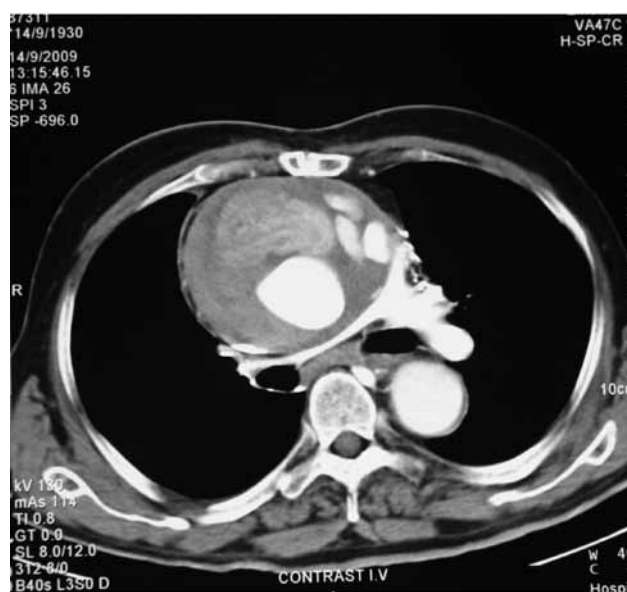


FIGURE 2. Contrast computed tomography of the superior mediastinum showing the pseudoaneurysm of the aorta causing compression of superior vena cava.

posterior segment of the distal anastomosis were revealed. Suturing with 3/0 prolene reinforced by teflon patches was performed. Eventually extracorporeal circulation was restarted and gradual rewarming was achieved.

The patient was extubated 6 hours later and he remained in the intensive care unit for 18 hours. His postoperative course was uneventful. Ten days following his admission the patient was discharged home in good condition. Three months following his discharge he remains free of symptoms.

DISCUSSION

Pseudoaneurysm of the ascending aorta is a well known complication after thoracic aortic surgery. It remains a rare clinical entity but fatal if left untreated. The sites of its origin are certain spots of handling during cardiac surgery such as the aortic cross clamp area, aortotomy, aortic cannulation and vent, cardioplegia needle, coronary anastomosis and proximal and distal aortic suture lines.^{1,2} The mechanism of pseudoaneurysm formation is not yet clear, but suture line tension and persistent bleeding into the space between the graft and the wrapped aorta wall seem to be most important.³

The first case of SVCS was described by William Hunter in 1757.⁴ This severe disease is caused mainly by tumors which compress or develop inside the superior vena cava. In recent reports, benign diseases accounted for 10% of SVCS cases.⁵ Among these, dehiscence of anastomotic regions in previously operated patients for heart vessel reconstruction appears to be

a small group. Five years ago, our patient underwent simultaneously replacement and substitution of the aortic valve and ascending aortic aneurysm respectively, which seems to be an efficient alternative of the Bentall technique,⁶ especially when patients are old and echocardiographic findings show a normal aortic root.

Bleeding from the proximal or distal aorto-graft anastomosis can occur long after an aortic composite graft operation. It is a necessity to consider the formation of pseudoaneurysm as a rare but dramatic complication in almost all cardiovascular operations.⁶⁻⁸

REFERENCES

1. Kouchoukos NT, Wareing TH, Murphy SF. Sixteen-year experience with aortic root replacement: results of 172 operations. *Ann Surg* 1991; 214:308-320.
2. Sullivan KL, Steiner RM, Smullens SN. Pseudoaneurysm of the ascending aorta following cardiac surgery. *Chest* 1988; 93:138-143.
3. Carrel T, Pasic M, Jenni R. Reoperations after operation on the thoracic aorta: etiology, surgical techniques and prevention. *Ann Thorac Surg* 1993; 56:259-269.
4. The superior vena cava syndrome as a manifestation of dissection of the ascending aorta. *Med Pregl* 2001; 54(7-8):380-382.
5. Baker GL, Barnes HJ. Superior vena cava syndrome: etiology, diagnosis and treatment. *Am J Crit Care* 1992; 1:54-64.
6. T Vyd, J Coddens, F Wellens. Superior vena cava syndrome caused by a pseudoaneurysm of the ascending aorta. *Heart* 2005; 91:e29
7. Baldari D, Chiu S, Saliccioli L. Aortic pseudoaneurysm as a rare cause of superior vena cava syndrome-a case report. *Angiology* 2006; 57:363-366.
8. Olivier Michel Bical, Jerom Heran, Bernard Thebault, Francois Funck. Pseudoaneurysm following Dacron replacement of the ascending aorta. *Eur J Cardiothoracic Surg* 2009; 35:536.