

IMAGES IN MEDICINE

## Serious Penetrating Chest Trauma without Severe Sequelae

Charalambos Zisis, MD, FETCS,<sup>1</sup> Marios Patronis, MD,<sup>1</sup>  
Vassiliki Karameri, MD,<sup>2</sup> Georgios Rallis, MD,<sup>1</sup> Ion Bellenis, MD, FETCS<sup>1</sup>

<sup>1</sup>Department of Thoracic and Vascular Surgery,

<sup>2</sup>Department of Anesthesiology, Evangelismos Hospital, Athens-Greece

A 58-year-old male builder was admitted with penetrating trauma after a labor accident. An iron rod pierced through the right hemithorax, but the radiological evaluation with chest X-ray and computed tomography (CT) showed that all vital structures were spared (**Figure 1A & 1B**). The patient was hemodynamically stable without signs

**KEY WORDS:** penetrating injury; chest trauma; video assisted thoracoscopic surgery; labor accident

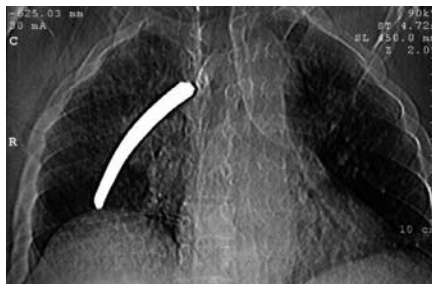


FIGURE 1A.

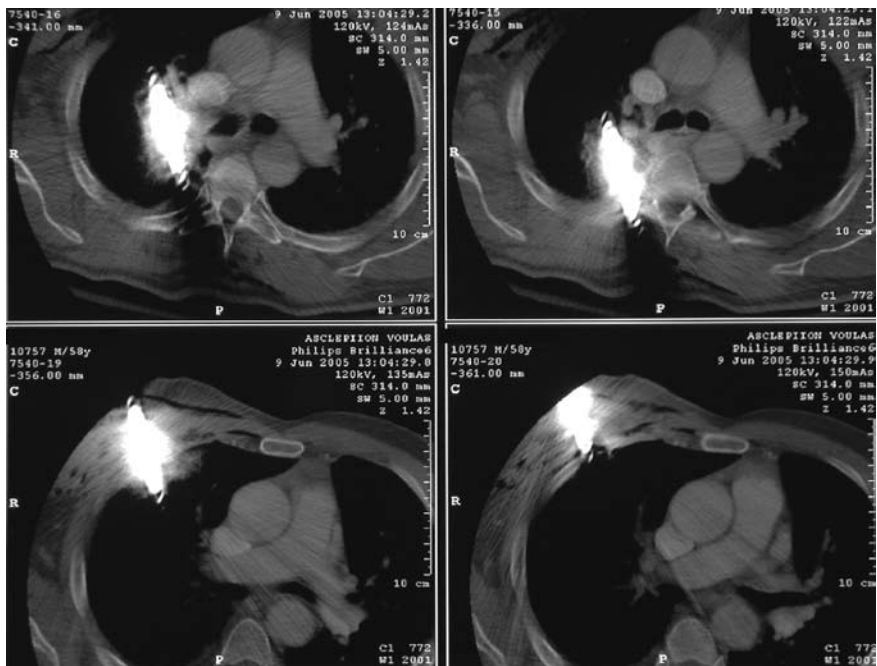


FIGURE 1B.

Correspondence to:  
Charalambos Zisis, MD  
17a Patriarchou Grigoriou Street  
166 74 Glyfada, Athens, Greece  
E-mail: xzhs84@otenet.gr  
Tel. No: +30-210-9651639  
FAX No: +30-210-7224449

Manuscript received February 21, 2010;  
Revised manuscript received May 23, 2010;  
Accepted June 4, 2010

of acute bleeding and underwent right thoracotomy in order to explore the pleural cavity, remove the rod, and assess for major vessel, diaphragmatic and cardiac injuries. Removal of the rod was performed (Figure 2), and air leak of the pulmonary parenchyma was checked. The postoperative course was uneventful (Figure 3), the tube thoracostomy was removed on the fifth postoperative day, and the patient was discharged home on the sixth postoperative day.

Penetrating thoracic injuries are usually life threatening and potentially compromise both respiratory and cardiac function. Multislice CT-scan in hemodynamically stable patients

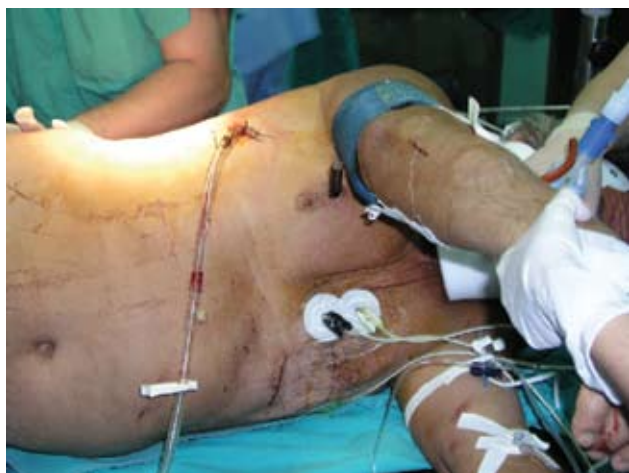

FIGURE 2.

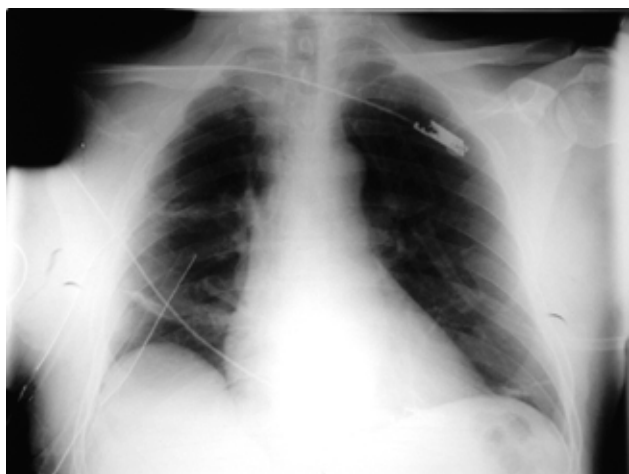

FIGURE 3.

provides accurate detection of pericardial hemorrhage, major thoracic vascular injuries, hemothorax or pneumothorax, diaphragmatic tears, lung contusion and laceration<sup>1</sup> and contributes to a faster and more detailed diagnosis of thoracic injuries.<sup>2</sup> It secures at the same time assessment of the traumatic lesions and safe planning of the operation avoiding unexpected findings. Thoracotomy with by-pass pump at stand-by allows excellent access, relatively easy removal of large foreign bodies, and assessment of intrathoracic injury with thorough debridement. The role of video assisted thoracoscopic surgery (VATS) in penetrating chest trauma was originally intended for the treatment of retained hemothorax and the diagnosis of diaphragmatic injury, and is now expanding in the treatment of chest wall bleeding, persistent pneumothorax, pericardial window formation and diagnosis of transmediastinal injuries.<sup>3</sup> The VATS approach has been proposed as a reliable alternative in select cases of stable patients.<sup>4</sup> However, it has been reported that before choosing VATS, an exhaustive evaluation with CT scan, angiogram and esophagogram is crucial. If a large amount of hematoma is suspected in proximity to a great vessel, thoracotomy should always be the first choice.<sup>5</sup>

As rarely are such cases complicated with infections such as thoracic empyema or mediastinitis, negative pleural fluid cultures are considered mandatory before chest tube removal. In cases of uncontrollable bleeding due to penetrating thoracic trauma, when hypothermia and coagulopathy compromise the survival of the patient, the principles of damage control surgery with packing have been proposed as a reliable alternative.<sup>6</sup>

## REFERENCES

1. Mirvis SE. Diagnostic imaging of acute thoracic injury. *Semin Ultrasound CT MR* 2004; 25: 156-179.
2. Keel M, Meier C. Chest injuries - what is new? *Curr Opin Crit Care* 2007; 13: 674-679.
3. Casos SR, Richardson JD. Role of thoracoscopy in acute management of chest injuries. *Curr Opin Crit Care* 2006; 12: 584-589.
4. Komatsu T, Neri S, Fuziwara Y, Takahashi Y. Video-assisted thoracoscopic surgery (VATS) for penetrating chest wound: thoracoscopic exploration and removal of a penetrating foreign body. *Can J Surg* 2009; 52: E301-302.
5. Burack JH, Amulraj EA, O'Neill P, Brevetti G, Lowery RC. Thoracoscopic removal of a knife impaled in the chest. *J Thorac Cardiovasc Surg* 2005; 130: 1213-1214.
6. Caceres M, Buechter KJ, Tillou A, Shih JA, Liu D, Steeb G. Thoracic packing for uncontrolled bleeding in penetrating thoracic injuries. *South Med J* 2004; 97: 637-641.