

REVIEW

Management of Cryptogenic Strokes by Percutaneous Closure of Interatrial Communications

Antonis S. Manolis, MD, FACC, FESC, FHRS

First Department of Cardiology
Evangelismos General Hospital of
Athens, Athens, Greece

KEY WORDS: *Cryptogenic stroke, patent foramen ovale, atrial septal defect, migraine, percutaneous closure devices*

ABSTRACT

In patients with a cryptogenic stroke the prevalence of a patent foramen ovale (PFO) is increased to approximately 50% compared with a 25%-30% prevalence rate in the general population. This leads to a plausible assumption that a considerable number of strokes could potentially be attributed to a PFO, most likely due to paradoxical embolism. It is estimated that the risk for an embolic stroke due to the presence of a PFO may be 9-fold higher than that related to hypertension, diabetes or hypercholesterolemia. Furthermore, in the presence of an interatrial septal aneurysm (IASA), this risk may even be 30-fold higher. The management of patients with a cryptogenic stroke and a PFO is currently based on antithrombotic or anti-platelet therapy, however the recurrence rate remains high (4-25%), and this has led to the recommendation of percutaneous PFO closure, which is now effected via a simple and relatively safe technique, which appears to reduce recurrences to 0-5%. However, the studies which provide such favorable data are only retrospective, which means that we are in dire need of prospective randomized studies that compare the two therapeutic approaches, before the interventional method is more widely adopted.

In addition to cryptogenic stroke, the presence of a PFO has been also associated, among other conditions, with bouts of migraine and its percutaneous closure has been shown, albeit via retrospective and observational data, to eliminate or significantly improve this common condition. The only prospective randomized trial available (MIST trial) failed to show conclusively the superiority of PFO closure to medical treatment with regards to elimination of migraine.

Another large group of patients undergoing percutaneous closure of an interatrial communication are those with a secundum atrial septal defect (ASD). The majority of these patients, at least those having defects as large as 35-38 mm and an adequate rim to support a closure device, can now be successfully submitted to the percutaneous technique and thus avoid surgery. Certainly, these patients could also suffer from cryptogenic strokes and migraine, however, most of them usually require intervention because of hemodynamic reasons.

The technique of percutaneous closure of a PFO or an ASD performed by adult interventional cardiologists is indeed a relatively simple and swift procedure of right heart catheterization, carried out from the groin area via the femoral vein with use of local anesthesia. Complications related to the procedure are limited to $\leq 1-3.4\%$. Due to this paradigm of technological progress, a rapid growth of procedures of percutaneous closure of ASD and PFO has been noted over the last decade, particularly over the recent 4-5 years. Nevertheless, one has to resist in widely and hastily adopting such methods before further strong evidence becomes available via randomized prospective studies.

Address for correspondence:

Antonis S. Manolis, MD
Professor & Director of Cardiology
First Department of Cardiology
Evangelismos General Hospital of
Athens
Athens, Greece
E-mail: asm@otenet.gr

Submitted: July 1, 2009

Accepted: September 11, 2009

CRYPTOGENIC STROKES AND PATENT FORAMEN OVALE - PFO

Over the recent years, significant progress has been accomplished in the percutaneous management of endocardial communications, thus obviating the need for open heart surgery procedures. Among these, a rapid growth of procedures of percutaneous closure of atrial secundum defects (ASD) and patent foramen ovale (PFO) has been noted, particularly in young patients with cryptogenic strokes and/or migraine headaches.¹⁻³

Cerebrovascular accidents or strokes are the third cause of death following cardiovascular events and cancer. It is estimated that approximately 750 000 strokes occur yearly in the USA, accounting for a 27% mortality rate. Among these, around 600 000 strokes are considered ischemic in origin and 10-40% of them are considered cryptogenic, i.e. of unknown cause or source.^{4,5} It is in this group of patients with a cryptogenic stroke that the prevalence of a PFO is found to be increased to approximately 50% compared with a 25%-30% prevalence rate in the general population,⁶⁻⁸ a fact that leads to a plausible assumption that 30000-120000 strokes could potentially be attributed to a PFO, most likely due to paradoxical embolism.^{7,9-13} It is estimated that the risk for an embolic stroke due to the presence of a PFO may be 9-fold higher than that related to hypertension, diabetes or hypercholesterolemia.^{6,9} Furthermore, in the presence of an interatrial septal aneurysm (IASA), this risk culminates to even a 30-fold increase.⁸ Magnetic resonance imaging (MRI), and not computed tomography (CT) scanning, is considered the most appropriate imaging technique to display the cerebral infarcts.¹⁴ In certain cases in the literature, thrombus has been "caught in the act",^{15,16} i.e. straddling the PFO, in its passage from the right to the left circulation, necessitating surgery for its removal.

The diagnosis of a PFO demands a transesophageal echocardiography (TEE)¹⁷ study assisted by a "bubble study", whereby a rapid injection of agitated saline or other contrast material via the antecubital vein can demonstrate the right-to-left passage of microbubbles of saline or contrast directly or after Valsalva maneuvering. An alternate method is a transcranial Doppler study, when the flow of the middle cerebral artery is disturbed from the right-to-left passage of microbubbles of the agitated saline or other contrast material again injected via the antecubital vein; of course, the right-to-left shunting is thus confirmed but the level of communication (atrial or ventricular or other) is not visualized with this technique. In cases where clinical suspicion is high (e.g. in presence of IASA) but these contrast studies are non-diagnostic or negative, repeat injections via the femoral vein may enhance the diagnosis, particularly in the presence of a Eustachian valve in the right atrium; less commonly, probing the inter-atrial

septum with a catheter during right heart catheterization, e.g. during an electrophysiology study or an ablation procedure, can reveal a PFO.

The management of patients with a cryptogenic stroke (permanent or transient) and a PFO is currently based on antithrombotic or anti-platelet therapy,^{18,19} however the recurrence rate remains high (4-25%), a fact that has led to the recommendation of percutaneous PFO closure, which is now effected via a simple and relatively safe technique, which appears to reduce recurrences to 0-5%.^{20,21} However, the studies which provide such favorable data are only retrospective and data from prospective randomized studies that compare the two therapeutic approaches are still lacking. Recruitment of patients into such studies is slow, due to the fact that patients and physicians alike are reluctant to participate, since they intuitively opt for PFO closure as they consider it a more secure therapeutic modality rather than continuing medical therapy. Only though when such evidence-based data become available, will this matter of appropriate use of percutaneous PFO closure be finally and more definitively settled. All these notwithstanding, there has been an exponential increase of percutaneous procedures by a factor of 5- to 30-fold increase over the last decade, particularly over the recent 4-5 years.^{1,2} In our department, the program of percutaneous closures was started 4 years ago and counts around 55 procedures, all performed successfully; however, a hesitant referral pattern of such patients by their neurologists who usually first see and manage them is quite obvious and largely justified due to the incomplete data of evidence-based medicine, mainly related to randomized prospective studies, comparing this invasive approach with the alternative conservative approach with use of antithrombotic agents.

According with current guidelines of medical societies, such as the American College of Chest Physicians-ACCP, American Heart Association-AHA/American Stroke Association-ASA, and American Academy of Neurology - AAN, the evidence for PFO closure is still incomplete and mainly anti-platelet or anticoagulant therapy (the latter in presence of known deep vein thrombosis or thrombophilia) is recommended.²² They also encourage patient participation in prospective randomized study protocols, while they make mention (American Heart Association/American Stroke Association) for consideration of percutaneous closure in cases of recurrences despite medical therapy. However, when these options are put before a patient and his or her family, in the majority of cases an interventional approach is selected after a first stroke, rather than a life-long antithrombotic therapy, since very few settle with the idea of a remaining higher risk for recurrence. The data currently available from several comparative, albeit non-randomized, studies demonstrate a significant difference between the two approaches with regards to recurrences, indicating a much smaller percentage of recurrent stroke (0-4.9%) following PFO closure compared with the recurrence rate (3.8-12%) of

pharmacotherapy.^{3,18-21}

Certainly, one must emphasize that the PFO may simply serve in most cases as the passage gate of a right-sided thrombus to the systemic circulation leading to paradoxical embolism, and in very few one may suspect that there may be in situ thrombosis, particularly in large and long serpentine PFO tunnels,²³ thus becoming imperative in most cases to search for the source or cause of thromboembolism, such as deep vein thrombosis (with use of Doppler ultrasound examination) or thrombophilia (e.g. associated with protein C or S deficiency, factor V Leiden, antiphospholipid antibody, etc.). If, indeed, such a thrombophilic state or thrombo-embolic source exists, percutaneous PFO closure does not cure or eliminate the problem, since a paradoxical embolic episode may be prevented, but there will remain a continuous risk of a serious pulmonary embolic episode, and thus the need for continuing anticoagulation therapy.³

PFO AND MIGRAINE

Beyond the risk of a recurrent cryptogenic stroke due to paradoxical embolism, there are, of course, other reasons for PFO closure, such as diver's disease,^{24,25} the syndrome of tachypnea and desaturation in upright position (tachypnea-orthodeoxia),⁶ the "economy class" syndrome,¹⁰ the obstructive sleep apnea syndrome,²⁶ the multiple infarct dementia,¹¹ or even myocardial infarction due to paradoxical embolism,²² etc. Interestingly, after the fortuitous observation of reduction or elimination of migraine symptoms in patients with cryptogenic stroke undergoing percutaneous PFO closure, a heated discussion has ensued in the literature regarding the association of migraine with a PFO.^{9,27-40} One could attribute this association to substances such as serotonin, or to microthrombi crossing the PFO and bypassing the pulmonary circulation, a place of inactivation or neutralization, and these substances or other ones emanating from platelets produce vasoactive disturbances in the cerebral circulation with subsequent migrainous symptoms. Indeed, it is well known to neurologists that in a good number of patients afflicted with migraine, magnetic resonance imaging (MRI) of the brain discloses areas with "silent" infarcts, which could possibly be related to the presence of a PFO. Nevertheless, it is a fact that several publications report a significant reduction or even elimination of migraine symptoms after a percutaneous device closure of a PFO in an impressive number of cases ranging from 30% to 80%. These, of course, were all observational or retrospective data. However, there, indeed, seems to be an association of migraine with a PFO since the migraine incidence increases from ~12% in the general population to 27-52% in patients with cryptogenic stroke and PFO. On the other hand, the presence of a PFO increases from 27% in the general population to 50% in migraine sufferers, particularly

those with typical migraine associated with an aura. Of course, the issue remains controversial in the absence of randomized prospective data associating migraine with a PFO and indicating a better outcome with percutaneous PFO closure. Indeed, the only prospective randomized trial available (the MIST trial)⁴¹ failed to show conclusively the superiority of PFO closure to medical treatment with regards to elimination of migraine in 147 patients randomized to a PFO closure or sham procedure. Nevertheless, a greater percentage (42%) of patients improved amongst those receiving the device compared to those who did not (23%). An argument has been put forth that the procedure was carried out with a suboptimal device, but this remains to be proven.

ATRIAL SECUNDUM DEFECT-ASD

Another large group of patients undergoing percutaneous closure of an interatrial communication are those with an ASD. The majority of these patients, at least those having defects as large as 35-38 mm and an adequate rim to support a closure device, can now be successfully submitted to the percutaneous technique and thus avoid surgery.⁴²⁻⁴⁴ Certainly, these patients could also suffer from cryptogenic strokes and migraine, however, most of them usually require intervention because of hemodynamic reasons such as large right-to-left shunting (Qp/Qs >1.5:1.0) leading to right ventricular dilation and dysfunction. Intervention has to occur

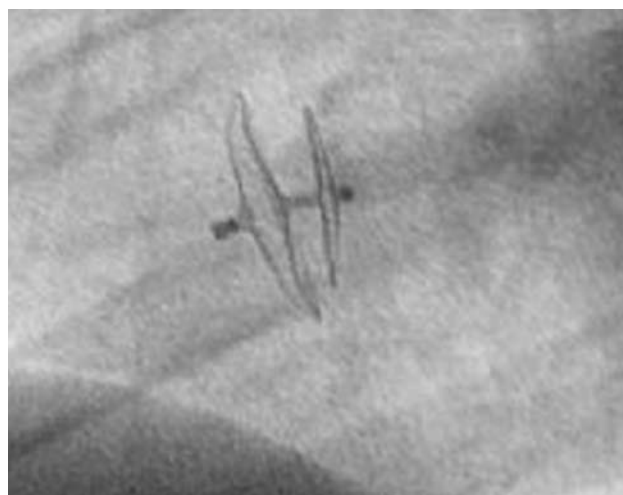

FIGURE 1. Fluoroscopic appearance (left anterior oblique-LAO projection) of a PFO closure device with the two disks held together via a thin trunk, deployed, the smaller one in the left atrium, and the larger one in the right atrium, bringing in contact (close apposition) the two membranous parts of the interatrial septum. Complete closure with impermeability from full endothelialization is achieved within 3-6 months.

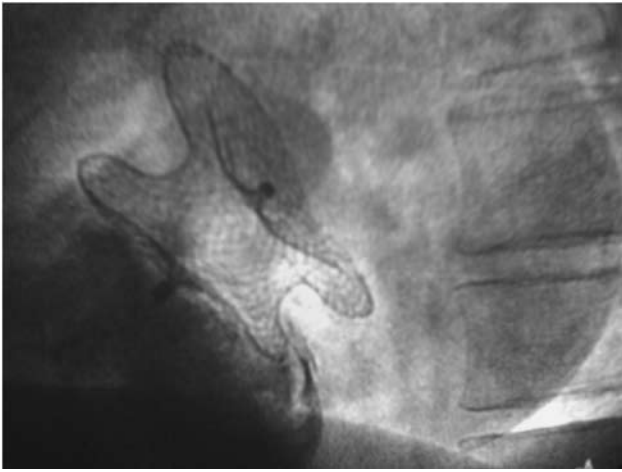


FIGURE 2. Fluoroscopic appearance (LAO projection) of an ASD closure device with the two disks held together with a thick trunk, which covers completely the atrial defect. Injection of contrast material in the right atrium shows the absence of right-to-left passage and thus the complete coverage and closure of the defect.

before pulmonary hypertension develops (with pulmonary pressure >70% systemic pressure) and pulmonary resistance increases excessively (beyond 5 units Wood/m²), all leading to reversal of flow (Eisenmenger syndrome). Symptoms attributed to ASD comprise easy fatigability, general weakness, dyspnea on exertion and/or at rest, syncope or palpitations. Finally, atrial septal defect of the primum or sinus venosus type remain surgical diseases.

PERCUTANEOUS CLOSURE

The technique of percutaneous closure of a PFO or an ASD performed by adult interventional cardiologists is indeed a relatively simple and swift procedure of right heart catheterization, carried out from the groin area via the femoral vein with use of local anesthesia.²² This method is quite different from that employed by pediatric cardiologists, who use general anesthesia and guidance by TEE throughout the procedure. In contrast, in the adult catheterization laboratory the procedure is carried out with use of local anesthesia and is only guided by fluoroscopy and contrast material injection, occasionally aided by use of intracardiac echocardiography. First, one gets access to the left atrium via the PFO or the ASD with use of a long guidewire. The longest delay indeed relates to the time required to cross the interatrial communication, which occasionally may be tedious due to an elongated and serpentine tunnelous formation of a PFO. The latter is further facilitated with use of precurved or steerable catheters. After the passage of the wire to the left atrium, a guiding catheter is advanced over

the wire and secured in place and through this catheter the closure device is introduced into the left atrium. The closure device has two disks joined with a central axis or trunk (Figure 1). One disk is deployed in the left atrium, pulled back to the PFO or ASD until it gets stacked, and then the second disk is deployed in the right atrium. Subsequently, contrast material is injected through the guide catheter to check the position and confirm the absence of right-to-left shunting. Then the closure device is released from the holding device and its position re-checked with a new contrast injection. The duration of the whole procedure takes approximately 10-15 minutes for the PFO closure. For the ASD closure, additional time is usually required, as there is need to make further measurements with use of a balloon to precisely size the defect and select the appropriate device, before initiating the insertion procedure (Figure 2).

The patient stays in the hospital for only 1-2 days. Pre-treatment with aspirin (100-325 mg/d) and clopidogrel (75 mg/d) is used for 3-5 days before the procedure. This antithrombotic regimen is continued for 3-6 months afterwards, which is until complete endothelialization of the device is accomplished and thus the thromboembolic risk is obviated. A bolus of heparin injection (50-100 u/kg) and 2-3 doses of prophylactic antibiotic are administered peri-procedurally. A new TEE exam is performed the next day to confirm proper device position. It is occasionally possible to observe some degree of interatrial shunting during this examination as each of the device's disks is really a sieve, while full impermeability is achieved at 3-6 months with full device endothelialization. During this critical 3-6 month period, prophylactic antibiotic treatment is recommended in case of dental or other procedures.

Complications related to the procedure are limited to ≤1-3.4%^{3,43} and comprise mainly reversible problems at the site of access in the groin (bleeding or hematomas), but more serious adverse effects may occur, such as device dislodgement and embolization, cardiac tamponade, air embolism and atrial tachyarrhythmias. Occasionally, thromboembolic complications and late cardiac perforation from device erosion have rarely been reported.

NEW TECHNIQUES

Novel percutaneous closure systems promise a smaller device volume on the left side, easier device manipulation and complete communication closure with a safer technique and elimination of thromboembolic complications. Of course, the existing closure systems have already minimal or absent thromboembolic risk, especially if a lege artis technique is employed with avoidance of endocardial thrombi formation during use and manipulation of guide wires and catheters. New bioabsorbable devices are being tested,⁴⁵ while novel methods of fusion of the two atrial membranes (primum and secundum

part of the interatrial septum) are under investigation with use of radiofrequency energy, but have only produced modest success to date, in hope to further perfect such techniques and thus obviate the need for foreign material implantation in the future.

CONCLUSION

As up to 25% of patients with a cryptogenic stroke may have a recurrence within 4 years of the first event despite antithrombotic pharmacotherapy and because the presence of a PFO represents a congenital defect which can be easily remedied, several experts believe that the percutaneous closure of the PFO should be the treatment of choice in patients with cryptogenic stroke and a PFO even after the first event. Over the last several years, there has been a great technological progress in percutaneous PFO devices and closure techniques. Nevertheless, one has to resist in widely and hastily adopting such methods before further strong evidence becomes available via randomized prospective studies. At the same time, attempts are continued in developing safer and more efficacious closure devices with fewer or no metallic elements or with bioabsorbable material. Ideally, physicians should be able to discern high risk patients before they develop their first stroke and thus prevent it by proceeding to percutaneous complete closure with use of a device made from material that conforms well to both sides of the atrial septum and has no risk of thrombosis, erosion, infection, or arrhythmias. Prospective randomized trials comparing pharmacotherapy to device closure are under way,²² but their completion is delayed and patient recruitment is difficult⁴⁶ as the incidence of recurrent stroke is low in young patients. Meanwhile, as the occurrence of device complications is decreasing and simpler and safer and more reliable devices are developed, the threshold of percutaneous closure rather decreases, a fact that has become apparent in recent years from the exponentially increasing number of percutaneous interventions for PFO closure worldwide.^{1,2,47}

REFERENCES

1. Opatowsky AR, Landzberg MJ, Kimmel SE, Webb GD. Trends in the use of percutaneous closure of patent foramen ovale and atrial septal defect in adults, 1998-2004. *JAMA* 2008;299(5): 521-522.
2. Karamlou T, Diggs BS, Ungerleider RM, et al. The rush to atrial septal defect closure: is the introduction of percutaneous closure driving utilization? *Ann Thorac Surg* 2008;86:1584-1590.
3. Ford MA, Reeder GS, Lennon RJ, et al. Percutaneous device closure of PFO in patients with presumed cryptogenic stroke or transient ischemic attack. *J Am Coll Cardiol Intv* 2009;2:404-411.
4. Broderick J, Brott T, Kothari R, et al. The Greater Cincinnati/Northern Kentucky Stroke Study: preliminary first-ever and total incidence rates of stroke among blacks. *Stroke* 1998;29:415-421.
5. National Stroke Association. *Stroke/Brain Attack Briefing*. Englewood, CO: Postgraduate Institute for Medicine; 1996:1-34.
6. Hara H, Virmani R, Ladich E, et al. Patent foramen ovale: current pathology, pathophysiology, and clinical status. *J Am Coll Cardiol* 2005; 46: 1768-1776.
7. Lechat P, Mas JL, Lascault G, et al. Prevalence of PFO in patients with stroke. *N Engl J Med* 1988;318:1148-1152.
8. Cabanes J, Mas JL, Cohen A, et al. Atrial septal aneurysm and PFO as risk factors for cryptogenic stroke in patients less than 55 years of age. A study using TEE. *Stroke* 1993;24:1856-1873.
9. Lamy C, Giannesini C, Zuber M, et al. Clinical and imaging findings in cryptogenic stroke patients with and without PFO: the PFO-ASA Study. Atrial Septal Aneurysm. *Stroke* 2002;33: 706-711.
10. Isayev Y, Chan RK, Pullicino PM. «Economy class» stroke syndrome? *Neurology* 2002;58:960-1
11. Angeli S, Carrera P, Del Sette M, et al. Very high prevalence of right-to-left shunt on transcranial Doppler in an Italian family with cerebral autosomal dominant angiopathy with subcortical infarcts and leukoencephalopathy. *Eur Neurol* 2001;46:198-201.
12. Kerut EK, Norfleet WT, Plotnick GD, Giles TD. Patent foramen ovale: a review of associated conditions and the impact of physiological size. *J Am Coll Cardiol* 2001;38:613-23.
13. Mas JL, Arquizon C, Lamy C, et al. Recurrent cerebrovascular events associated with PFO, atrial septal aneurysm, or both. *N Engl J Med* 2001;345:1740-1746.
14. Rothwell PM. Lessons from MATCH for future randomised trials in secondary prevention of stroke. *Lancet* 2004; 364: 305-307.
15. Srivastava TN, Payment MF. Images in clinical medicine. Paradoxical embolism--thrombus in transit through a patent foramen ovale. *N Engl J Med* 1997; 337:681.
16. Koullias GJ, Elefteriades JA, Wu I, et al. Images in cardiovascular medicine. Massive paradoxical embolism: caught in the act. *Circulation* 2004; 109: 3056-3057.
17. Sulek CA, Davies LK, Enneking FK, Gearen PA, et al. Cerebral microembolism diagnosed by transcranial Doppler during total knee arthroplasty: correlation with transesophageal echocardiography. *Anesthesiology* 1999;91:672-6
18. Homma S, Sacco RL, Di Tullio MR, et al; PFO in Cryptogenic Stroke Study (PICSS) Investigators. Effect of medical treatment in stroke patients with patent foramen ovale: patent foramen ovale in Cryptogenic Stroke Study. *Circulation* 2002;105:2625-2631.
19. Mohr JP, Thompson JL, Lazar RM, et al. A comparison of warfarin and aspirin for the prevention of recurrent ischemic stroke. *N Engl J Med* 2001;345:1444-1451.
20. Windecker S, Wahl A, Nedeltchev K, et al. Comparison of medical treatment with percutaneous closure of patent foramen ovale in patients with cryptogenic stroke. *J Am Coll Cardiol* 2004; 44:750-758.
21. Khairy P, O'Donnell CP, Landzberg MJ. Transcatheter closure versus medical therapy of patent foramen ovale and presumed

- paradoxical thromboemboli: a systematic review. *Ann Intern Med* 2003;139:753-760.
22. Meier B. Catheter-based closure of the PFO. *Circulation* 2009; 120:1837-1841.
 23. Goel SS, Tuzcu EM, Shishehbor MH, et al. Morphology of the patent foramen ovale in asymptomatic versus symptomatic (stroke or transient ischemic attack) patients. *Am J Cardiol* 2009; 103:124-129.
 24. Wilmshurst P. Patent foramen ovale and decompression illness. *Spams J* 1997;27:82-83.
 25. Schwerzmann M, Seiler C, Lipp E, et al. Relation between directly detected patent foramen ovale and ischemic brain lesions in sport divers. *Ann Intern Med* 2001;134:21-24.
 26. Agnoletti G, Iserin L, Lafont A, Sidi D, et al. Obstructive sleep apnoea and PFO: successful treatment of symptoms by percutaneous foramen ovale closure. *J Interv Cardiol* 2005;18:393-395.
 27. Del Sette M, Angeli S, Leandri M, et al. Migraine with aura and right-to-left shunt on transcranial Doppler: a case-control study. *Cerebrovasc Dis* 1998;8:327-30.
 28. Wilmshurst PT, Nightingale S, Walsh KP, Morrison WL. Effect on migraine of closure of cardiac right-to-left shunts to prevent recurrence of decompression illness or stroke or for haemodynamic reasons. *Lancet* 2000;356:1648-1651.
 29. Morandi E, Anzola GP, Angeli S, Melzi G, et al. Transcatheter closure of PFO: a new migraine treatment? *J Interv Cardiol* 2003;16:39-42.
 30. Schwerzmann M, Wiher S, Nedeltchev K, et al. Percutaneous closure of PFO reduces the frequency of migraine attacks. *Neurology* 2004; 62:1399-1401.
 31. Post MC, Thijs V, Herroelen L, Budts WI. Closure of a PFO is associated with a decrease in prevalence of migraine. *Neurology* 2004;62:1439-1440.
 32. Azarbal B, Tobis J, Suh W, et al. Association of interatrial shunts and migraine headaches impact of transcatheter closure. *J Am Coll Cardiol* 2005;45:489-492.
 33. Reisman M, Christofferson RD, Jesurum J, et al. Migraine headache relief after transcatheter closure of PFO. *J Am Coll Cardiol* 2005;45:493-495.
 34. Wilmshurst P, Nightingale S, Pearson M, et al. Relation of atrial shunts to migraine in patients with ischemic stroke and peripheral emboli. *Am J Cardiol* 2006;98: 831-833.
 35. Tsimikas S. Transcatheter closure of patent foramen ovale for migraine prophylaxis: hope or hype? *J Am Coll Cardiol* 2005; 45:496
 36. Manolis AS, Andrikopoulos G, Tsagou V, et al. Transcatheter closure of patent foramen ovale during a radiofrequency ablation procedure. *Clin Cardiol* 2006;29:369-371.
 37. Giardini A, Donti A, Formigari R, et al. Transcatheter patent foramen ovale closure mitigates aura migraine headaches abolishing spontaneous right-to-left shunting. *Am Heart J* 2006; 151:922. e1-5.
 38. Anzola GP, Frisoni GB, Morandi E, et al. Shunt-associated migraine responds favorably to atrial septal repair: a case-control study. *Stroke* 2006;37:430-434.
 39. Rigatelli G, Braggion G, Aggio S, et al. Primary patent foramen ovale closure to relieve severe migraine. *Ann Intern Med* 2006;144:458-460.
 40. Jesurum JT, Fuller CJ, Kim CJ, et al. Frequency of migraine headache relief following patent foramen ovale "closure" despite residual right-to-left shunt. *Am J Cardiol* 2008;102:916-920.
 41. Dowson A, Mullen MJ, Peatfield R, et al. Migraine Intervention With STARFlex Technology (MIST) trial: a prospective, multicenter, double-blind, sham-controlled trial to evaluate the effectiveness of patent foramen ovale closure with STARFlex septal repair implant to resolve refractory migraine headache. *Circulation* 2008;117:1397-404.
 42. Jemielity M, Dyszkiewicz W, Paluszkiwicz L, et al. Do patients over 40 years of age benefit from surgical closure of atrial septal defects? *Heart* 2001;85:300-303.
 43. Krumdorf U, Ostermayer S, Billinger K, et al. Incidence and clinical course of thrombus formation on atrial septal defect and patent foramen ovale closure devices in 1,000 consecutive patients. *J Am Coll Cardiol* 2004;43:302-309.
 44. Bialkowski J, Karwot B, Szkutnik M, et al. Closure of atrial septal defects in children: surgery versus Amplatzer device implantation. *Tex Heart Inst J* 2004;31:220-223.
 45. Mullen MJ, Hildick-Smith D, De Giovanni JV, et al. BioSTAR Evaluation Study (BEST): a prospective, multicenter, phase I clinical trial to evaluate the feasibility, efficacy, and safety of the BioSTAR bioabsorbable septal repair implant for the closure of atrial-level shunts. *Circulation* 2006;114:1962-1967.
 46. O'Gara PT, Messe SR, Tuzcu EM, et al. Percutaneous device closure of PFO for secondary stroke prevention. *J Am Coll Cardiol* 2009;53:2014-2018.
 47. Onorato E, Casilli F, Berti M, Anzola GP. Patent foramen ovale closure. Pros and cons. *Neurol Sci* 2008;29 Suppl 1:S28-32.