

IMAGES IN MEDICINE

Tako Tsubo Cardiomyopathy With Right Ventricular Involvement

Socrates Pastromas, MD,¹ Spyridon Koulouris, MD,¹
Isidoros P. Gavaliatsis, MD,² Prodromos Temperikidis, MD,¹
Antonis S. Manolis, MD, FACC, FESC, FHRS¹

¹First Cardiology Department,
Evangelismos Hospital, Athens, Greece
²Department of Interventional
Cardiology, Evangelismos Hospital,
Athens, Greece

A 68-year-old woman, with a history of thyroid cancer diagnosed 2 years ago, underwent a bronchoscopy due to persistent cough lasting for several months. Approximately 4 hours after the procedure she started complaining of chest discomfort and dyspnea. The ECG showed impressive ST-segment elevation (up to 20 mm) in leads II, III, aVF, V₄–V₆ (Figure 1). Based on these findings an ST elevation inferolateral acute myocardial infarction was diagnosed and the patient was promptly transferred to the catheterization laboratory for an emergency coronary angiogram and possible primary angioplasty. Surprisingly, the angiogram did not reveal any significant lesions in the coronary arteries. However, the left ventriculogram displayed the characteristic

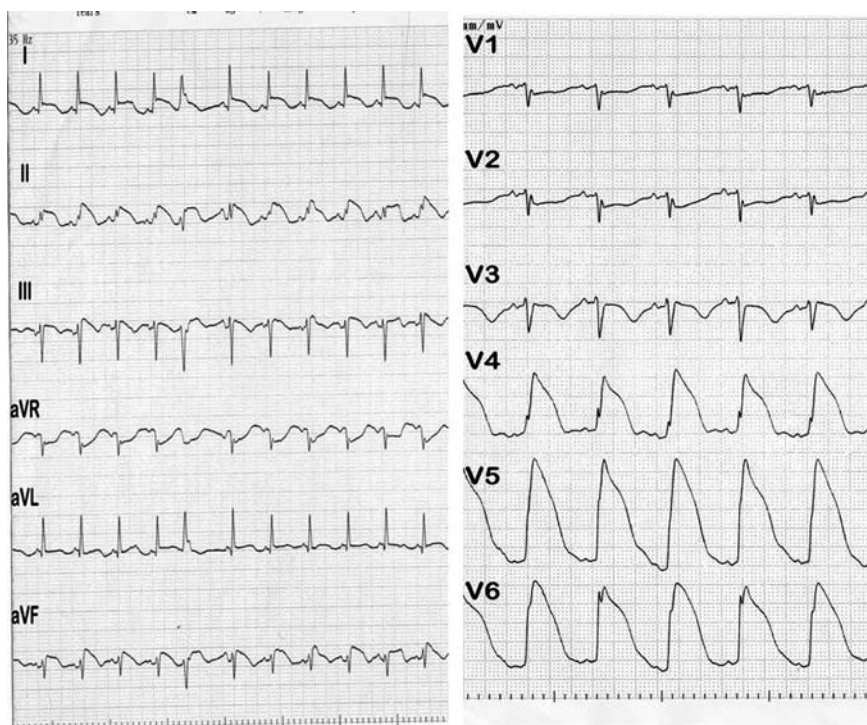


FIGURE 1. The ECG shows impressive ST segment elevation in leads II, III, aVF, V₄–V₆. ST depression in leads V₁, V₂ indirectly denotes right ventricular involvement.

Address for correspondence:
Antonis S. Manolis, MD
Professor & Director of Cardiology
First Department of Cardiology
Evangelismos General Hospital of
Athens
Athens, Greece
E-mail: asm@otenet.gr

Submitted: September 10, 2009

Accepted: September 25, 2009

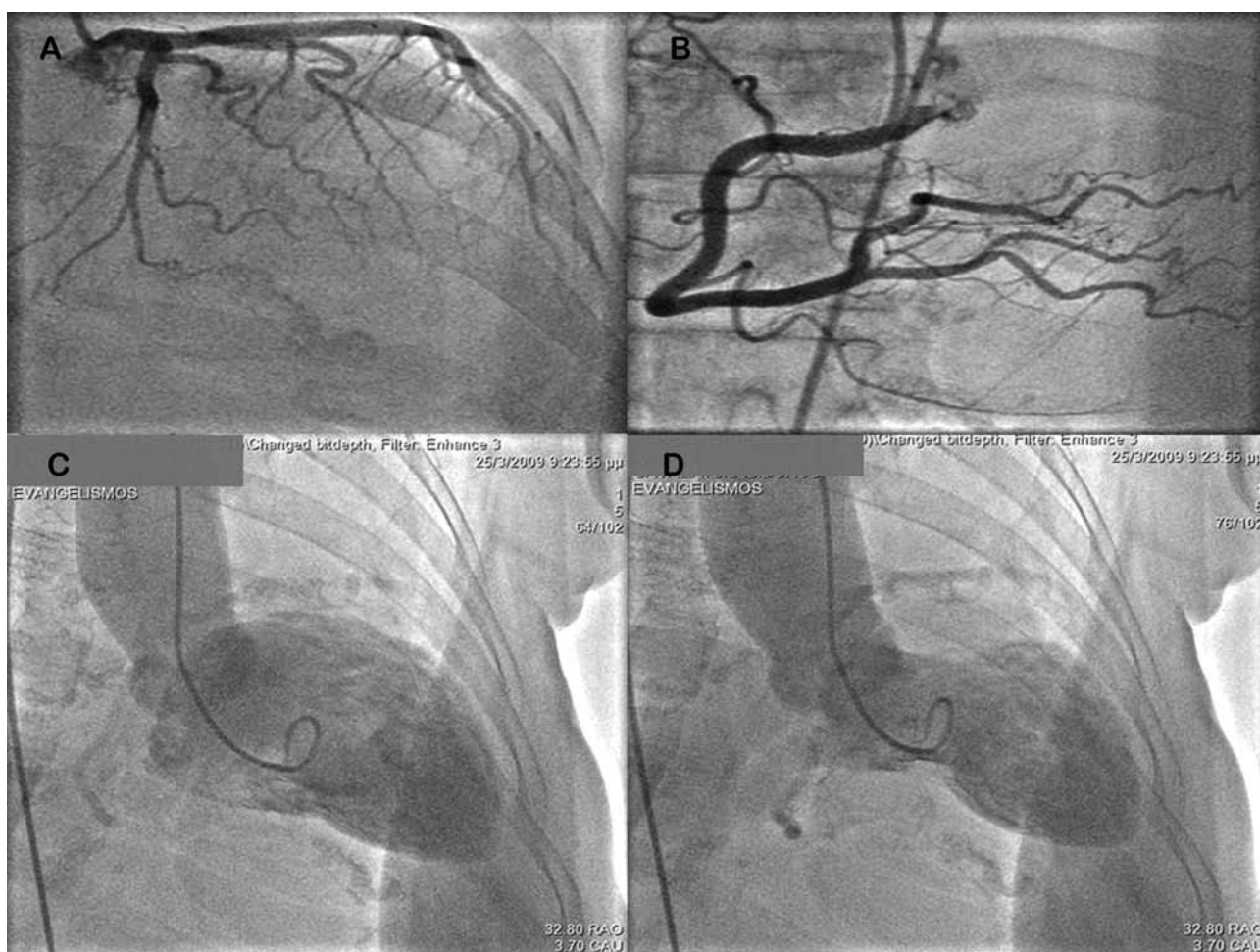


FIGURE 2. A, B: Normal left and right coronary arteries. C, D: Left ventriculography revealed apical ballooning during systole and diastole respectively.

apical ballooning with apical akinesis diagnostic of Tako-tsubo cardiomyopathy (Figure 2). A transthoracic echocardiogram also revealed regional systolic dysfunction of the left ventricular apex. One day after this event, the patient had a magnetic resonance imaging (MRI) study of the heart, which confirmed the diagnosis of Tako-tsubo cardiomyopathy but additionally revealed a right ventricular apex involvement (Figure 3). The right ventricular ejection fraction was estimated at around 33% as measured by the MRI. Serum troponin T was found

slightly elevated (1.2 ng/ml). The post procedural course was uneventful and the patient was discharged home after 4 days on aspirin, diltiazem, ramipril and atorvastatin.

There are only few cases in the literature describing bi-ventricular involvement in the Tako-tsubo cardiomyopathy syndrome^{1,2}. These patients seem to have more severe left ventricular dysfunction which is possibly associated with a worse prognosis. However, our patient did have an uneventful course and complete recovery.

TAKO TSUBO CARDIOMYOPATHY WITH RIGHT VENTRICULAR INVOLVEMENT

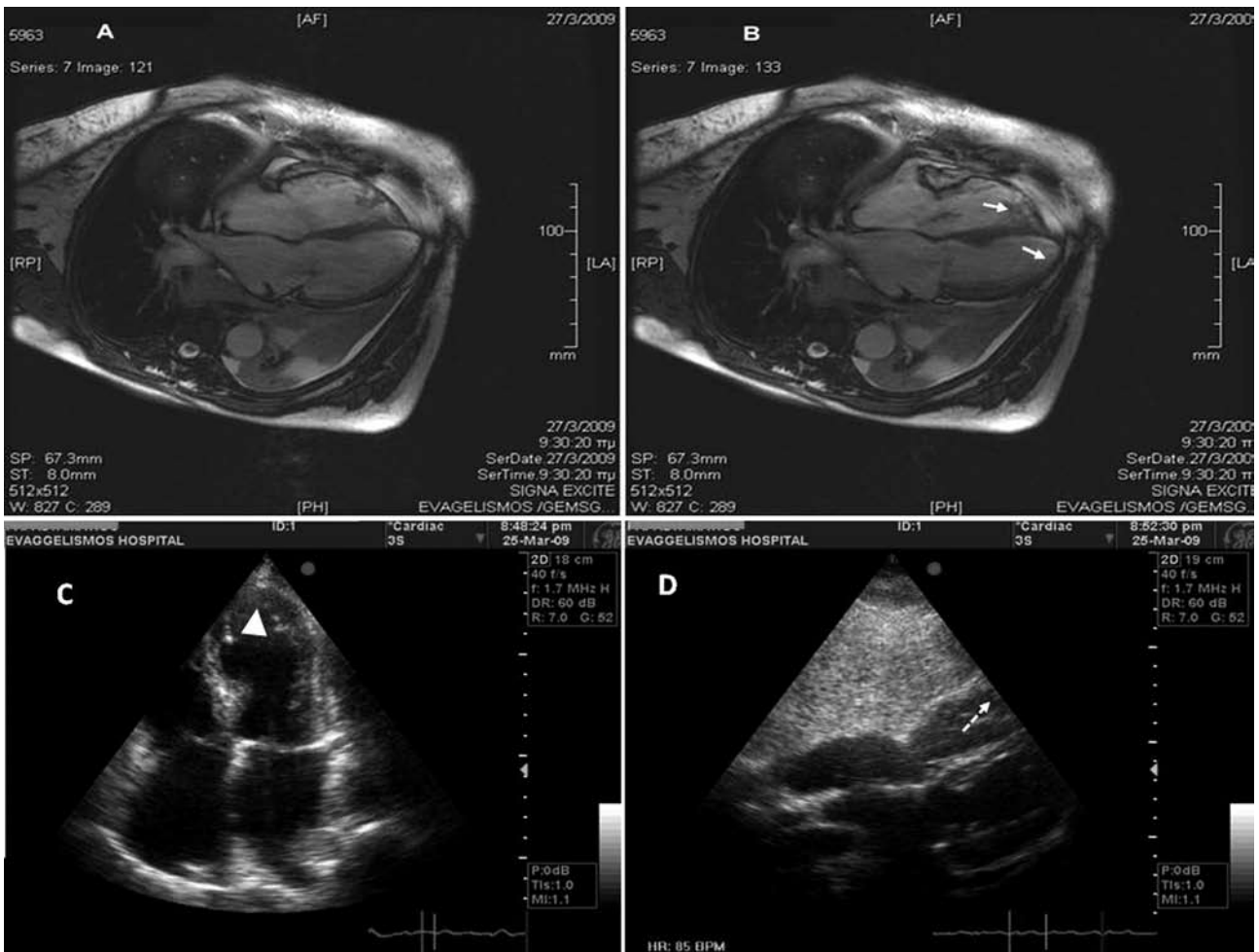


FIGURE 3. A, B: MRI findings supported the biventricular apical akinesia (arrows) during diastole (A) and systole (B). C, D: Transthoracic echocardiogram showed left ventricular apical akinesia in the four-chamber view (C) and right ventricular apical akinesia in the subcostal view (D).

REFERENCES

1. Haghi D, Athanasiadis A, Papavassiliu T, et al. Right ventricular involvement in Takotsubo cardiomyopathy. *Eur Heart J* 2006;27:2433–2439.
2. Elesber AA, Prasad A, Bybee KA, et al. Transient cardiac apical ballooning syndrome: prevalence and clinical implications of right ventricular involvement. *J Am Coll Cardiol* 2006;47:1082-1083.