

CASE REPORT

Rosacea-Like Demodicosis Induced by Topical Pimecrolimus: Immunohistochemical Evaluation of Inflammatory Infiltrate

Efi Pasmatzí¹, MD, Maria Melachrinou², MD, Alexandra Monastirli¹, MD,
Anastasia Tzouma¹, MD, Dionysios Tsambaos¹, MD, PhD

Departments of Dermatology¹ and
Pathology², School of Medicine,
University of Patras, Greece

KEY WORDS: Demodicosis, calcineurin
inhibitors, rosacea, T-lymphocytes

ABSTRACT

We present a 48-year-old female patient who developed rosacea-like demodicosis after seven days of topical application of 1% pimecrolimus cream. The inflammatory infiltrate in the lesions was mainly composed of T-cells with a CD4+/CD8+ ratio = 0.33; B-cells (CD20+) and NK-cells (CD56+) were not detected. Large numbers of (CD68+) histiocytes were demonstrated, whereas the number of Langerhans cells (CD1a+) revealed no significant alteration. The reduced CD4+:CD8+ ratio may have led to a modification of follicular microenvironment favouring the excessive proliferation of *Demodex* mites, who triggered a presently unknown sequence of events leading to the development of pimecrolimus-induced rosacea-like demodicosis.

INTRODUCTION

Demodex folliculorum and *Demodex brevis* are obligatory ectoparasites in the follicular infundibulum and in the sebaceous ducts and meibomian glands, respectively. *Demodex* mites do not cause clinical manifestations in most infected individuals, unless local or systemic immune function of the host is impaired, follicular infestation is heavy and the mites penetrate into the dermis¹⁻³. Demodicosis is a term used to describe cutaneous disorders caused by *Demodex* mites including papulopustular rosacea, pustular folliculitis, perioral dermatitis, rosacea-like demodicosis, pityriasis folliculorum, demodicosis gravis, blepharitis and demodex granuloma⁴.

We describe herein a patient with seborrheic dermatitis who developed a rosacea-like demodicosis with abundant *Demodex* mites subsequent to a 7-day topical application of 1% pimecrolimus cream.

CASE REPORT

A 48-year-old HIV negative female Caucasian patient with a 5-year history of facial seborrheic dermatitis presented with cutaneous lesions (accompanied by a burning sensation) that had suddenly developed after seven days of effective and well-tolerated topical application of 1% pimecrolimus cream (Elidel, Novartis Hellas S.A.,

Address for correspondence:

E. Pasmatzí, M.D.
Department of Dermatology
School of Medicine
University of Patras
P.O. Box 1413
26504 Rio-Patras
Greece

Tel.: +30.2610.994 670

Fax: +30.2610.993 951

e-mail: PASMATZI@med.upatras.gr

Submitted: June 10, 2009

Accepted: September 4, 2009

Athens, Greece) prescribed by her dermatologist. She had previously been treated with topical antimycotics (ketoconazole cream 2%; Fungoral, Janssen-Cilag, Athens, Greece) or steroids (dexamethasone 0.1 % cream, Thilodexine, Farmex S.A., Athens, Greece) with varying success; however, she had received no systemic or topical medications for treatment of the last exacerbation of her seborrheic dermatitis prior to the initiation of pimecrolimus. During pimecrolimus treatment she had not been exposed to sunlight, artificial UV-light or infrared radiation and had received no other topical or systemic medication. The patient denied any previous history of alcohol ingestion, rosacea, acne or perioral dermatitis. Physical examination revealed erythematous and edematous papules and plaques on the nasolabial folds, cheeks, perioral and periorbital areas (Fig. 1).

Routine laboratory investigations including flow cytometry analysis of peripheral lymphocyte subpopulations revealed no abnormalities. Potassium hydroxide examination of skin scrapings showed numerous *Demodex* mites. Histopathological examination of a lesional skin biopsy revealed a dermal perivascular and diffuse predominantly lymphocytic infiltrate mixed with histiocytes. Lymphocytes, isolated and in small clusters, had penetrated into the slightly parakeratotic and spongiotic epidermis (Fig. 2A), whereas 3-5 *Demodex* mites were seen in hair follicles (Figs. 2B & 2C), suggesting a rosacea-like demodicosis. Immunohistochemical investigation performed for the first time in this study revealed that the lymphocytic infiltrate was mainly composed of T-cells (CD3+

and CD5+) with a predominance of CD8+ relative to CD4+ lymphocytes and a CD4+/CD8+ ratio = 0.33 (Figs. 2D & 2E); B-cells (CD20+) and NK-cells (CD56+) were not detected. Large numbers of (CD68+) histiocytes were demonstrated, whereas the number of Langerhans cells (CD1a+) revealed no significant alteration. After 4 weeks of treatment with 50 mg oral minocycline hydrochloride (Minocin caps 50 mg, Teofarma, Athens, Greece) twice daily, the patient revealed a complete resolution of her facial lesions.

DISCUSSION

Topical pimecrolimus, a representative of macrolactam immunomodulators, is an effective and safe second-line modality for the short-term and intermittent management of non-immunocompromised patients with atopic and seborrheic dermatitis and other dermatoses unresponsive to, or intolerant of other treatments⁵⁻⁷. Its side effects include transient local skin reactions (burning/tingling, erythema, pruritus), increased incidence of mostly viral cutaneous infections and lymphadenopathy⁵. The patient presented herein had received no systemic or topical medications for treatment of the last exacerbation of her seborrheic dermatitis prior to the initiation of pimecrolimus. Thus, in view of the morphology of the cutaneous manifestations, the identification of numerous *Demodex* mites in skin scrapings and in the hair follicles and

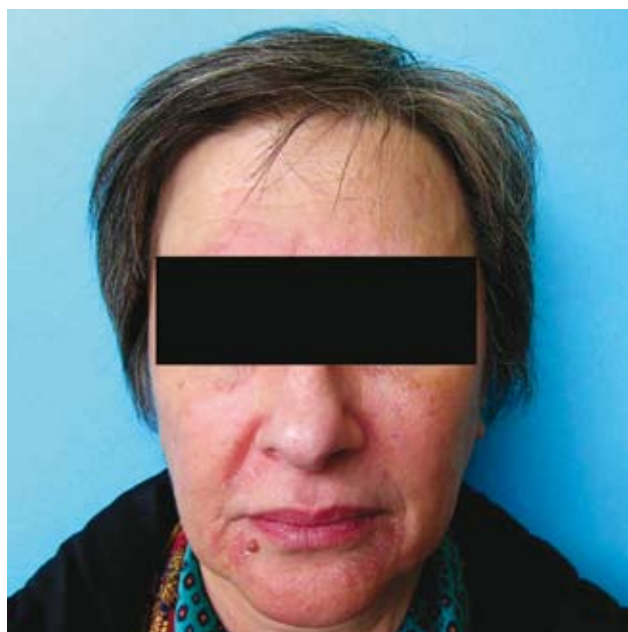

FIGURE 1. Clinical aspect of pimecrolimus-induced rosacea-like demodicosis.

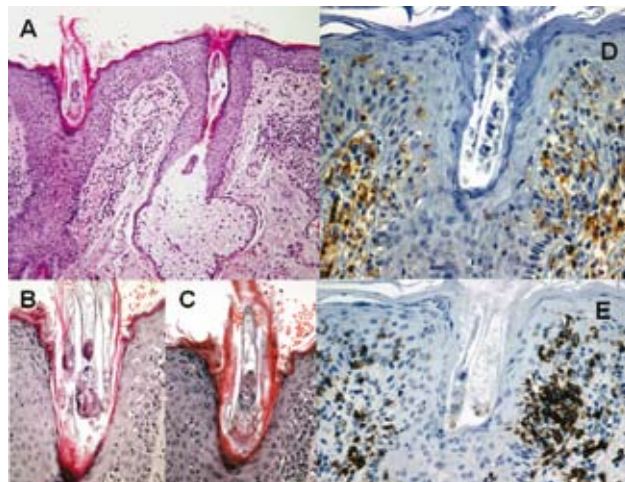


FIGURE 2. A. Histopathological aspect of rosacea-like demodicosis, showing *Demodex* mites within hair follicles and dermal lymphocytic infiltrate (hematoxylinosin; original magnification x 200); B. & C. Intrafollicular mites at higher magnification (hematoxylin-eosin; original magnification x 400); Immunostaining of dermal inflammatory infiltrate for CD4 (D; original magnification x 200) and CD8 (E; original magnification x 200), clearly showing the predominance of CD8+ cells.

of the temporal relationship between the occurrence of the skin lesions and the topical application of this compound, the diagnosis of pimecrolimus-induced rosacea-like demodicosis was established. To our knowledge, this is the fourth report of this disorder (Table 1) in patients with seborrheic or atopic dermatitis⁸⁻¹⁰. However, the potential to cause this rare complication is also shared by tacrolimus and seems to be a common property of topical calcineurin inhibitors¹¹.

In the lesional skin of patients with either atopic or seborrheic dermatitis there is a numerical increase of Langerhans cells, as compared to healthy controls^{12,13}. Furthermore, in contrast to the inflammatory infiltrate in the lesions of atopic and seborrheic dermatitis, in which T-lymphocytes are mostly of helper cell phenotype (CD4+)^{12,13}, in the present case CD8+ cells predominated over CD4+ cells, although CD4+:CD8+ ratio in peripheral blood of the patient was within normal limits (2.17). It seems, therefore, reasonable to suggest that this distinct immunohistochemical profile may be due to the

biological action of topical pimecrolimus. Indeed, it is well known that the latter mainly acts through inhibition of the calcineurin-dependent signal transduction pathway, which is required for activation of CD4+ T-lymphocytes¹⁴. Thus, the reduced CD4+:CD8+ ratio found in the lesional skin of our patient may be interpreted in terms of a pimecrolimus-induced downregulation of IL-2 synthesis and reduction in the numbers of CD4+ lymphocytes. The immunological alterations found in the present study support the hypothesis previously put forth by other groups^{8,10} according to which a pimecrolimus-induced local immunosuppressive effect may have led to a modification of follicular microenvironment favouring the excessive proliferation of *Demodex* mites, who triggered a presently unknown sequence of events leading to the development of pimecrolimus-induced rosacea-like demodicosis. Further studies are now warranted to define the incidence and the predisposing factors of this disorder and the role played by CD8+ cells in its pathogenetic mechanisms.

TABLE 1. Reported cases of rosacea-like demodicosis after topical application of 1% pimecrolimus cream

No.	Sex/age (years)	Previous disease	Onset time	Treatment	Reference
1	Female/43	AD	3 days	Doxycycline	Lübbe et al (2003)
2	Male/36	SD	4 days	Minocycline	Gorman & White (2005)
3	Male/43	SD	7 days	Minocycline	Yoon et al (2007)
4	Female/48	SD	7 days	Minocycline	Present case

AD = atopic dermatitis; SD = seborrheic dermatitis

REFERENCES

- Rufli T, Mumcuoglu Y. The hair follicle mites *Demodex folliculorum* and *Demodex brevis*: biology and medical importance. A review. *Dermatologica* 1981; 162:1-11.
- Akilov O, Mumcuoglu Y. Immune response in demodicosis. *JEADV* 2004; 18:440-444.
- Boutli F, Delli FS, Mourellou O. Demodicidosis as spinulosis of the face – a therapeutic challenge. *J Eur Acad Dermatol Venereol* 2007; 21:273-274.
- Hsu C, Hsu M, Lee J. Demodicosis: A clinicopathological study. *J Am Acad Dermatol* 2009; 60:453-462.
- Luger TA, Gollnick H, Schwennesen T, Bextermöller R et al. Safety and efficacy of pimecrolimus cream 1% in the daily practice: Results of a patient self-observation study in patients with atopic dermatitis. *J Deutsch Derm Ges* 2007; 10: 908-914.
- Mensing CO, Mensing CH, Mensing H. Treatment with pimecrolimus cream 1% clears irritant dermatitis of the periocular region, face and neck. *Pharmacol & Ther* 2008; 47: 960-964.
- Cook BA, Warshaw EM. Role of topical calcineurin inhibitors in the treatment of seborrheic dermatitis: a review of pathophysiology, safety and efficacy. *Am J Clin Dermatol* 2009; 10: 103-118.
- Löbke J, Stucky L, Saurat JH. Rosaceiform dermatitis with follicular *Demodex* after treatment of facial atopic dermatitis with 1% pimecrolimus cream. *Dermatology* 2003; 207:205-207.
- Gorman CR, White SW. Rosaceiform dermatitis as a complication of treatment of facial seborrheic dermatitis with 1% pimecrolimus cream. *Arch Dermatol* 2005; 141:1168.
- Yoon TY, Kim HJ, Kim MK. Pimecrolimus-induced rosacea-like demodicosis. *J Dermatol* 2007;46:1103-1105.
- Antille C, Saurat JH, Lubbe J. Induction of rosaceiform during treatment of facial inflammatory dermatoses with tacrolimus ointment. *Arch Dermatol* 2004; 140:457-460.
- Bergbrant IM, Johansson S, Robbins D, Scheynius A et al. An immunological study in patients with seborrheic dermatitis. *Clin Exp Dermatol* 1991; 16:331-338.
- Lugovic L, Lipozenovic J, Jakic-Razumovic J. Atopic dermatitis: immunophenotyping of inflammatory cells in skin lesions. *Int J Dermatol* 2001; 40:489-494.
- Gupta AK, Chow M. Pimecrolimus: A review. *JEADV* 2003; 17:493-503.