

CASE REPORT

# Transradial Percutaneous Coronary Intervention in Acute Coronary Syndromes: a Case Report and Review of the Literature

Konstantinos A. Triantafyllou, MD, Nikolaos V. Kafkas, MD,  
Georgios A. Mertzanos, MD, Dimitrios K. Babalis, MD

Cardiology Department and Cardiac  
Catheterization Laboratory, KAT  
General Hospital, Athens, Greece

---

ABSTRACT

---

The radial approach to perform coronary angiography and percutaneous coronary interventions (PCI) is currently supported by abundant literature and has been repetitively shown to minimize access site related complications, reduce hospitalization time and costs and increase patient comfort compared to the femoral approach. Most importantly, in acute coronary syndromes the radial access has the potential to significantly decrease serious bleeding complications, which are related to increased morbidity and mortality rates. Despite gradually gaining popularity, the radial approach is still used in only a small fraction of the total number of coronary procedures.

We present herein the case of a woman suffering from acute inferior myocardial infarction referred to our hospital for emergency catheterization after failed fibrinolysis and treated successfully with transradial rescue PCI. The case presentation is followed by a concise overview of data supporting the wider use of the radial approach, especially focusing on acute coronary syndromes.

**KEY WORDS:** *radial approach, acute coronary syndromes, percutaneous coronary intervention*

---

INTRODUCTION

---

The radial access is an alternative to the widely used femoral access to perform coronary angiography and percutaneous coronary interventions (PCI). It was initially presented as a technique for coronary angiography in 1989 by Campeau and further evolved in order to perform coronary angioplasty and stenting due to the pioneering work of Kiemencij.<sup>1,2</sup> Having initially been adopted in centers around Europe the technique gradually gained popularity in other continents as well.<sup>3,4</sup> The radial approach to perform PCI has been consistently shown to minimize access site related complications, reduce hospitalization time and costs and increase patient comfort compared to the femoral approach.<sup>5-7</sup> Despite such data it is still currently used in only a very small fraction of the total number of PCI procedures.<sup>8</sup>

Below is presented the case example of a rescue PCI performed transradially to minimize the possibility of hemorrhagic access site related complications. Additionally, a concise overview of data supporting the use of the radial approach to perform PCI in acute coronary syndromes (ACS) and an appraisal of the most important pertinent

**ABBREVIATIONS**

PCI : percutaneous coronary intervention.  
LAD: left anterior descending.  
RCA: right coronary artery.  
ACS : acute coronary syndrome.

*Address for correspondence:*

Konstantinos A. Triantafyllou,  
Platonos 79-81,  
176 73 Kallithea, Athens, Greece  
e-mail: kontriad@gmail.com

*Submitted: March 25, 2009*

*Accepted: May 11, 2009*

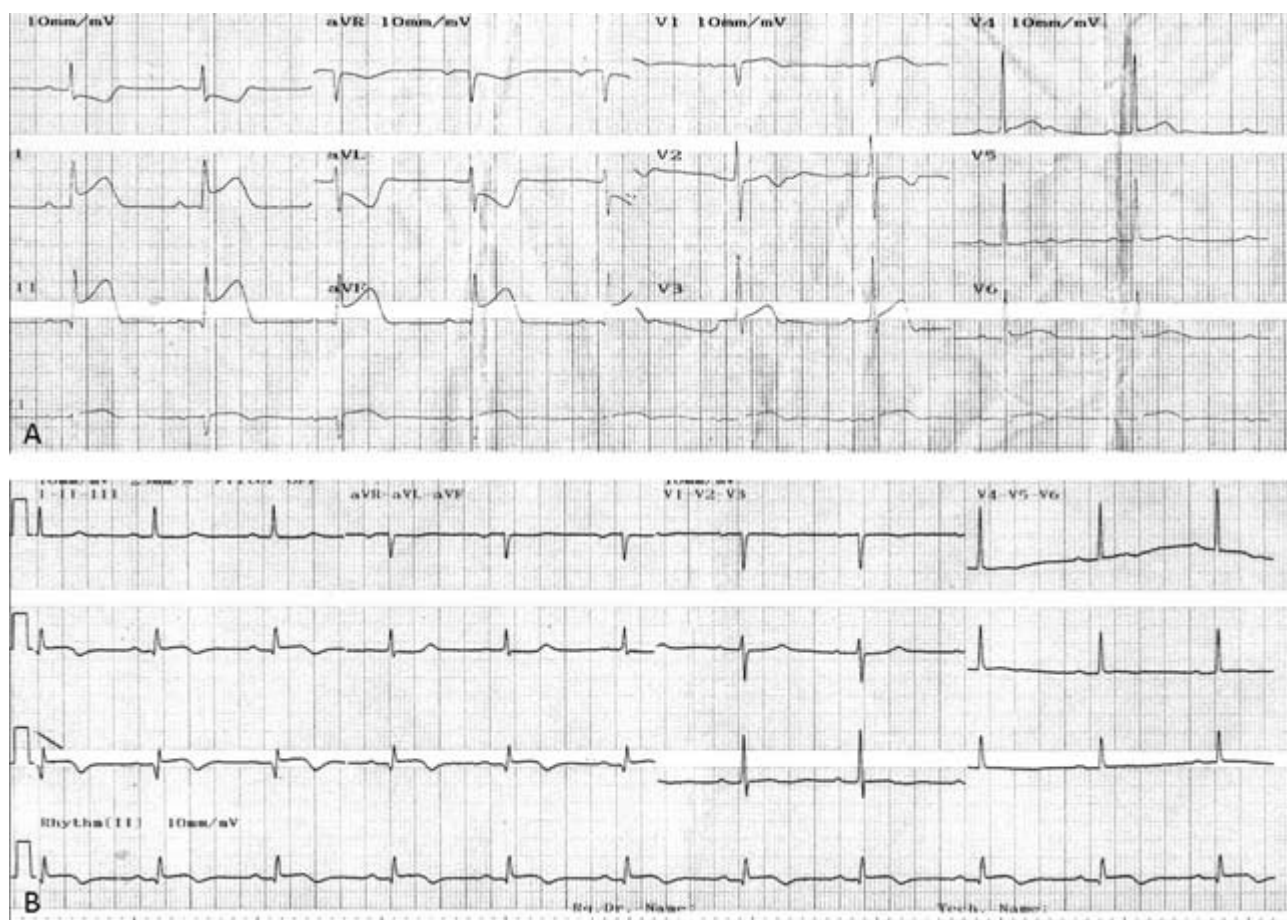
technical issues are attempted.

### CASE PRESENTATION

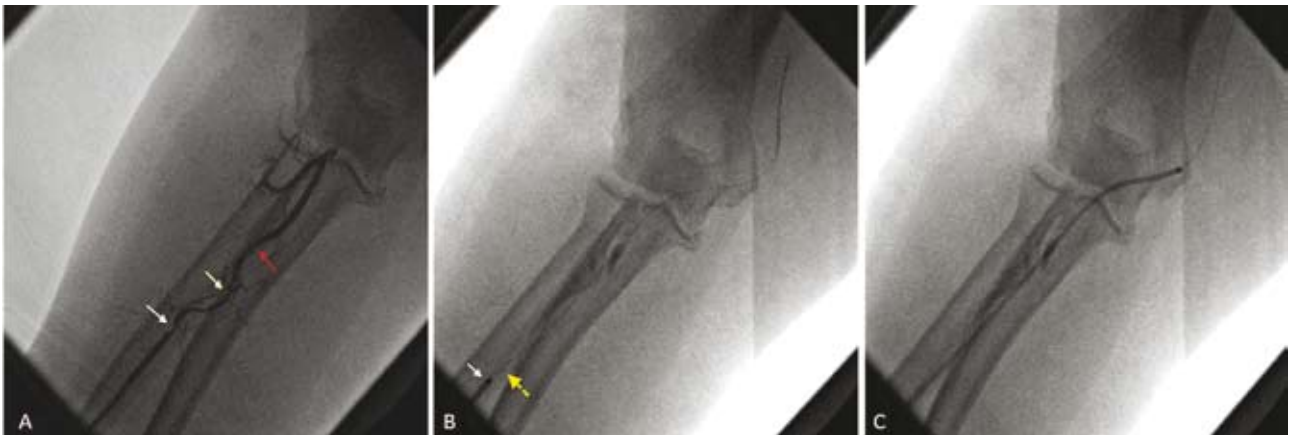A 70-year-old woman suffering from acute inferior myocardial infarction with right ventricular involvement was referred to our hospital for rescue PCI. She had been initially treated with aspirin 325 mg, clopidogrel 300 mg, heparin 4000 IU and tenecteplase 40 mg about 90 minutes after symptom onset and 3 hours before arrival in the catheterization laboratory. She had two-vessel coronary artery disease known for 6 years and was treated medically ever since, despite the fact that coronary artery bypass had been recommended at the time due to severe disease of the proximal and middle segments of the left anterior descending coronary artery (LAD). She had a history of arterial hypertension and dyslipidemia and her body mass index was 34. Upon arrival she was still experiencing severe chest pain and the electrocardiogram (ECG) showed no ST segment resolution in the inferior leads (Figure 1A). She had

a Killip class I status, her blood pressure was 100/60 mmHg and she was in sinus rhythm at 85-90 beats per minute. During physical examination mild jugular venous distension was noted, while a fourth heart sound and a mild systolic apical murmur were audible without any other remarkable findings.

Due to the patient's high risk profile for bleeding complications, the right radial access was chosen to perform rescue PCI. A 6 French 10 cm long hydrophilic sheath was promptly inserted in the radial artery after successful puncture and unfractionated heparin 4000 IU (50 IU/Kg) plus verapamil 4 mg for spasm prevention were administered intra-arterially. Unexpectedly, the standard 0.035" wire was blocked upon exiting the sheath tube. Contrast medium was injected in the radial artery and three consecutive stenoses of the radial artery were noted (Figure 2A). Despite the initial inconvenience the radial access was not aborted in favour of the femoral. The stenoses were easily crossed with a 0.014" coronary guide-wire (Figure 2B) and 5 French diagnostic catheters (Judkins left 3.5 and Judkins right 4) could be easily advanced (Figure 2C) and manipulated without resistance to perform coronary



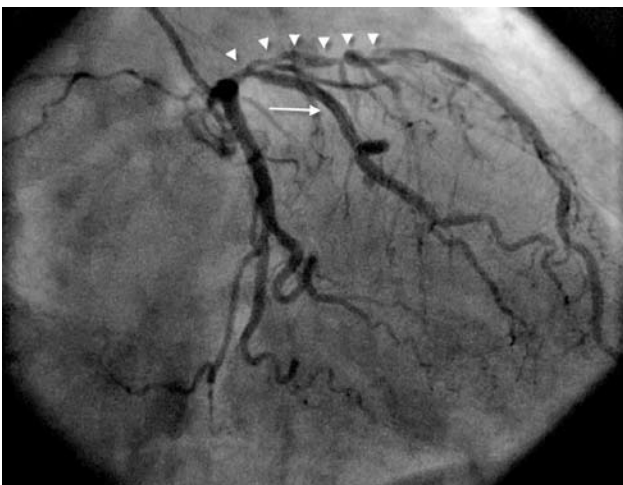**Figure 1.** Electrocardiogram: A. Upon admission. B. 90 minutes post-PCI.



**Figure 2.** A. Three consecutive stenoses of the radial artery (arrows). The first is just after the sheath tip (white arrow). B. Successful crossing with a 0.014" coronary guidewire (white arrow: catheter tip, yellow arrow: sheath tip). C. Diagnostic catheter advancement over the 0.014" guidewire.

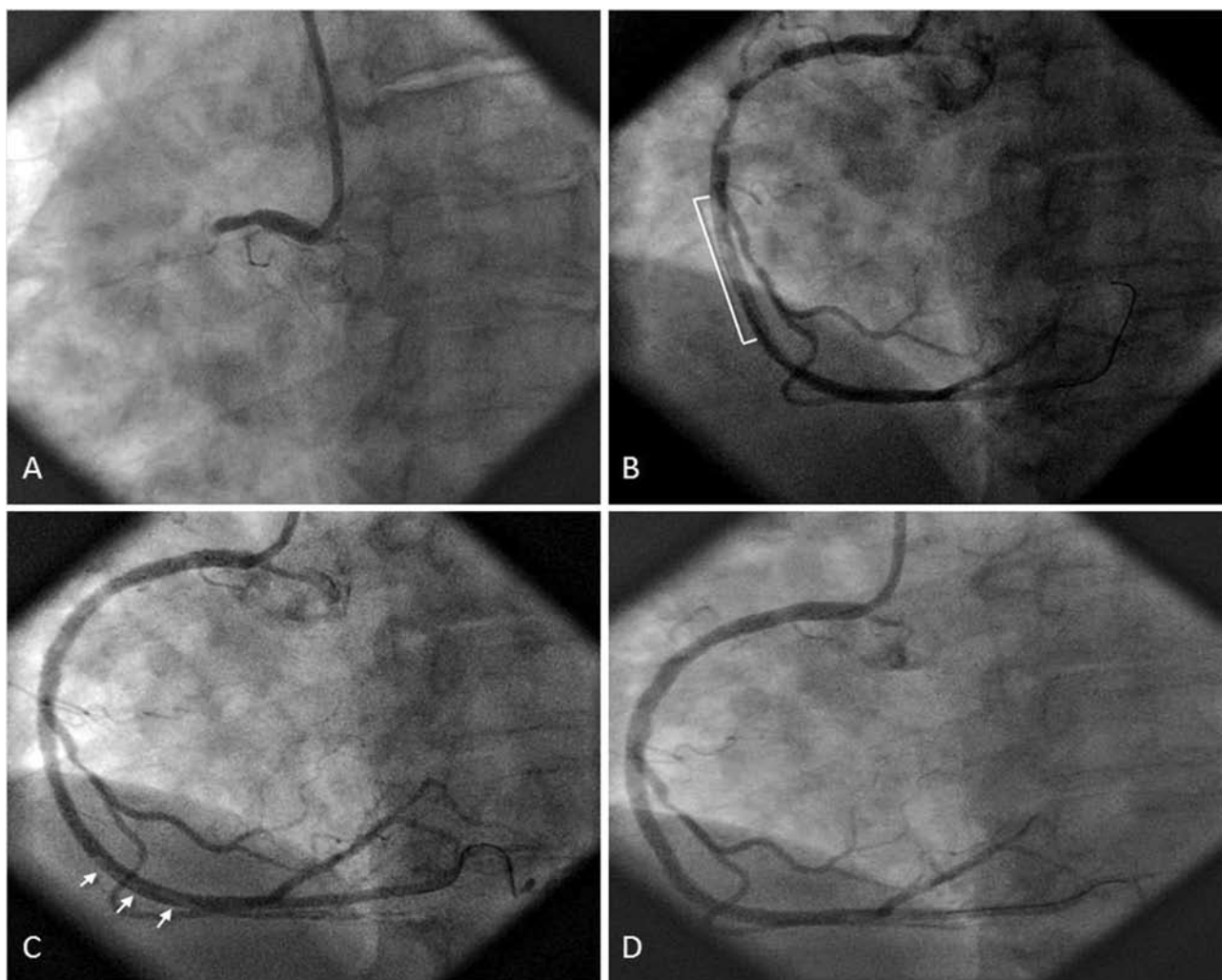
angiography. Two vessel disease was documented; after a short left main the LAD was calcified with diffuse severe disease starting from the ostium and extending to the proximal and middle segments, while a large diagonal branch originating from the very proximal LAD was also affected at the ostium (Figure 3). These lesion characteristics were consistent with the previous recommendation for surgical treatment. However, a total occlusion of the proximal right coronary artery (RCA) was the culprit lesion (Figure 4A).

A Judkins right-4 6French guiding catheter was selected,



**Figure 3.** RAO caudal projection: LAD diffuse severe disease starting at its ostium and extending to the proximal and middle segments is noted (arrow heads). A proximally originating large diagonal with ostial stenosis is also implicated (arrow).

advanced through the radial artery without resistance and positioned at the right coronary ostium. The lesion was easily crossed with the same 0.014" coronary guide-wire previously used to cross the radial artery lesions. After "dottering" and predilatation of the occluded region with a 1.5X15 mm balloon, TIMI III flow was re-established in the artery; a tight long lesion was noted at the end of the proximal segment and diffuse disease with significant thrombotic burden in the middle segment (Figure 4B). A bolus dose (180 µg/kg) of eptifibatide was administered, followed by continuous infusion (2 µg/kg/min), while a second bolus (180 µg/kg) ensued ten minutes later. A thrombus aspiration catheter was used (Export, Medtronic) but only partial thrombus removal could be achieved. Three cobalt-chromium stents were implanted (3X18 mm, 3.5X20 mm and 4X12 mm, from distal to proximal) covering the severe lesions of the middle and proximal vessel segments. Drug eluting stents were not preferred since due to the anatomic characteristics of the LAD lesions a surgical approach might be preferable in the near future to complete revascularization. Moreover, the relatively large diameter of the vessel made bare metal stents seem an even more attractive choice. Following the deployment of stents, thrombus migration more distally was noted (Figure 4C). The thrombus aspiration catheter was re-used and a final satisfactory angiographic result was achieved (Figure 4D). The thrombus aspiration catheter was re-used and a final satisfactory angiographic result was achieved (Figure 4D). The patient was transferred to the coronary care unit and soon thereafter symptoms resolved and ST segment resolution >70% was noted (Figure 1B). The maximum cardiac enzyme values post-procedure included TnI of 32.28 ng/ml, CPK of 1303 IU/L, and CK-MB of 253 IU/L. Eptifibatide infusion was continued for 18 hours. The remainder in-hospital course was uncomplicated. No access site complication was noted.



**Figure 4.** A. RCA occlusion (culprit lesion). B. Diffuse proximal to middle segment disease. Thrombus in the middle segment. C. Residual thrombus migration distally after deployment of stents. D. Final result after thrombus aspiration with Export catheter.

---

**DISCUSSION**

---

The most significant advantage of radial access is its superiority concerning safety, since it practically eradicates vascular access related complications.<sup>9</sup> Such complications are the Achille's heel of femoral access. Closure devices not only did they give a solution to the problem, but to the contrary, there is some evidence that they may increase access site related complications.<sup>10</sup> In a study among almost 18000 Mayo Clinic patients submitted to transfemoral PCI from 1994 to 2005, major hemorrhagic complications despite a trend to decrease as time elapsed, remained at the unsatisfactory level of 3.5% for the period 2000-2005.<sup>11</sup> Of note, their appearance was linked to increased morbidity and mortality at 30 days.<sup>11</sup> In a meta-analysis of 12 randomized trials comparing radial to femoral access there was no difference in success rates

and furthermore, major adverse cardiac events did not differ during the follow up period.<sup>5</sup> However, the use of the radial artery was related to an impressive 89% decrease of puncture related complications (0.3% versus 2.8%,  $p < 0.0001$ ). In a more recent metaanalysis of 23 randomized trials, the radial access has been found to reduce major hemorrhagic complications by 73% compared to the femoral route (0.05% versus 2.3%,  $p < 0.001$ ).<sup>6</sup>

Aggressive antiplatelet and antithrombotic regimens combined with invasive strategies currently used in ACS treatment, carry the risk for serious hemorrhagic complications. Special emphasis has been recently given on their importance for prognosis. Blood transfusions due to hemorrhage complicating ACS treatment have been linked to 4-fold increased mortality at 30 days.<sup>12</sup> Similarly, in another report major hemorrhages were independently related to 5-fold increased mortality at

30 days as well as increased ischemic adverse events.<sup>13</sup> New antiplatelet and antithrombotic agents for the treatment of ACS are under development in the quest for the optimal balance between efficacy and safety. However, the cause of limiting hemorrhagic complications among ACS patients could possibly be served readily and additionally by the wider utilization of radial access. As shown by the SYNERGY trial data analysis from about 10000 patients, transradial PCI in ACS can significantly decrease vascular access related hemorrhagic complications.<sup>14</sup> Femoral access was used in 94,9% of cases while radial in 4.4%. However, blood transfusions were needed in 4.8% of patients treated transfemorally but only in 0.9% of those treated transradially ( $p=0.007$ ). The ability of radial access to minimize vascular access related hemorrhagic complications is even more important when PCI is combined with GP IIb/IIIa receptor antagonist administration.<sup>15</sup>

Apart from ACS without ST segment elevation, the radial access has been compared to the femoral approach in all possible scenarios of emergency PCI for ST elevation myocardial infarction (primary, rescue or facilitated). Two primary transradial PCIs in patients with severe peripheral arterial disease were initially reported in 1996 by Steg and Aubry.<sup>16</sup> Subsequent reports coming from patient series and non-randomized trials compared the radial with the femoral access to perform PCI for ST elevation myocardial infarction.<sup>17-20</sup> Without being inferior to femoral access concerning procedural success, the radial access has been further shown to reduce vascular access related complications in this context. This was also verified in two more recent randomized trials.<sup>21,22</sup> The risk of hemorrhagic complications is significantly increased among patients referred for rescue PCI, as in our case. In these patients a thrombolytic agent had been unsuccessfully administered a few hours prior to the procedure together with aspirin, clopidogrel, heparin and possibly a GP IIb/IIIa receptor antagonist as well. A recent study has shown that for similar procedural success rates, a significant decrease of vascular access related complications can be expected when radial access is used instead of femoral (0% versus 13%,  $p<0.01$ ).<sup>23</sup>

The radial access thus seems capable of minimizing vascular complications in any given clinical context for PCI, either electively performed for stable patients or urgently for patients with ACS with or without ST segment elevation. However, the technique has certain limitations. Adequate blood supply to the hand from the ulnar artery should be confirmed with an Allen test. The radial approach is technically more demanding and characterized by a steeper learning curve compared to femoral.<sup>24</sup> A large meta-analysis has shown that a small increase in the average procedural and fluoroscopy time should be expected compared to femoral access; the difference however tends to be eliminated as experience with the radial technique accumulates.<sup>5</sup> Puncture difficulties, arterial tortuosity and mainly radial spasm can lead to transition to the femoral access in 7.2% of cases.<sup>5</sup> Among experienced

operators the most usual reason for failure is radial spasm whose frequency has drastically decreased with the use of hydrophilic sheaths and medication cocktails administered intra-arterially.<sup>25,26</sup> Asymptomatic loss of the radial pulse in 3-6% of cases is the most frequent local complication after completion of transradial PCI through a 6 French sheath.<sup>5,27</sup> Serious complications (brachial artery perforation, large forearm hematoma, arterial-venous communication, eversion radial arterectomy upon sheath removal) are extremely rare and reported as isolated cases in the literature.<sup>5</sup>

When performing non-complex PCI, the use of 5 French guiding catheters (with 0.058" internal diameter) can lead to similar procedural success rates compared to the widely used 6 French catheters and decrease in parallel the frequency of radial spasm during the procedure as well as asymptomatic radial artery occlusion afterwards.<sup>28</sup> In a series of 119 patients with ACS (with or without ST elevation), transradial PCI through 5 French guiding catheters has shown high success rates with minimal vascular complications.<sup>29</sup> However, a 6 French guiding catheter is at least needed during primary PCI in order to use thrombus aspiration devices, recently shown to contribute to decreased mortality at 1 year in the TAPAS study.<sup>30</sup> It should be noted that PCIs demanding a kissing balloon technique, as well as intravascular ultrasound, optical coherence tomography or fractional flow reserve measurements are all feasible transradially through 6 French guiding catheters (with 0.070" internal diameter). Experienced operators can also use 7 French guiding catheters when rarely required and if the radial artery diameter permits so. The radial approach should be avoided in cases demanding  $\geq 7$  French guiding catheters, insertion of an intra-aortic balloon, temporary pacemaker placement or rotablation with a  $\geq 1.5$  mm burr.

## REFERENCES

1. Campeau L. Percutaneous radial artery approach for coronary angiography. *Cathet Cardiovasc Diagn* 1989;16:3-7.
2. Kiemeneij F, Laarman GJ. Percutaneous transradial artery approach for coronary stent implantation. *Cathet Cardiovasc Diagn* 1993;30:173-8.
3. Schneider JE, Mann T, Cubeddu MG, Arrowood ME. Transradial Coronary Stenting: A United States Experience. *J Invasive Cardiol* 1997;9:569-74.
4. Saito S, Miyake S, Hosokawa G, Tanaka S, et al. Transradial coronary intervention in Japanese patients. *Catheter Cardiovasc Interv* 1999;46:37-41; discussion 2.
5. Agostoni P, Biondi-Zoccai GG, de Benedictis ML, Rigattieri S, et al. Radial versus femoral approach for percutaneous coronary diagnostic and interventional procedures; Systematic overview and meta-analysis of randomized trials. *J Am Coll Cardiol* 2004;44:349-56.
6. Jolly SS, Amlani S, Hamon M, Yusuf S, et al. Radial versus femoral access for coronary angiography or intervention and the impact

- on major bleeding and ischemic events: a systematic review and meta-analysis of randomized trials. *Am Heart J* 2009;157:132-40.
7. Cooper CJ, El-Shiekh RA, Cohen DJ, Blaesing L, et al. Effect of transradial access on quality of life and cost of cardiac catheterization: A randomized comparison. *Am Heart J* 1999;138:430-6.
  8. Rao SV, Ou F-S, Wang TY, Roe MT, et al. Trends in the Prevalence and Outcomes of Radial and Femoral Approaches to Percutaneous Coronary Intervention: A Report From the National Cardiovascular Data Registry. *J Am Coll Cardiol Interv* 2008;1:379-86.
  9. Morice MC, Dumas P, Lefevre T, Loubeyre C, et al. Systematic use of transradial approach or suture of the femoral artery after angioplasty: attempt at achieving zero access site complications. *Catheter Cardiovasc Interv* 2000;51:417-21.
  10. Koreny M, Riedmuller E, Nikfardjam M, Siostrzonek P, et al. Arterial puncture closing devices compared with standard manual compression after cardiac catheterization: systematic review and meta-analysis. *JAMA* 2004;291:350-7.
  11. Doyle BJ, Ting HH, Bell MR, Lennon RJ, et al. Major Femoral Bleeding Complications After Percutaneous Coronary Intervention: Incidence, Predictors, and Impact on Long-Term Survival Among 17,901 Patients Treated at the Mayo Clinic From 1994 to 2005. *J Am Coll Cardiol Interv* 2008;1:202-9.
  12. Rao SV, Jollis JG, Harrington RA, Granger CB, et al. Relationship of blood transfusion and clinical outcomes in patients with acute coronary syndromes. *JAMA* 2004;292:1555-62.
  13. Eikelboom JW, Mehta SR, Anand SS, Xie C, et al. Adverse impact of bleeding on prognosis in patients with acute coronary syndromes. *Circulation* 2006;114:774-82.
  14. Cantor WJ, Mahaffey KW, Huang Z, Das P, et al. Bleeding complications in patients with acute coronary syndrome undergoing early invasive management can be reduced with radial access, smaller sheath sizes, and timely sheath removal. *Catheter Cardiovasc Interv* 2007;69:73-83.
  15. Choussat R, Black A, Bossi I, Fajadet J, et al. Vascular complications and clinical outcome after coronary angioplasty with platelet IIb/IIIa receptor blockade. Comparison of transradial vs transfemoral arterial access. *Eur Heart J* 2000;21:662-7.
  16. Steg G, Aubry P. Radial access for primary PTCA in patients with acute myocardial infarction and contraindication or impossible femoral access. *Catheter Cardiovasc Diagn* 1996;39:424-6.
  17. Louvard Y, Ludwig J, Lefevre T, Schmeisser A, et al. Transradial approach for coronary angioplasty in the setting of acute myocardial infarction: a dual-center registry. *Catheter Cardiovasc Interv* 2002;55:206-11.
  18. Philippe F, Larrazet F, Meziane T, Dibie A. Comparison of transradial vs. transfemoral approach in the treatment of acute myocardial infarction with primary angioplasty and abciximab. *Catheter Cardiovasc Interv* 2004;61:67-73.
  19. Ziakas A, Klinke P, Mildemberger R, Fretz E, et al. Comparison of the radial and the femoral approaches in percutaneous coronary intervention for acute myocardial infarction. *Am J Cardiol* 2003;91:598-600.
  20. Saito S, Tanaka S, Hiroe Y, Miyashita Y, et al. Comparative study on transradial approach vs. transfemoral approach in primary stent implantation for patients with acute myocardial infarction: results of the test for myocardial infarction by prospective unicenter randomization for access sites (TEMPURA) trial. *Catheter Cardiovasc Interv* 2003;59:26-33.
  21. Cantor WJ, Puley G, Natarajan MK, Dzavik V, et al. Radial versus femoral access for emergent percutaneous coronary intervention with adjunct glycoprotein IIb/IIIa inhibition in acute myocardial infarction-the RADIAL-AMI pilot randomized trial. *Am Heart J* 2005;150:543-9.
  22. Brasselet C, Tassan S, Nazeyrollas P, Hamon M, et al. Randomised comparison of femoral versus radial approach for percutaneous coronary intervention using abciximab in acute myocardial infarction: results of the FARMi trial. *Heart* 2007;93:1556-61.
  23. Cruden NL, Teh CH, Starkey IR, Newby DE. Reduced vascular complications and length of stay with transradial rescue angioplasty for acute myocardial infarction. *Catheter Cardiovasc Interv* 2007;70:670-5.
  24. Louvard Y, Pezzano M, Scheers L, Koukoui F, et al. [Coronary angiography by a radial artery approach: feasibility, learning curve. One operator's experience]. *Arch Mal Coeur Vaiss* 1998;91:209-15.
  25. Saito S, Tanaka S, Hiroe Y, Miyashita Y, et al. Usefulness of hydrophilic coating on arterial sheath introducer in transradial coronary intervention. *Catheter Cardiovasc Interv* 2002;56:328-32.
  26. Kiemeneij F, Vajifdar BU, Eccleshall SC, Laarman G, et al. Evaluation of a spasmolytic cocktail to prevent radial artery spasm during coronary procedures. *Catheter Cardiovasc Interv* 2003;58:281-4.
  27. Kiemeneij F, Laarman GJ, Odekerken D, Slagboom T, et al. A randomized comparison of percutaneous transluminal coronary angioplasty by the radial, brachial and femoral approaches: the access study. *J Am Coll Cardiol* 1997;29:1269-75.
  28. Dahm JB, Vogelgesang D, Hummel A, Staudt A, et al. A randomized trial of 5 vs. 6 French transradial percutaneous coronary interventions. *Catheter Cardiovasc Interv* 2002;57:172-6.
  29. Hamon M, Sabatier R, Zhao Q, Niculescu R, et al. Mini-invasive strategy in acute coronary syndromes: direct coronary stenting using 5 Fr guiding catheters and transradial approach. *Catheter Cardiovasc Interv* 2002;55:340-3.
  30. Vlaar PJ, Svilaas T, van der Horst IC, Diercks GF, et al. Cardiac death and reinfarction after 1 year in the Thrombus Aspiration during Percutaneous coronary intervention in Acute myocardial infarction Study (TAPAS): a 1-year follow-up study. *Lancet* 2008;371:1915-20.